

Histological Characteristics of Altered Human Lingual Frenulum

Roberta Lopes de Castro Martinelli¹, Irene Queiroz Marchesan^{2,*}, Reinaldo Jordão Gusmão³, Antonio de Castro Rodrigues⁴ and Giédre Berretin-Felix⁵

¹Faculty of Odontology, University of Sao Paulo - Bauru, Brazil

²CEFAC – Health and Education, Brazil

³Department of ENT, Faculty of Medical Science - UNICAMP, Brazil

⁴Department of Biological Sciences, Faculty of Odontology University of São Paulo- Bauru, Brazil

⁵Department of Speech-Language Pathology, Faculty of Odontology University of São Paulo- Bauru, Brazil

Abstract: *Aim:* The aim of this study was to describe the histological characteristics of altered human lingual frenulum.

Materials and Methods: Between March and July, 2011, 50 children between 6 months and 4 years of age were assessed by a Speech Language Pathologist in a Public Health Care Service in Brotas – Sao Paulo, Brazil. The lingual frenulum evaluation protocol proposed by Marchesan (2010, 2012) was administered to the 50 children – 26 male and 24 female. Of the 50, 8 children had lingual frenulum alterations. The 8 children with lingual frenulum alteration underwent lingual frenectomy. The materials for analyses were taken from 7-micrometer-thick tissues sections. Staining was employed using haematoxylin paired with eosin (H&E), Masson's trichrome and picosirius red.

Results: The assessment of the lingual frenulum indicated that 8 children had lingual frenulum alteration. Surgery was performed and the material collected was submitted to analyses. The histological analyses demonstrated that the lingual frenulum of children with ankyloglossia or with short frenulum had bundles of striated skeletal muscle fibers, high frequency of type I collagen in the deep layers and compact bundles of elastic fibers positioned near the epithelial lining. Bundles of muscle fibers were not observed in anterior frenulum and short frenulum with anterior fixation. Type I collagen and bundles of elastic fibers sparse and far from the epithelial lining were observed in those types of frenulum.

Conclusion: The analysis of the histological sections demonstrated the characteristics of altered human lingual frenulum.

Keywords: Ankyloglossia, Histology, Lingual frenulum, Morphology, Muscle fibers.

INTRODUCTION

The lingual frenulum is a small fold of mucous membrane extending from the floor of the mouth to the midline of the underside of the tongue [1,2]. Lingual frenulum may have different characteristics: long, short, thin or thick. Different lingual frenulum classifications are found due to the anatomic variations. Recent studies have reported that the anatomic variations of the lingual frenulum may be justified by the persistence of midline sublingual tissue that did not undergo apoptosis during embryonic development. That may be the cause of tongue movement restriction [3-10].

The prevalence of lingual frenulum alterations ranges from 2.8 to 22.5% [10,12]. The different diagnostic criteria could explain that considerable variation.

Although several researches on the embryogenesis of the lingual frenulum alterations have been conducted, conclusive results were not obtained.

Studies in humans report that the lingual frenulum alterations can be caused by mutations in the T-box gene, inherited as an autosomal dominant trait with incomplete penetrance [4,13,14].

Studies on morphology of human lingual frenulum were not found in the databases searches. Furthermore, the consequences of lingual frenulum alterations are a controversial subject in literature. Some studies report the importance of early diagnosis and treatment to avoid feeding difficulties and speech alterations [3,5,6,10]. Other studies claim that the lingual frenulum may recede, stretch, and even rupture; therefore, the diagnosis should not be concluded before 5 years of age [15-17].

Currently, when the lingual frenulum restricts the tongue movements, the decisions of healthcare professionals on the appropriate treatment differ. While some professionals refer to surgery, others indicate therapy or postergate the decision [3,15-22]. The diversity of views regarding types of therapy or surgery and appropriate age for intervention may be due to the lack of common parameters for assessment and diagnosis, and lack of deeper knowledge about the lingual frenulum. Studies on the histological

*Address correspondence to this author at the CEFAC Rua Cayowa, 664 CEP 05018-000 Sao Paulo – SP, Brazil; Tel: 551138680818; Fax: 551138680818; E-mail: irene@cefac.br

characteristics of the lingual frenulum may help healthcare professionals decide the best treatment – lingual frenulum surgery, therapy, or both.

The aim of this study was to describe the histological characteristics of altered human lingual frenulum.

MATERIALS AND METHODS

The research was approved by the CEFAC's Ethics Committee (107/10). Informed consent form was given to the subjects and their parents and they were made aware of the procedures of the study.

Between March and July, 2011, 50 children between 6 months and 4 years of age were assessed by a Speech Language Pathologist in a Public Health Care Service in Brotas – Sao Paulo, Brazil. The lingual frenulum evaluation protocol proposed by Marchesan [23,24] was administered to the 50 children – 26 male and 24 female. The analyses of the assessment indicated that 8 children – 7 male and 1 female – had lingual frenulum alterations. The lingual frenulum alterations were classified according to the criteria proposed in the protocol. The 8 children – aged between 2 years and 3 years and seven months – with altered lingual frenulum underwent surgery performed by an Otorhinolaryngologist.

The materials collected during surgery were placed in vials containing fixative solution (10% buffered formalin) and submitted to morphological analysis. Tissue fragments were fixed for 24 hours in 10% buffered formalin, and subsequently rinsed under running water to remove any excess fixative. The material was dehydrated in a solution of increasing alcohol concentration to avoid severe tissue shrinkage, which could lead to structural damage. The samples were subjected to two baths of xylene and embedded in paraffin. 7µm thin sections were obtained using a microtome. Staining was employed using haematoxylin paired with eosin (H&E) for microscopic examination of general characteristics; Masson's trichrome for detection of the fibers observed previously (collagen or muscle fibers); and picrosirius red for collagen detection using the polarized light microscopy. Finally, Resorcin-fuchsin staining was used for the detection of elastic fibers.

RESULTS

The assessment of the lingual frenulum indicated that 4 children had lingual frenulum with anterior

fixation, 1 with short frenulum, 1 with short frenulum and anterior fixation, and 2 with ankyloglossia. The 8 children with lingual frenulum alteration underwent lingual frenectomy.

Histological analyses demonstrated that all types of lingual frenulum consist of mucosa lined by a stratified squamous epithelium. Nucleated cells with some keratin granules in the cytoplasm were found in the superficial layers.

The lingual frenulum of children with ankyloglossia had significant bundles of muscle fibers scattered on the fold mucosa (Figure 1).

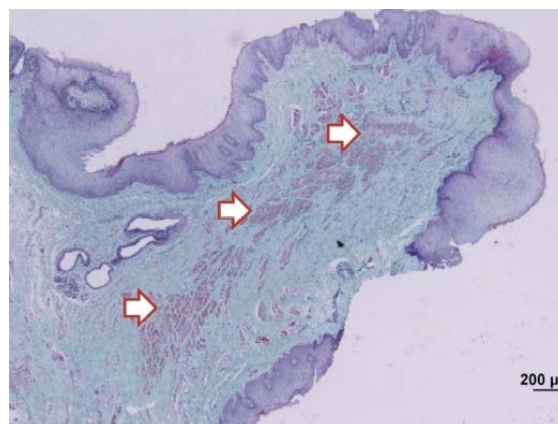


Figure 1: Photomicrograph of ankyloglossia. Significant bundles of muscle fibers (arrows) were observed in the frenulum with ankyloglossia. Masson's trichrome stain.

The short frenulum also had some muscle fibers; however, in lower concentration when compared to the frenulum with ankyloglossia (Figure 2).

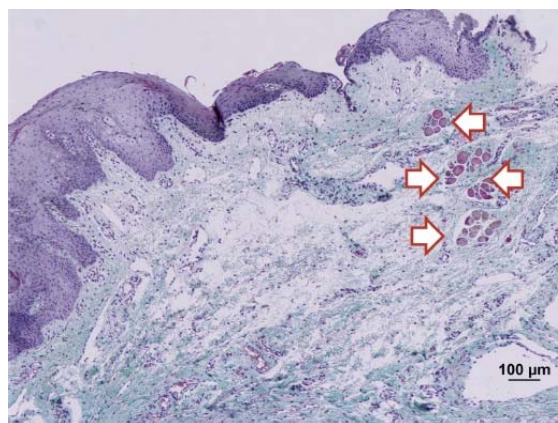


Figure 2: Photomicrograph of the short lingual frenulum. Small fascicles of muscle fibers (arrows) were observed in short frenulum. Masson's trichrome stain.

Striated skeletal muscle fibers were not observed in the anterior frenulum and in the short frenulum with anterior fixation.

Similar distribution of type I collagen and type III collagen was observed in all types of lingual frenulum. Although type I and III collagen were predominant, higher concentration of the type I collagen was observed in the deeper areas of the lingual frenulum. Under polarized light microscopy the type I collagen fibers presented a yellow, orange, or bright red color while the type III collagen fibers presented bright green color. The type III collagen fibers were predominant near the epithelium and around the vessels and muscle fibers (Figure 3).

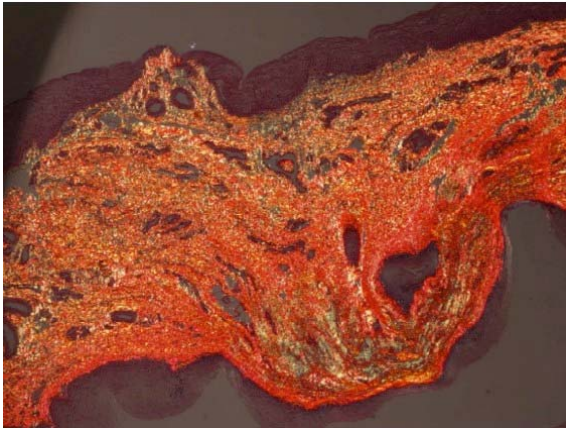


Figure 3: Photomicrograph of lingual frenulum. Distribution of collagen fibers. The bright red color (type I collagen) was predominant in the deep area of the section. The bright green color (type III collagen) was predominant near the epithelium and around the vessels and muscle fibers. Picosirius red stain.

Bundles of elastic fibers oriented and positioned near the epithelial lining were observed in short lingual frenulum (Figure 4).

Bundles of elastic fibers sparse and far from the epithelial lining were observed in anterior lingual frenulum and short frenulum with anterior fixation (Figure 5).

Table 1 shows the histological characteristics of the types of lingual frenulum.

DISCUSSION

The histological analyses demonstrated that the lingual frenulum has the same characteristics of the oral cavity as reported in the literature [25].

The frenulum with ankyloglossia had significant number of striated skeletal muscle fibers. That may be due to the entanglement of the collagen and elastic fibers of the mucosa with the muscle fibers of the genioglossus. In the lingual frenulum with ankyloglossia the high amount of type I collagen fibers in deep areas

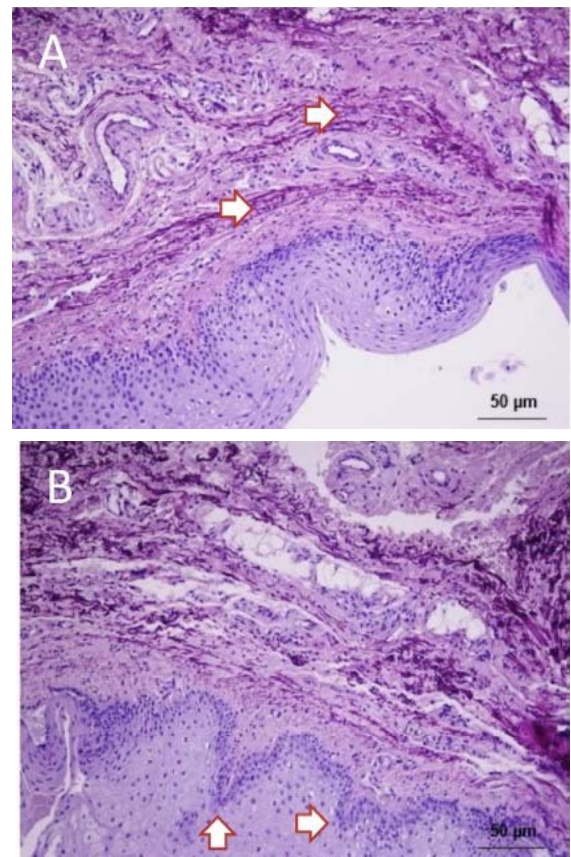


Figure 4: Photomicrograph of short lingual frenulum. Bundles of elastic fibers (violet) oriented and positioned near the epithelial lining were observed (A). Epithelial lining with papillary formations providing more resistance to the fold of mucous membrane were observed (B). Resorcin-Fuchsin stain.

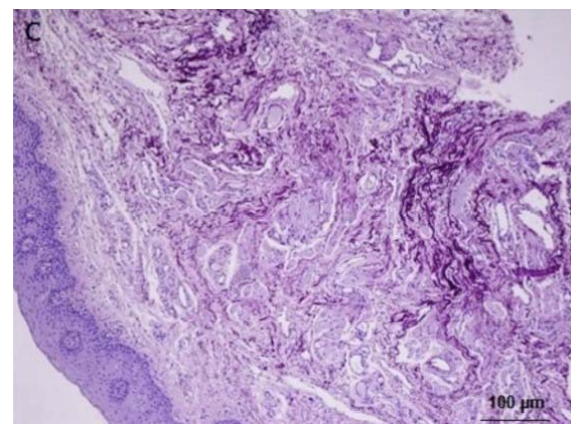


Figure 5: Photomicrograph of anterior lingual frenulum. Bundles of elastic fibers sparse and far from the epithelial lining were observed. Resorcin-Fuchsin stain.

may justify the restriction of the tongue movement. Type I collagen fibers are also present in ligaments and tendons [26], and have high traction resistance. Type III collagen wrapping vessels and nerves was also observed.

Table 1: Histological Characteristics of 4 Types of Lingual Frenulum

Type of frenulum	Muscle fibers	Elastic fibers	Collagen fibers
Ankyloglossia	Present	More compact, grouped, near the epithelial lining.	Type I
Short	Present	More compact, grouped, near the epithelial lining.	Type I
Short with anterior fixation	Absent	Sparse, not grouped, far from the epithelial lining.	Type I
Anterior	Absent	Sparse, not grouped, far from the epithelial lining.	Type I

In ankyloglossia and short frenulum, bundles of elastic fibers oriented and positioned near the epithelial lining contribute to the restriction of the tongue movement, interfering with the oral functions, mainly speech. That may be explained by the fact that speech requires refined tongue movements, specially lifting.

High concentration of type I collagen was detected in all types of lingual frenulum. Due to the fact that type I collagen is resistant to traction, stretching exercises may not be helpful to elongate the lingual frenulum. Therefore, lingual frenectomy may be considered the appropriate procedure to release the tongue in order to provide better oral functions.

CONCLUSION

The analyses of the histological sections demonstrated the characteristics of altered human lingual frenulum.

The results of the present study highlight the importance of further researches on the theme. There were certain limitations in this study regarding sample size.

CONFLICT OF INTEREST

The authors declare that they have no conflict of interest.

DISCLOSURE STATEMENT

No competing financial interests exist.

REFERENCES

- [1] Anderson KN, Anderson LE. Mosby's medical, nursing, and allied health dictionary. 5^a ed. St Louis, MO: Ed. Mosby, Inc; 1998; 661.
- [2] Singh S, Kent RD. Dictionary of speech-language pathology. San Diego, CA: Singular's 2000; 88.
- [3] Knox I. Tongue-tie and frenotomy in the breastfeeding Newborn. *NeoReviews* 2010; 11(9): 513-9. <http://dx.doi.org/10.1542/neo.11-9-e513>
- [4] Morita H, Mazerbourg S, Bouley DM, et al. Neonatal lethality of LGR5 null mice is associated with ankyloglossia and gastrointestinal distension. *Mol Cell Biol* 2004; 24: 9736-43. <http://dx.doi.org/10.1128/MCB.24.22.9736-9743.2004>
- [5] Berry J, Griffiths M, Westcott C. A double-blind, randomized, controlled trial of tongue-tie division and its immediate effect on breastfeeding. *Breast Med* 2011; 1-5.
- [6] Buryk M, Bloom D, Shope T. Efficacy of neonatal release of ankyloglossia: A randomized trial. *Pediatrics* 2011; 128: 280-8. <http://dx.doi.org/10.1542/peds.2011-0077>
- [7] Edmunds J, Hazelbaker A, Murphy JG, et al. Roundtable discussion: tongue-tie. *J Hum Lact* 2012; 28: 114-17. <http://dx.doi.org/10.1177/0890334411428588>
- [8] Forlenza GP, Black NMP, McNamara EG, et al. Ankyloglossia, exclusive breastfeeding, and failure to thrive. *Pediatrics* 2010; 125: e1500-4. <http://dx.doi.org/10.1542/peds.2009-2101>
- [9] Miranda BH, Milrou CJ. A quick snip: a study of the impact of outpatient tongue tie release on neonatal growth and breastfeeding. *J Plast Reconstr Aesth Surg* 2010; 63: e683-85. <http://dx.doi.org/10.1016/j.bjps.2010.04.003>
- [10] Edmunds J, Miles S, Fulbrook P. Tongue-tie and breastfeeding: a review of the literature. *Breast Rev* 2011; 19(1): 19-26.
- [11] Segal LM, Stephenson R, Dawes M, et al. Prevalence, diagnosis and treatment of ankyloglossia. *Can Fam Physician* 2007; 53(6): 1027-33.
- [12] Martinelli RLC, Marchesan IQ, Berretin-Felix G. Protocolo de avaliação do frênulo lingual para bebês: relação entre aspectos anatômicos e funcionais. *Rev Cefac* 2013; 15(3): 599-610. <http://dx.doi.org/10.1590/S1516-18462013005000032>
- [13] Braybrook C, Lisgo S, Doudney K, et al. Craniofacial expression of human and murine TBX22 correlates with the cleft palate and ankyloglossia phenotype observed in CPX patients. *Hum Mol Genet* 2002; 11: 2793-2804. <http://dx.doi.org/10.1093/hmg/11.22.2793>
- [14] Klockars T. Familial ankyloglossia (tongue-tie). *Int J Pediatr Otorhinolaryngol* 2007; 71(8): 1321-4. <http://dx.doi.org/10.1016/j.ijporl.2007.05.018>
- [15] Wallace AF. The tongue-tie controversy. *Nurs times*. 1964; 60: 527-28.
- [16] Kummer AW. Ankyloglossia: to clip or not to clip? That's the question. *The ASHA Leader* 2005.
- [17] Wright JE. Tongue-tie. *J Paediatr Child Health* 1995; 31: 276-8. <http://dx.doi.org/10.1111/j.1440-1754.1995.tb00810.x>
- [18] Brito SF, Marchesan IQ, Bosco CM, et al. Frênulo lingual: classificação e conduta segundo ótica fonoaudiológica, odontológica e otorrinolaringológica. *Rev CEFAC* 2008; 10(3): 343-51. <http://dx.doi.org/10.1590/S1516-18462008000300009>
- [19] Constantine AH, Williams C, Sutcliffe AG. A systematic review of frenotomy for ankyloglossia (tongue tie) in breast fed. *Infants Arch Dis Child* 2011; A62 96(Suppl 1): A1-A100.
- [20] Dollberb S, Botzer E, Grunis E, et al. Immediate nipple pain relief after frenotomy in breast-fed infants with ankyloglossia: a randomised, prospective study. *J Pediatr Surg* 2006; 41: 1598-1600. <http://dx.doi.org/10.1016/j.jpedsurg.2006.05.024>

- [21] Wallace AF. Tongue-tie. *Lancet* 1963; 2: 377-8.
[http://dx.doi.org/10.1016/S0140-6736\(63\)93057-5](http://dx.doi.org/10.1016/S0140-6736(63)93057-5)
- [22] Mazzochi A, Clini F. La brevitá del frenulo linguale: cosiderazioni cliniche e terapeutiche. *Ped Med Chir* 1992; 14: 643-46.
- [23] Marchesan IQ. Protocolo de avaliaão do frênulo da língua. *Rev CEFAC* 2010; 12(6): 977-89.
<http://dx.doi.org/10.1590/S1516-18462010000600009>
- [24] Marchesan IQ. Lingual Frenulum Protocol. *Int J Orofacial Myology* 2012; 38: 89-103.
- [25] Junqueira LC, Carneiro J. *Histologia básica*. 9ª ed. Rio de Janeiro: Guanabara Koogan 1999.
- [26] Benjamin M, Ralphs J. Tendons and ligaments: an overview. *Histol Histopathol* 1997; 12: 1135-44.

Received on 23-05-2014

Accepted on 29-05-2014

Published on 29-11-2014

DOI: <http://dx.doi.org/10.12974/2311-8687.2014.02.01.2>

© 2014 Martinelli *et al.*; Licensee Savvy Science Publisher.

This is an open access article licensed under the terms of the Creative Commons Attribution Non-Commercial License (<http://creativecommons.org/licenses/by-nc/3.0/>) which permits unrestricted, non-commercial use, distribution and reproduction in any medium, provided the work is properly cited.