

# EM CASE OF THE WEEK.

BROWARD HEALTH MEDICAL CENTER  
DEPARTMENT OF EMERGENCY MEDICINE



Care Warriors

Author: Karin Hwang, MS IV | Editors: Andrea Sarchi, DO ; Jason Mansour, MD

January 2017 | Vol 3 | Issue 21

## Lacerations of the Face

A 27 year-old male with no significant past medical history presents to the ED with a facial laceration secondary to trauma. The patient states that two hours prior, he was in a grocery store where had a confrontation with an ex-girlfriend who bit him on the forehead above his right eye. He denies fever, chills, nausea, vomiting, or any prior similar incidences. Patient does not recall his last tetanus shot. Vitals are 128/72, pulse 68 bpm, respiratory rate 12, O<sub>2</sub> saturation 99% on room air. On physical exam, the patient has a 3 cm x 2 cm superficial elliptical laceration on his forehead involving the superior border of his right eyebrow. The borders of the laceration are unable to be approximated without disfiguring the forehead and eyebrow. Which of the following approaches would be the most appropriate next step in treating the forehead laceration?

- A. Cleanse, irrigate, and proceed with primary closure; treat with cephalexin (Ancef)**
- B. Cleanse, irrigate, and proceed with primary closure; treat with amoxicillin-clavulanate (Augmentin)**
- C. Cleanse, irrigate, and allow for healing by secondary closure; treat with cephalexin (Ancef)**
- D. Cleanse, irrigate, provide amoxicillin-clavulanate (Augmentin) and consider referring to plastic surgery to close with a skin graft**

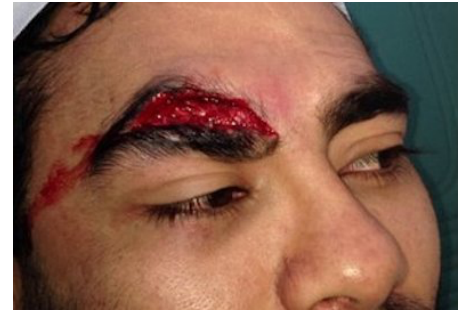

Figure 1. Depiction of a facial laceration<sup>1</sup>

Facial wounds are the most cosmetically apparent of all wounds and often involve many functional underlying structures. Therefore, careful evaluation and meticulous repair techniques are required for the best possible outcome. Three common principles to guide repair of facial and scalp lacerations include:

- 1) Cleanse, irrigate, and remove foreign object.
- 2) Limit debridement of skin edges due to excellent blood supply.
- 3) If local anesthetic infiltration distorts anatomy and hinders wound edge alignment, use regional nerve blocks.

*EM Case of the Week is a weekly "pop quiz" for ED staff.*

The goal is to educate all ED personnel by sharing common pearls and pitfalls involving the care of ED patients. We intend on providing better patient care through better education for our nurses and staff.

**BROWARD HEALTH MEDICAL CENTER**

Department of Emergency Medicine  
1625 SE 3rd Avenue  
Fort Lauderdale, FL 33316

The correct answer is **D, Cleanse, irrigate, provide amoxicillin-clavulanate (Augmentin) and consider referring to plastic surgery to close with skin graft.** All lacerations should be rinsed, cleansed and irrigated with high pressure and high volume of either normal saline or tap water. Because cephalexin (Ancef) has poor activity against *Eikenella*, a common human oral organism, cephalexin should be avoided. The agent of choice is amoxicillin-clavulanate (Augmentin). Trimethoprim-sulfamethoxazole (TMP-SMX, i.e. Bactrim) is also appropriate, especially if the patient is allergic to penicillin<sup>2</sup>.

Because facial and scalp lacerations have a low incidence of post-repair infection, primary closure can usually be done in wounds that are not obviously infected, regardless of the duration of time since the injury or even if the injury was from a bite.<sup>3</sup> In this case, the inability to approximate the wound edges without causing disfigurement indicates that it may require a surgery referral for laceration repair.

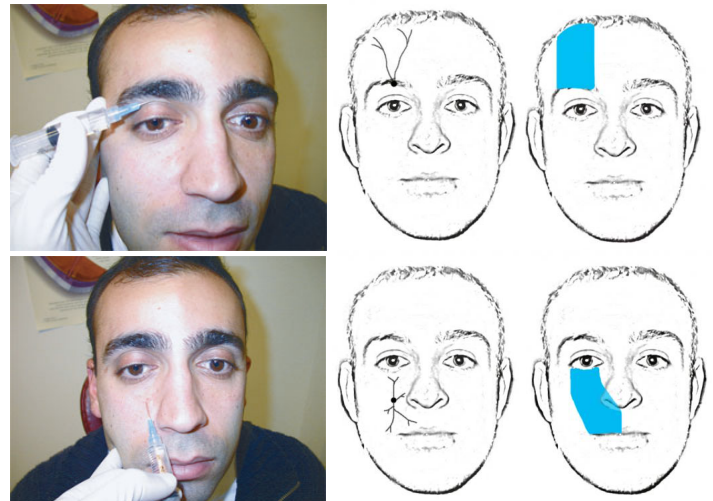
### Epidemiology and Etiology

Approximately 3 million people present annually to the ED for treatment of traumatic facial injuries in the United States, the majority being for minor soft tissue injuries that require first-aid care or primary closures. The primary cause ranges from domestic violence in inner metropolitan areas to sport participation in males 10-29 years old.<sup>4</sup> Of facial lacerations, injuries to the forehead, orbital region (eyelid/eyebrow) and lips comprise over 75% of all soft tissue injuries.<sup>5</sup>

### Anesthesia

Although children may need sedation for wound repair, anesthesia is primarily provided by topical, local or regional infiltration. Topical agents can provide adequate anesthesia in one-half of patients, reducing the need for local anesthetic injection. Local anesthetics (like lidocaine) with epinephrine can be used in highly vascular wounds to help control hemorrhage from small vessels; however, epinephrine use should be avoided in wounds such as the nasal septum and the tips of noses and ears due to the risk of necrosis. Meanwhile, regional infiltration such as nerve blocks (Figure 2) may be preferred if the laceration covers a large area

where injection of a local anesthetic may cause distortion. A good concept of nerve location and areas of distribution is required for nerve blocks.



**Figure 2.** The location of injection, pathway of the nerve, and area of anesthesia for a supraorbital (top) and infraorbital nerve block (bottom)<sup>6-8</sup>

### Repair of the Forehead

Forehead lacerations are categorized as either superficial (not involving the frontalis muscle) or deep (involving the frontalis muscle). Superficial lacerations can be closed with 6-0 non-absorbable interrupted suture, rapidly absorbable suture or tissue adhesive. Deep lacerations require closing the muscular layer with a buried 5-0 absorbable suture and epidermal layer closure with 6-0 non-absorbable sutures to avoid noticeable defects (see Figure 3 for recommended suture material and size by site of injury). Adhesives can be used if there is minimal tension, no hair in the area and only an epidermal closure is required.

### Repair of the Orbital Region

Prior to laceration repair, it is important to examine the structure and function of the eye, followed by involvement of the canthi, lacrimal system or penetration through the tarsal plate or lid margin. Eyelid injuries within 6 to 8 mm of the medial canthus are at risk for canalicular laceration, especially if associated with medial wall blow-out fractures.

For a list of educational lectures, grand rounds, workshops, and didactics please visit [BrowardER.com](http://BrowardER.com) and **click** on the **"Conference"** link.

*All are welcome to attend!*

# Warriors

Site of Injury	Suture Size	Suture Material (Alternative)	Anesthetic	Typical Removal
Cheek, forehead, or nose skin	5-0, 6-0	Nylon/Prolene (chromic for children or patients who cannot return for suture removal)	Cheek: Local or infraorbital nerve block; Nose: Local or Intranasal; Forehead: Local or supraorbital nerve block	3-5 days
External tongue mucosa	4-0	Chromic (Vicryl)	Local, inferior alveolar, or lingual nerve block	Never
Eyelid skin	5-0, 6-0	Nylon/Prolene (chromic)	Supra- or infraorbital nerve block	3 days
Frontalis (forehead) muscle	3-0, 4-0	Polydioxanone (Vicryl, chromic)	Local or supraorbital nerve block	Never
Galea (Scalp)	3-0, 4-0	Polydioxanone (Vicryl, chromic)	Local	Never
Lip or intraoral mucosa	4-0	Chromic (Vicryl)	Local, infraorbital, mandibular or mental nerve block	Never
Lip muscle	4-0	Vicryl/Dexon (chromic, polydioxanone)	Local, infraorbital, submandibular or mental nerve block	Never
Lip skin	5-0, 6-0	Nylon/Prolene (chromic)	Local, infraorbital or mental nerve block	3-5 days
Nasal mucosa	5-0	Chromic (Vicryl)	Intranasal	Never
Scalp skin	3-0, 4-0	Nylon/Prolene (staples, chromic)	Local	14 days
Subcutaneous tissue	4-0, 5-0	Vicryl (chromic)	Local or regional nerve block	Never
Tongue muscle	3-0	Vicryl (chromic, polydioxanone)	Local, inferior alveolar, or lingual nerve block	Never

**Figure 3.** Recommended suture size, suture material, anesthetic and removal time by site of injury<sup>2,9</sup>

Tissue adhesives should not be used near the eye, as adhesives may abrade the cornea or bond the lids together. Lacerations less than 1 mm at the lid edge do not need suturing and will spontaneously heal.

### Repair of the Lips

Initial evaluation of lip lacerations requires fully exploring lacerations, teeth and mucosa and identifying any missing, impacted or fractured teeth. While intraoral mucosal lacerations do not need to be sutured if they are isolated and wound edges spontaneously approximate (esp. 1 cm in length), through-and-through lacerations should be closed in layers. If the vermilion border (the junction of skin and red portion of the lip) is involved in any lip laceration, the first stitch should always be to precisely align the vermilion border, as even a 1mm variation in alignment is noticeable to the naked eye.

### When to Consult a Surgical Subspecialty

The choice to consult surgery is ultimately based on the physician's level of expertise, experience and comfort with managing the laceration. Situations in which one may consider surgical consultation include: wounds to the cheek with associated injury to the facial nerve, facial artery or parotid gland or ducts; lacerations involving the nasal cartilage or ala; eyelid or orbital lacerations that involve the eyelid margin or tarsal plate; complex wounds that require extensive revision or have significant skin loss that may require grafting; and wounds with associated fractures.

### Take Home Points

- Facial lacerations are best approached by area of injury, as they are the most cosmetically apparent and require meticulous repair for the best outcome.
- The decision to consult a specialist is dependent on the physician's experience and comfort level with managing the laceration.



### ABOUT THE AUTHOR

This month's case was written by Karin Hwang, a fourth year medical student from Nova Southeastern University College of Osteopathic Medicine. She completed her Emergency Medicine rotation at Broward Health North during October 2016. Karin is currently applying to residency and plans a career in General Surgery after graduation.

### REFERENCES

1. Byrne KM. Medscape. Medscape: Infraorbital Nerve Block. 2016. <http://emedicine.medscape.com/article/82660-overview>.
2. Byrne KM. Medscape: Supraorbital Nerve Block. 2014. <http://emedicine.medscape.com/article/82641-overview>.
3. Hollander JE, Camacho M. Assessment and Management of Facial Lacerations. 2015. *UpToDate*. 2015. <https://www.uptodate.com/contents/image?imageKey=ID%2F69328&topicKey=PSYCH%2F15250&source=see-link>.
4. Lee JH, et al. Analysis of Patients with Facial Lacerations Repaired in the Emergency Room of a Provincial Hospital. *Archives of Plastic Surgery*. 2015 Jan; 42(1): 34-49.
5. Photo: UFC's Faraal Natal Earns Worst Cut in MMA History Award. 2013. <http://www.bjpenn.com/mmanews/photo-ufcs-rafael-natal-earns-worst-cut-in-mma-history-award-warning-graphic/>.
6. Salam GA. Regional Anesthesia for Office Procedures: Part I Head and Neck Surgeries. *Am Fam Phy*. 2004 Feb 1;69(3):585-590.
7. Semer NB. (2007). Chapter 16: Facial Lacerations. *Practical Plastic Surgery for NonSurgeons*. [http://practicalplasticsurgery.org/docs/Practical\\_16.pdf](http://practicalplasticsurgery.org/docs/Practical_16.pdf).
8. Sutphin DD. Facial Soft Tissue Trauma. 2015. *Medscape*. <http://emedicine.medscape.com/article/2065124-treatment>.
9. Tintinalli J et al. (2015). Chapter 42: Face and Scalp Lacerations. (8) *Tintinalli's Emergency Medicine: A Comprehensive Study Guide*. <http://accessmedicine.mhmedical.com.ezproxy.local.library.nova.edu/content.aspx?sectionid=109428401&bookid=1658&jumpsectionid=109428420&Resultclick=2>.