

## Nighttime Bracing With the Providence Brace in Adolescent Girls With Idiopathic Scoliosis

Charles Roland d'Amato, MD, FRCS(C), Sean Griggs, MD, and Barry McCoy, MEd, CPO

**Study Design.** A prospective study was conducted of 102 consecutive female patients with adolescent idiopathic scoliosis. Those patients with Risser 0, 1, and 2 met the criteria for inclusion and were treated only with the Providence brace.

**Objectives.** To report the authors' experience with a hypercorrective nighttime brace and to evaluate the results with respect to risk factors for progression. Second, the study compares results with expectations from the natural history as reported by others.

**Summary of Background Data.** Compliance with full-time brace treatment for adolescent idiopathic scoliosis has been a problem. Since the introduction of the Milwaukee brace, alternatives such as low-profile braces, reduced wearing schedules, and nighttime only bracing have been tried. However, many factors influence the success or failure besides compliance. These include in-brace correction, brace design, and the orthotist's skills. This is the first report of the results of treatment with a new nighttime brace that is made with CAD/CAM technology that can achieve higher initial in-brace corrections than other reported methods.

**Methods.** Results were analyzed with respect to curve size, curve pattern, maturity, and level of the primary curve apex. Both compliant and noncompliant patients were included in the analysis. A univariate analysis was done on those factors thought to influence success with bracing using the Pearson  $\chi^2$  test.

**Results.** The average initial in-brace correction with a supine radiograph was 96% for major curves and 98% for minor curves. Seventy-five patients (74%) did not progress  $>5^\circ$  and 27 patients (26%) progressed  $\geq 6^\circ$  or went on to surgery. Twenty-nine percent of Risser 0 or 1 patients progressed and 17% of patients Risser 2 progressed. The risk of progression anticipated by natural history data, which included all curve patterns, was 68% for Risser 0 and 1 and 23% for Risser 2. Risser 3 and 4 patients were excluded from the study. Seventy-six percent of patients with curve apexes between T8 and L1 had successful outcomes using the Providence brace. This is compared with a 74% success rate in the prospective Scoliosis Research Society study of patients wearing a thoraco lumbar sacral orthosis for 16 hours per day with curve apexes between T8 and L1. With the Providence brace, 63% of thoracic curves and 65% of double curves were successful. Ninety-four percent of lumbar curves and 93% of thoracolumbar curves were successful.

**Conclusion.** Excellent initial in-brace correction of adolescent idiopathic scoliosis was observed with this computer-designed and manufactured recumbent brace. Patients with high apex curves cephalad to T8 ( $n = 31$ ) had a success rate of 61% compared with a success rate of 79% ( $n = 71$ ) if the apex was at or below T9. Compared with previous natural history and the prospective study data, the Providence brace is effective in preventing progression of adolescent idiopathic scoliosis for curves  $<35^\circ$ . It was effective for larger curves with a low apex. The authors' experience with patients with curves  $>35^\circ$  ( $n = 8$ ) is too small to validate its effectiveness for larger curves with a higher apex. [Key words: scoliosis, nighttime bracing, treatment] **Spine 2001;26:2006-2012**

Poor compliance with a full-time bracing program for the treatment of adolescent idiopathic scoliosis (AIS) has been a well-recognized problem. A search for alternatives more acceptable to adolescents has included the development of underarm braces and part-time and nighttime-only bracing in an effort to address the stresses associated with a full-time bracing program.<sup>1,2,9,10</sup> In 1990 Price et al published their early report using the Charleston Nighttime Bending Brace and recently reported their long-term follow-up results.<sup>18</sup> Climent and Sanchez studied the effect of different types of spinal orthoses on psychosocial functioning, sleep disturbance, back pain, body image, and back flexibility.<sup>5</sup> They found that a nighttime-only bracing program had the least negative effect on these parameters. They recommended using a brace with the least impact on quality of life in cases in which the different braces are similarly effective.

The Providence brace was developed when it was observed that significant correction of scoliotic curves could be achieved using an acrylic frame to apply direct corrective forces to the patient. The frame (Figure 1) was originally developed to demonstrate supine spinal flexibility radiographically for preoperative planning. The frame works by the application of controlled, direct, lateral, and rotational forces on the trunk to move the spine toward the midline or beyond the midline. A plaster impression of the patient was taken on the frame with corrective forces applied to the spine. As with other nighttime braces, we observed greater radiographic brace correction and often overcorrection. The brace is now fabricated using computer-aided design and manufacturing techniques.

We are reporting our experience with the first consecutive 102 female patients with AIS who have completed treatment. Our study includes both compliant and non-compliant patients. The results are compared with the natural history data published by Lonstein and Carl-

From the Department of Orthopaedic Surgery, Brown University School of Medicine, Providence, Rhode Island.

Acknowledgment date: February 17, 2000.

First revision date: October 27, 2000.

Second revision date: February 5, 2001.

Acceptance date: May 1, 2001.

None of the authors has a financial interest in the manufacturer of the Providence brace or Spinal Technologies, Inc., or has received anything of value beyond the normal compensation for clinical services rendered.

Device status category: 6.

Conflict of interest category: 12.

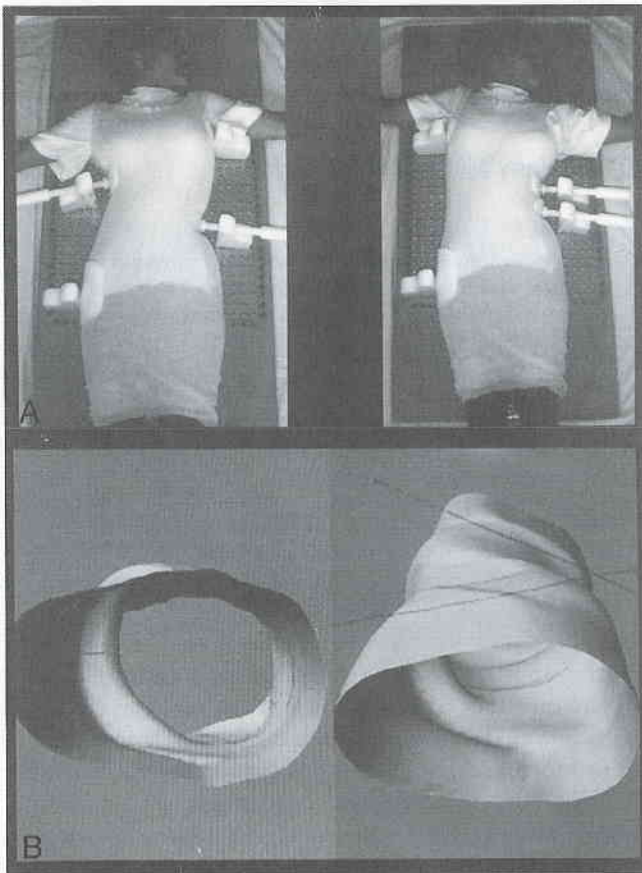


Figure 1. **A**, Measuring frame. **B**, Mold made on CAD/CAM milled bank.

son<sup>13</sup> and the more recent multicenter prospective study published by Nachemson and Peterson.<sup>16</sup>

The brace is fabricated of polypropylene plastic from measurements or a plaster impression. The patient is placed on a polycarbonate measurement and casting board (Figure 1). The board has a grid of holes on its surface for placement of the bolsters to apply corrective forces and stabilization to the spine with reference to the patient's midline. They enable one to accurately apply forces to the lateral surfaces of the patient's body. Information from a standing radiograph of the patient's spine serves as a guide for the placement of the stabilizing and corrective bolsters used in the casting or measurement process.

Originally, the patient is removed from the board and wrapped in a standing plaster jacket and returned to the board, and the bolsters are returned to the determined settings. The dried plaster jacket is then removed and used as a female mold to make a male plug on which the brace is custom made. At the outset all of our braces were fitted in this manner. Over the past 6 years, cast molds were scanned into a CAD/CAM computer (Spinal Technologies, West Yarmouth, MA) enabling the brace fabrication to be done with measurements alone in 95% of cases.

Delrin bolsters (Dupont, Division of Ashland Chemical, Columbus, OH) or stabilizing blocks are used at the

end points of curves, and pressure blocks are located at the apexes of the curves to be treated. Control of rotation is accomplished in two different ways. In the lumbar spine the pressure pad is located between the iliac crest and the twelfth rib. When pressure is applied this pad creates a posterior lateral pressure as it is tightened because of a wedging of the pad against the surface of the board. Derotation in the thoracic section of the brace is accomplished on the CAD/CAM model. The thoracic section is separated from the lumbar section. Then the thoracic portion is rotated a specific amount and re-joined to the lumbar section of the model.

The amount of corrective force used is monitored with the use of pressure-sensitive film (Fuji, Inc., ITOCHU, Montreal, Canada). The average lumbar pressure measured inside the brace is 7.4 lb/in<sup>2</sup> in the lumbar spine and 5.4 lb/in<sup>2</sup> in the thoracic spine. Pressure measurements are helpful in avoiding excessive pressures that can lead to intolerance of the brace and the development of skin problems. Pressure testing gives the orthotist a guideline so that he/she doesn't harm the patient. When the patient outgrows the brace, it becomes tight circumferentially, but there is a decrease in pressure at the apex of the curve or curves. Consequently, pressure readings serve to evaluate the ongoing effectiveness of the brace as the patient grows.

A computer program selects a CAD/CAM model based on the measurements from the polycarbonate board. The model is further modified to match the patient's measurements. It is then milled out in a computerized milling machine. The CAD/CAM program gives the orthotist unlimited control over the model with the ability to interchange top and bottom and right and left halves and rotate the model as well as increase or decrease any dimension on the model. Examples of the finished braces used for various curve patterns are shown in Figure 2. An example showing overcorrection of two curves with their apexes in opposite directions is given in Figure 3.

## ■ Materials and Methods

From 1992 through 1999, 102 consecutive female patients with AIS who met the criteria for inclusion and who were treated with the Providence brace at nighttime were studied prospectively. All patients have completed treatment with a minimum follow-up of 2 years after the cessation of brace wear and an average follow-up of 2.6 years (range, 2.1–6.9 years). All data were collected at the time of each visit, and radiographs were measured using the Cobb technique by one author (S.G.). Patient information, including age, sex, menstrual history, and eventually total time in the brace, was recorded.

To be included in this study, patients had to be over the age of 10 years and diagnosed with idiopathic scoliosis. Curves between 20° and 42° by Cobb measurement were included. Curves between 20° and 25° were observed for progression of >5° before treatment was instituted. Curves >25° were braced on first presentation if significant spinal growth was considered probable based on the Risser sign or menarchal status. Patients

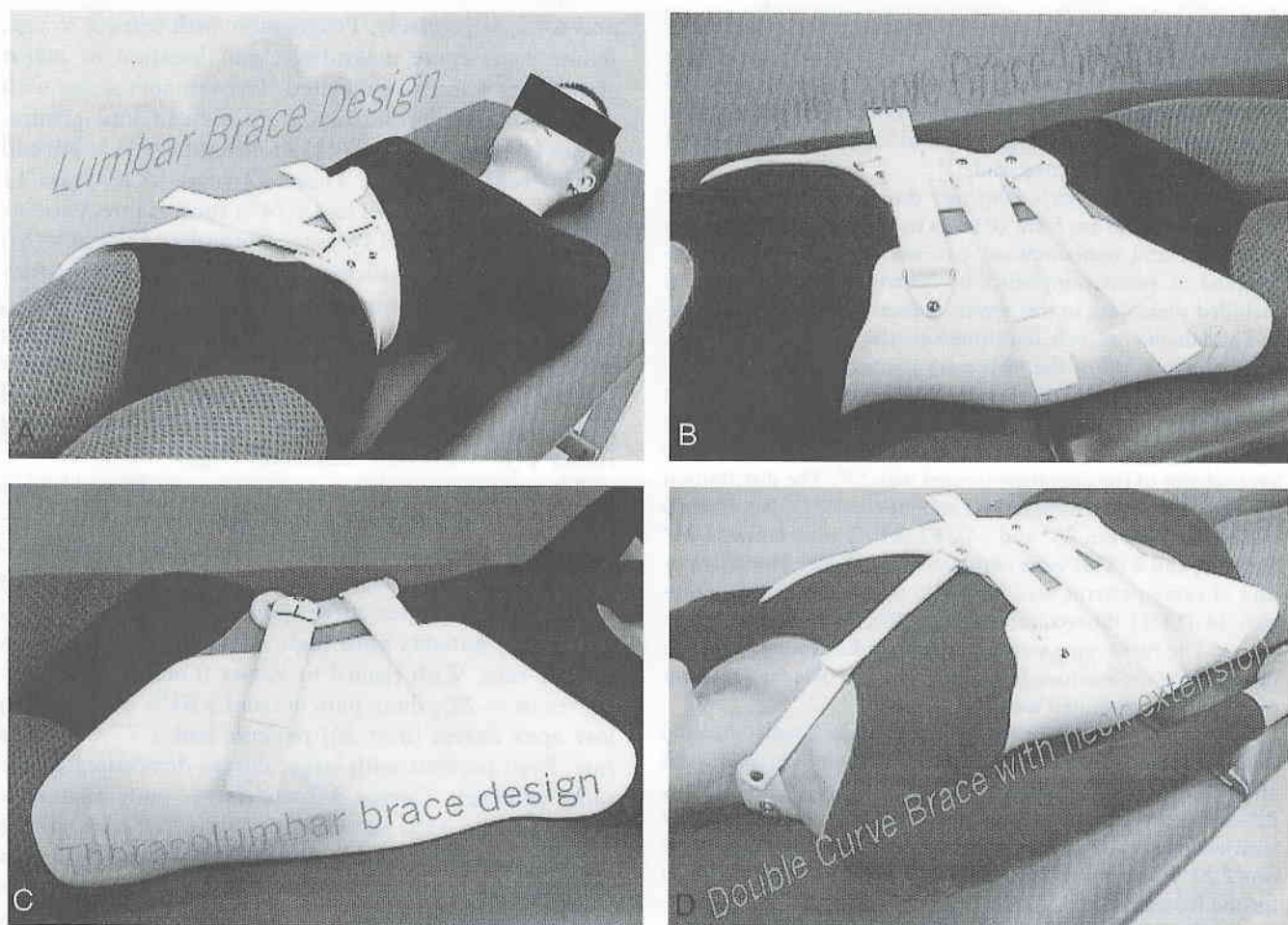


Figure 2. Providence brace. **A**, Lumbar brace design. **B**, Thoracolumbar. **C**, Double curve. **D**, High thoracic curve extension.

with Risser 2 were included only if their curves were progressing while under observation.

Patients were asked to wear the brace for a minimum of 8 hours per night. For the first 2 weeks patients were instructed to wear the brace at a loose setting to become acclimated to sleeping in the brace. After this break-in period the brace was grad-

ually tightened according to the pressure readings taken in the brace. At the first office visit after delivery of the brace, a supine radiograph was done in the brace to assess the percentage of correction of each curve measured by the method of Cobb. No further radiographs were taken with the brace on unless problems were encountered or a new brace was needed because of growth or fitting problems. The patients were seen at 3-month intervals to check the brace for comfort and to see if apical pressures were being maintained. Standing posteroanterior radiographs out of the brace were taken at no more than 6-month intervals. All patients had removed the brace at least 4 hours beforehand. Bracing was continued until no further growth was occurring by measuring standing height over two consecutive visits at least 6 months apart and Risser 4. The patients were required to have attained regular menses at least 18 months before stopping brace wear unless they were observed to have stopped all growth by serial height measurement.

Curve patterns were recorded by curve type: thoracic, thoracolumbar, lumbar, or double major. A double major curve was defined as two curves within 5° of each other by Cobb measurement. The initial correction of the curves achieved in the brace was recorded for the different curve types and for each curve in a double curve pattern. Bracing was considered successful if  $\leq 5^\circ$  of progression occurred, and to have failed if there were  $> 5^\circ$  of progression or if surgery were performed. Successes and failures were measured and analyzed for age, menarchal status, curve size, curve pattern, Risser sign, and

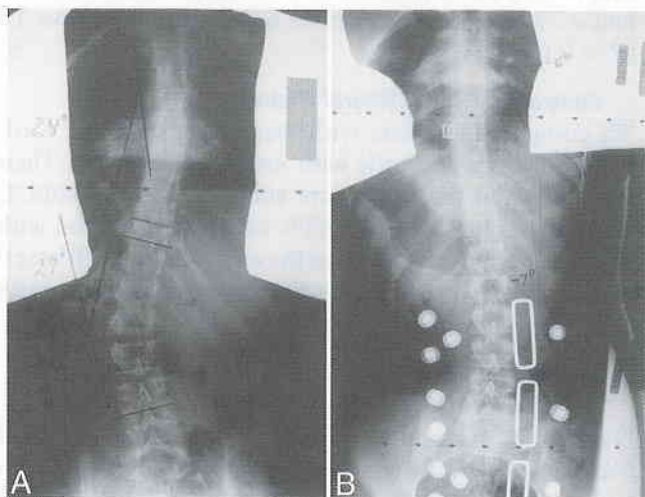


Figure 3. In-brace overcorrection of both curves (**A** and **B**) in a double-curve pattern.

major curve apex. A high apex curve was defined as a primary curve with an apex at T8 or higher. The low apex curves were curves with the apex below T8. The results were also analyzed comparing success rates with the risk of progression using the same parameters as the largest natural history study<sup>13</sup> and the only available prospective study.<sup>16</sup>

There were 102 girls who met the criteria for inclusion. Patients ranged in age from 10 years to 16 years 6 months. Both compliant and noncompliant patients are included. We attempted to assess compliance by questionnaire but have not included these data in this report because the data are subjective and do not, as such, contribute anything of scientific value. Sixty-two percent of the girls were premenarchal at the time bracing was begun. Eighty-two percent of the patients (n = 84) were Risser 0 or 1 and 18% were Risser 2 (n = 18). The average age at the beginning of brace wear was 13 years 1 month. The average size of the curvature treated was 27°. The distribution of major curve magnitudes was as follows: 32 (31%) patients had curves between 20° and 24°, 62 (61%) were between 25° and 34°, and 8 (8%) were between 35° and 42°. The distribution of curve patterns was 24 (24%) thoracic, 18 (17%) lumbar, 14 (14%) thoracolumbar, and 46 (45%) double major curves. The curve types were defined according to the definition proposed by the Scoliosis Research Society.<sup>20</sup> The total number of major curves treated was 148.

All of the patients included in this study have completed treatment and have been followed for a minimum of 2 years after bracing was stopped and an average of 2.6 years (range, 2.1–6.9 years) after cessation of bracing. The average time of treatment with a brace for the least mature Risser 0 patients was 2.25 years. It was 1.7 years for the Risser 1 and 1.6 years for the Risser 2.

A univariate analysis of the variables thought to influence the success or failure of preventing curve progression by >5° were studied. Pearson  $\chi^2$  tests were used to see if success rates were dependent on the following individual factors: menstrual status, curve apex of T8 or higher, Risser sign, and in-brace correction of >75%.

## ■ Results

The average initial correction with a supine in-brace radiograph of the all major and all compensatory was 96% and 98%, respectively. The average percentage of Cobb angle initial in-brace correction for each curve type while the patient was wearing the brace was 94% for thoracic curves, 111% for thoracolumbar curves, 103% for lumbar curves, and 90% and 91%, respectively, for both curves of a double curve pattern (Figure 4).

Overall, 75 (74%) of the 102 patients in the study were successful progressing  $\leq 5^\circ$ . Twenty-seven patients (26%) progressed  $\geq 6^\circ$  or went on to spinal fusion (n = 18). Those patients who underwent surgery began bracing with curves that averaged 31° at the onset of bracing. Of patients with primary thoracic curves, 15 of 24 (63%) were successful. Seventeen of 18 patients (94%) with a lumbar curve were successful. Thirteen of 14 (93%) patients with thoracolumbar curves were successful. Thirty of 46 patients (65%) with double curves were successful (Figure 5). For those patients Risser 0 or 1 with thoracic (22), lumbar (13), thoracolumbar (10), and double major (39) curves, the success rates were 64%, 92%, 90%,

and 64% respectively. Progression with respect to age, Risser sign, curve magnitude, and location of major curve apex was also evaluated. To evaluate success with respect to age the patients were divided into groups. Those 10 years to 11 years 11 months of age (n = 20) had a 60% rate of success. Those 12 years to 13 years 11 months of age (n = 58) had a 74% success rate. Patients between 14 years and 16 years 6 months of age (n = 24) had an 83% rate of success. The results were also evaluated by curve magnitude, for curves 20–24° (n = 32), 25–34° (n = 62), and 35–42° (n = 16). Success rates in these categories were 81%, 71%, and 63%, respectively (Figure 6). With regard to Risser sign, 67% percent of Risser 0 (n = 63), 86% of Risser 1 (n = 21), and 83% of Risser 2 (n = 18) were successful (Figure 7).

Those patients with a major curve apex T8 and higher were considered to have a high apex curve. Those patients with a major curve apex T9 and lower were considered to have a low apex curve. Overall, 71 patients (69%) had a low apex curve and had a 79% success rate. Thirty-one patients with high apex curves had a 61% success rate. With regard to Risser 0 and 1 high apex curves (n = 28), these patients had a 61% success rate; low apex curves (n = 56) patients had a 77% success rate. Even patients with larger curves demonstrated the same tendency. Curves 35° and larger with high apex (n = 3) had a 33% success rate, while low apex curves (n = 5) had a 77% success rate. In Risser 0 and 1 patients with high apex curves (n = 3) and high magnitude curves (>35°) the success rate was 33%, while low apex curves (n = 5) and high magnitude curves (>35°) had an 80% success rate (Figure 8).

The univariate analysis of success for curves corrected on initial in-brace radiograph of greater than or less than 75% showed that the more flexible curves did better as one would expect: 78% success *versus* 43%; this difference was significant ( $P = 0.012$ ). Risser 2 patients had an 83% success rate *versus* 71% for Risser 0 or 1 ( $P = 0.050$ ). This is consistent with expectations from the natural history data. Those with a curve apex lower than T8 had a 79% success rate *versus* 61% for those above T8 ( $P = 0.034$ ).

### Comparison With Natural History

We compared our data with that of Lonstein and Carlson<sup>13</sup> for boys and girls with untreated scoliosis. Their study showed that immature subjects, Risser 0 and 1, with curves 20–29° had a 68% rate of progression with all curve patterns included in the analysis. In our Risser 0 and 1 patients treated with the Providence brace, with curves 20–29°, only 23% progressed.

### Comparison With the Scoliosis Research Society Prospective Brace Study Data

Our results were also compared with the findings of Nachemson and Peterson in their nonrandomized controlled multicenter prospective study.<sup>16</sup> They studied girls with AIS with curves between 25° and 35° with apexes between the T8 and L1 that had worn an under-




Figure 4. The percentage of initial in-brace correction for different curve types.

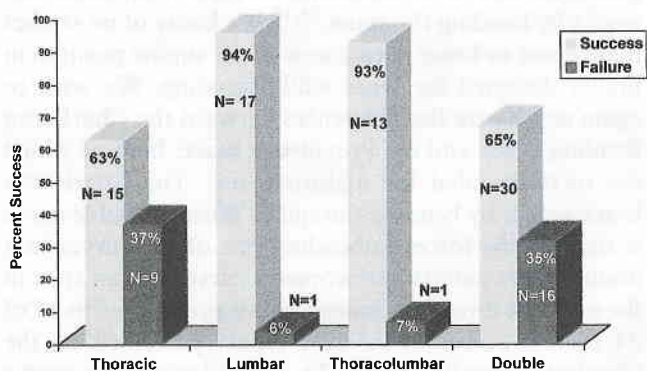


Figure 5. Percent success of the different curve types.

arm thoraco lumbar sacral orthosis (TLSO). All patients were asked to wear their braces 16 hours per day. According to their survivorship analysis, 74% who wore a brace were successful in avoiding progression of  $\geq 6^\circ$ . Seventy percent of their patients had attained menarche when treatment began and 34% were Risser 2–4. In the brace group 32% had thoracolumbar curves with apices at T11 or T12. This is compared with 19% in the observation only group and 10% in the electrical stimulation

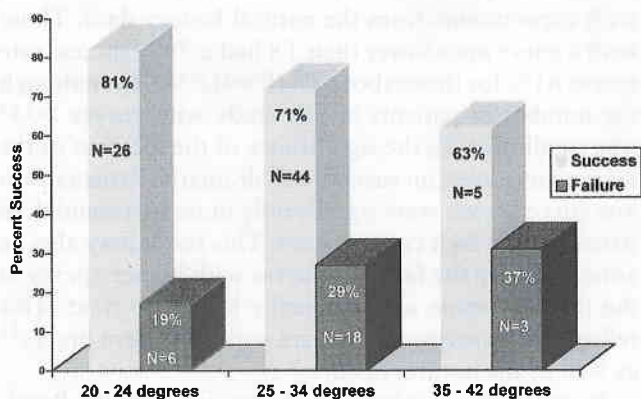


Figure 6. The success rate with respect to curve magnitude.

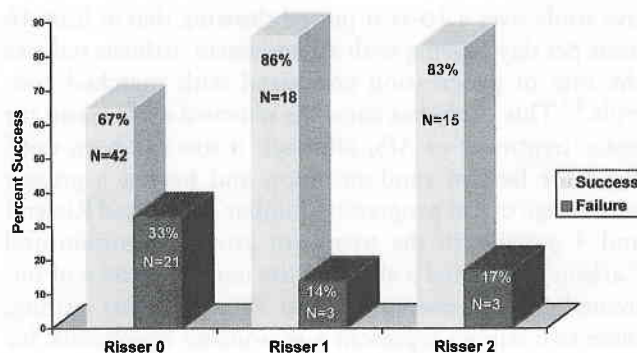


Figure 7. The success rate with respect to Risser sign.

group, which served as controls. In patients treated with the Providence brace, 82% of the patients were Risser 0 or 1 and 36% had an apical vertebra cephalad to T12. Peterson and Nachemson, in a subsequent study,<sup>17</sup> have shown that a Risser sign of 0 or 1, an apical vertebra cephalad to T12, and spinal imbalance of  $\leq 10$  mL were prognostic of curve progression of  $>6^\circ$ .

A similar analysis of our study group comparing patients with curve apices between T8 and L1 measuring 25–35° found that 76% were successful with nighttime only treatment. Twenty-nine percent were postmenarchal and 15% were Risser 2. The number of patients in our study is smaller, but their characteristics are similar except that Risser 3 and 4 patients are excluded. The results of night bracing with the Providence brace are similar to the 16-hour/day TLSO patients' results for curves between 25° and 35° in the prospective study.

### Complications

Complications have occurred in five patients. Four patients developed bursa forming over the ribs, which were resolved with brace modification. One patient developed a rash after an antifungal powder was placed on the skin by the parent in an attempt to treat reddening of the skin.

### Discussion

Many authors have reported success in treating AIS with full-time bracing using the Milwaukee brace<sup>4,14</sup> and various total contact thermoplastic braces.<sup>2,9,15</sup> Peterson and Nachemson conducted the first multicenter prospec-

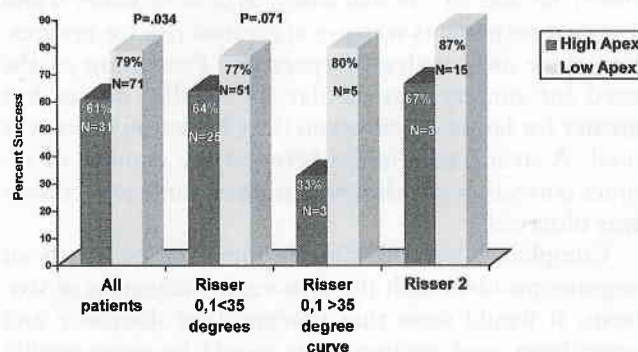


Figure 8. The influence of curve apex on success or failure with respect to Risser sign and curve size.

tive study over a 10-year period showing that at least 16 hour per day bracing with an underarm orthosis reduces the rate of progression compared with matched controls.<sup>17</sup> This study has caused a renewed enthusiasm for brace treatment of AIS, although it too has been criticized for lack of randomization and having a greater percentage of less progressive lumbar curves and Risser 3 and 4 patients in the treatment group.<sup>7</sup> Lonstein and Carlson<sup>13</sup> reported a study of the natural history of untreated curves between 20° and 29°. As of this writing, these two studies represent a reasonable benchmark for comparison of the result of any bracing program for AIS. Our results compare favorably with these two studies that address smaller curves. Similar natural history data are not available for more challenging curves >30°. Bunnell found that 67% of curves between 30° and 40° progressed  $\geq 5^\circ$  and 48% progressed only 10°.<sup>3</sup> In our study there were only eight patients with curves >35°. Although 63% were successful in avoiding progression, it is not possible to support or condemn the nighttime use of the Providence brace for curves >35°.

The minimum "dose," or number of hours of brace wear for treatment to be effective, is not known and may vary with curve size, location of major curve apex, curve flexibility, curve pattern, patient growth factors, and brace design. Wiley et al studied the effectiveness of the Boston brace on larger curves between 35° and 45°.<sup>21</sup> They found that compliant patients who wore their braces for >18 hours per day had less progression than those who wore the brace for  $\leq 12$  hours per day. In addition, they found a correlation between greater in-brace correction and compliance. Few scientific data are available on how spinal braces control progression of deformity in the growing spine. A case-control study comparing the Boston brace with the Charleston nighttime brace using two consecutive series of immature patients casts doubt on the sufficiency of nighttime only bracing, particularly for curves >35°.<sup>12</sup> Katz et al retrospectively studied 319 patients treated at the same institution with either a Boston or a Charleston brace to determine if the two different orthoses were equally effective. They found that with the Charleston brace there was an 83% rate of progression of >5° compared with 43% with the Boston brace for patients with curves between 36° and 45°. In that study, as in ours, Risser 0 and 1 immature patients who are at greatest risk for progression were also analyzed separately. Prevention of the need for surgery was similar for smaller curves but greater for larger curves when the Charleston brace was used. A strong correlation between the amount of in-brace correction and the prevention of curve progression was observed.

Compliance with bracing by some adolescents is an ongoing problem with the orthotic management of scoliosis. It would seem that bracing done discreetly and away from peer environments would be more readily acceptable to adolescent patients. DiRaimondio et al thought that <15% of their patients were fully compli-

ant with a 23-hour per day schedule.<sup>8</sup> Green tried part-time wear for 16 hours per day, which was thought to be as effective.<sup>10</sup> Objective measurement with actual monitoring of brace wear has been tried and suggests that actual brace compliance is much less than claimed by patients or parents.<sup>11</sup> Our questionnaire data were gathered at two points of contact with the patient, and the worse response was recorded. We recognize that this method of gathering data is subjective. However, this information is essential to the physician and orthotist treating patients with scoliosis because it helps identify problems with the brace that may need to be addressed.

The Charleston Nighttime Bending Brace, introduced by Price et al, extended the concept of reduced wearing schedule, further requiring brace wear a minimum of 8 hours per night during sleep.<sup>18,19</sup> They reported good results in preventing progression compared with historical brace controls. They also demonstrated a higher degree of in-brace correction with the recumbent brace that works by bending the spine.<sup>18,19</sup> We know of no studies that report in-brace corrections in the supine position in braces designed for wear while standing. We wish to again emphasize the differences between the Charleston Bending Brace and the Providence brace, both of which are recommended for nighttime use. The Charleston brace works by bending the spine. When a double curve is treated, the forces unbending one of the curves in a double curve pattern can worsen a curve with an apex in the opposite direction. Indeed, this was observed in 11 of 24 double curves in the first report published on the Charleston Bending Brace. The Providence brace works by the application of opposing forces and does not bend the spine; rather, it pushes the curve apexes to the midline. We did not experience permanent worsening of secondary curves at the final follow-up.

Factors that are important in predicting success are initial in-brace correction, Risser sign, and location of major curve apex. Our univariate analysis of success for curves corrected on initial in-brace radiograph of greater than or less than 75% showed that the more flexible curves did better as one would expect: 78% success *versus* 43%. This difference was significant ( $P = 0.012$ ). Risser 2 patients demonstrated an 83% success rate *versus* 71% for Risser 0 or 1 ( $P = 0.050$ ). This is consistent with expectations from the natural history data. Those with a curve apex lower than T8 had a 79% success rate *versus* 61% for those above T8 ( $P = 0.034$ ). Even though the number of patients in this study with curves >35° was small ( $n = 8$ ), the significance of the location of the major curve apex on success was dramatic. Patients with low curve apexes were significantly more successful than patients with high curve apexes. This result may also be anticipated by the fact that curves with higher apexes in the thoracic spine are technically harder to treat. This reflects the experience of others with underarm braces<sup>21</sup> as well as the natural history.<sup>6</sup>

In conclusion, nighttime only bracing with the Providence brace has been effective in preventing curve pro-

gression in 74% of our patients with AIS, particularly for curves  $<35^\circ$ . In our series of patients, the Providence brace provides  $>75\%$  initial in-brace correction in 86% of major curves with an average initial in-brace correction of 96%. More flexible thoracolumbar and lumbar curves were often overcorrected on the initial in-brace supine radiograph. The ability to standardize the fitting and manufacture of this brace, using computer-aided design and manufacturing technology, may assist orthotists in providing a consistent product. This study has few subjects with curves  $>35^\circ$ ; therefore, it is recommended with caution as the sole primary treatment for larger curves, especially if the major curve apex is T8 or higher.

Currently, if curve progression occurs in any of our patients, it is our practice to add a TLSO for day use in addition to the night brace. In this study such patients were all considered failures. Currently, the senior author does not offer nighttime only bracing for curves  $>35^\circ$  with a major curve apex T8 or higher. For curves  $>35^\circ$  with low apexes the Providence brace is offered with the provision that a daytime TLSO will be added if progression of the curve is observed. It is thought that one can little afford to risk progression in these patients, especially if they have a high apex curve and are willing to wear a brace on a "full-time" schedule.

### Acknowledgments

The authors thank Bethany Coia, MSN, and Nancy Seavor, RN, for their assistance in data collection and Steve Reinert for performing the statistical analysis.

### Key Points

- A total of 102 immature Risser 0–2 girls with AIS were prospectively treated with nighttime bracing.
- Overall, 74% did not progress  $>5^\circ$ .
- Initial supine in-brace radiograph corrections averaged 96%.
- The device is fabricated using CAD/CAM techniques.

### References

1. Allington NJ, Bowen JR. Adolescent idiopathic scoliosis: treatment with the Wilmington brace. A comparison of full-time and part-time use. *J Bone Joint Surg Am* 1996;78:1056–62.
2. Bassett GS, Bunnell WP, MacEwen GD. Treatment of idiopathic scoliosis

- with the Wilmington brace: results in patients with a twenty to thirty-nine-degree curve. *J Bone Joint Surg Am* 1986;68:602–5.
3. Bunnell WP. The natural history of idiopathic scoliosis before skeletal maturity. *Spine* 1986;11:773–6.
4. Carr WA, Moe JH, Winter RB, et al. Treatment of idiopathic scoliosis in the Milwaukee brace. *J Bone Joint Surg Am* 1980;62:599–612.
5. Climent JM, Sanchez J. Impact of the type of brace on the quality of life of adolescents with spine deformities. *Spine* 1999;24:1903–8.
6. Cochran T, Nachemson A. Long-term anatomic and functional changes in patients with adolescent idiopathic scoliosis treated with the Milwaukee brace. *Spine* 1985;10:127–33.
7. Dickson RA, Weinstein SL. Bracing (and screening): yes or no? *J Bone Joint Surg Br* 1999;83:193–8.
8. DiRaimondo CV, Green NE. Brace wear compliance in patients with adolescent idiopathic scoliosis. *J Pediatr Orthop* 1988;8:143–6.
9. Emans JB, Kaelin A, Bancel P, et al. The Boston bracing system for idiopathic scoliosis: follow-up results in 295 patients. *Spine* 1986;11:792–801.
10. Green NE. Part-time bracing of adolescent idiopathic scoliosis. *J Bone Joint Surg Am* 1986;68:738–42.
11. Houghton GR, McInerney A, Tew A. Brace compliance in adolescent idiopathic scoliosis. *J Bone Joint Surg Br* 1997;69:852.
12. Katz DE, Richards BS, Browne RH, et al. A comparison between the Boston brace and the Charleston bending brace in adolescent idiopathic scoliosis. *Spine* 1997;22:1302–12.
13. Lonstein JE, Carlson JM. The prediction of curve progression in untreated idiopathic scoliosis during growth. *J Bone Joint Surg Am* 1984;66:1061–71.
14. Lonstein JE, Winter RB. The Milwaukee brace for the treatment of adolescent idiopathic scoliosis: a review of one thousand and twenty patients. *J Bone Joint Surg Am* 1994;76:1207–21.
15. McCollough NC, Schultz M, Javech N, et al. Miami TLSO in the management of scoliosis: preliminary results in 100 cases. *J Pediatr Orthop* 1981;1:141–52.
16. Nachemson AL, Peterson LE. Effectiveness of treatment with a brace in girls who have adolescent idiopathic scoliosis: a prospective, controlled study based on data from the Brace Study of the Scoliosis Research Society [comments]. *J Bone Joint Surg Am* 1995;77:815–22.
17. Peterson LE, Nachemson AL. Prediction of progression of the curve in girls who have adolescent idiopathic scoliosis of moderate severity: logistic regression analysis based on data from the Brace Study of the Scoliosis Research Society. *J Bone Joint Surg Am* 1995;77:823–7.
18. Price CT, Scott DS, Reed FE Jr, et al. Nighttime bracing for adolescent idiopathic scoliosis with the Charleston bending brace: preliminary report. *Spine* 1990;15:1294–9.
19. Price CT, Scott DS, Reed FR Jr, et al. Nighttime bracing for adolescent idiopathic scoliosis with the Charleston bending brace: long-term follow-up. *J Pediatr Orthop* 1997;17:703–7.
20. Terminology Committee of the Scoliosis Research Society. A glossary of terms. *Spine* 1976;1:57–8.
21. Wiley J, Thompson J, Mitchel T, et al. Effectiveness of the Boston brace in treatment of large curves in adolescent idiopathic scoliosis. *Spine* 2000;25:2326–32.

Address reprint requests to

Charles Roland d'Amato, MD  
 University Orthopaedics, Inc.  
 2 Dudley Street, Suite 200  
 Providence, RI 02905  
 E-mail: Charles\_D'Amato@Brown.edu