

## Priapism

A 67-year old male with a past medical history of erectile dysfunction presents to the emergency department with a painful erection. The patient reports his erection started 5 hours prior to arrival, is constant, and has become increasingly painful. He denies weakness, fever, dysuria, or recent urinary incontinence. He denies any previous episodes of priapism. Earlier today the patient received an injection to treat erectile dysfunction. Patient is afebrile and vitals are within normal limits. On physical exam, patient appears in moderate distress with a fully erect penis which is exquisitely tender. The genital and perianal region show intact sensation and no signs of trauma. Which of the following is the most appropriate next step in the management of this patient's condition?

- A. Topical phenylephrine on the dorsal aspect of the penis**
- B. Inject phenylephrine 100mcg/mL into the corpus cavernosum**
- C. Aspirate corpus cavernosum bilaterally**
- D. Emergency surgical shunting**

The correct answer is C. In priapism with signs of ischemia or lasting longer than 4 hours, aspiration of the corpus cavernosum is recommended, usually to be followed by intracavernosal injection of a sympathomimetic drug (e.g., phenylephrine).

Priapism usually describes prolonged and painful erections of the penis. It also applies to the clitoris; however, this is far less common. Priapism is separated into ischemic and nonischemic priapism, with ischemic priapism being the more common form. Recurrent priapism may also occur and is associated with sickle cell disease. There are several underlying causes of priapism, however most cases are idiopathic. Incidence is 0.73/100,000 men per year. There is a bimodal distribution with incidence peaking between ages 5-10 years and 20-50 years.

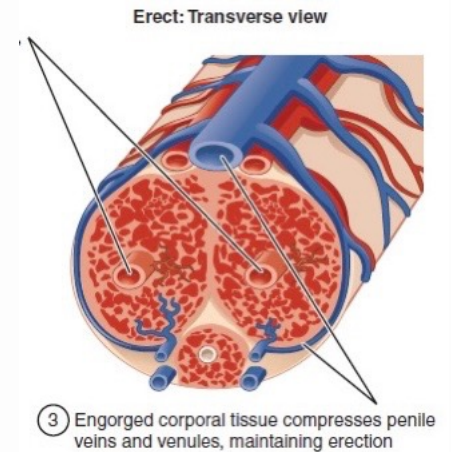


Figure 1. Showing compression of penile veins and venules during erection. Modified image, Creative Commons by 3.0 license, original <http://cnx.org/content/col11496/1.6/>

**Priapism is defined as a persistent erection of the penis or clitoris that is not associated with sexual stimulation or desire.**  
**(Deveci, 2022)**

## Discussion

Priapism results from interruption or dysregulation of the normal erection process. Normally, sexual arousal releases a series of neurotransmitters which lead to smooth muscle relaxation and dilation of arterioles in the corpus cavernosum as mediated by nitric oxide. As blood flow increases, intracorporal pressure increases leading to venous collapse, collection of blood, and engorgement of the penis. In ischemic priapism, impaired drainage of cavernous blood leads to a compartment syndrome which results in increasing hypoxia and acidosis in the cavernous tissue.

Common secondary causes of ischemic priapism include hematologic/thrombotic disorders (sickle cell disease), pharmacological agents, intracorporal injections (as seen in our patient), neurologic dysfunction, and malignancy. Nonischemic priapism usually occurs secondary to fistula formation between the cavernosal artery and corpus cavernosum, often in the setting of penile or perineal trauma.

Nonischemic priapism often does not represent a medical emergency, with most cases, up to 62%, resolving spontaneously. History and physical can often indicate the type of priapism, yet cavernosal blood gas analysis can provide a more definitive diagnosis.

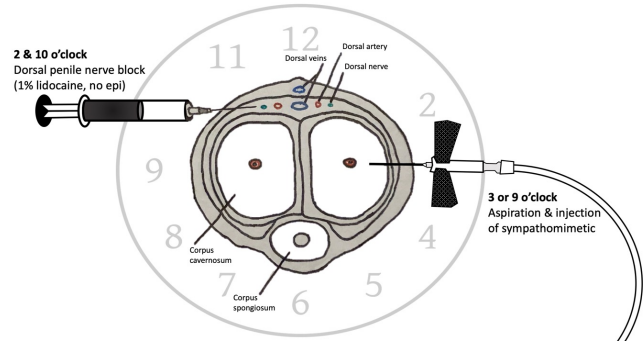


Figure 2. Locations of nerve block and aspiration.  
<https://canadiem.org/priapism-case-report-robert-de-niros-hard-situation-in-little-fockers/>

## Treatment

Ischemic priapism is a true medical emergency, and prompt identification and treatment are critical to minimizing long term sequelae, namely erectile dysfunction. Nonischemic priapism usually does not require urgent intervention and can be treated with observation and/or outpatient urologic intervention. In those cases where the type of priapism is unclear, cavernosal blood gas analysis and/or doppler ultrasonography should be utilized to guide treatment plans.

Timing is critical in the treatment of ischemic priapism. The American Urological Association has developed an algorithm to manage such cases. Prior to any injections or aspirations, adequate analgesia should be provided, including local nerve block at the dorsal base of the penis. If an erection has been present for less than 4 hours, intracavernosal injection with sympathomimetics is recommended as the first step. The drug of choice phenylephrine diluted with normal saline to a concentration of 100 to 500 mcg per ml. For patients with priapism lasting greater than 4 hours, aspiration of the corpus cavernosum, with or without irrigation, is performed prior to sympathomimetic injection. This is usually done using a 18-19 gauge needle at the 3 or 9 o'clock positions. Recurrence or failure of the priapism to resolve following these measures warrants immediate urology evaluation for possible shunt surgery.

## Prognosis

The prognosis of priapism varies based on the form of priapism, the underlying cause, the extent of ischemia present, the type of treatment required, and time of onset to treatment. The most common sequelae of priapism are impotence and erectile dysfunction. Penile prosthesis may be indicated in patients with unresolved erectile dysfunction following priapism. Additionally, urethral trauma may occur when treating priapism.

## Take Home Points

- **Priapism involves painful and persistent erections in the absence of sexual stimulation.**
- **Differentiating between ischemic and nonischemic priapism is critical to guiding treating. This can often be done clinically, but cavernous gas analysis and doppler ultrasonography can assist in confirming a diagnosis.**
- **Ischemic priapism is a true medical emergency. Early identification and treatment is critical for reducing complications, namely erectile dysfunction.**
- **Mainstay of treatment for ischemic priapism involves intracavernosal injection of sympathomimetics, with or without aspiration of the corpus cavernosum. Further management may involve urologic surgery such as shunting or penile prosthesis.**




### About the Author

This month's case was written by Daniel Orlan. Daniel is a 4<sup>th</sup> year medical student from FIU HWCOC. He did his emergency medicine rotation at BHMC in June 2022. Daniel plans on pursuing a career in Emergency Medicine after graduation and hopes to later work in healthcare policy.

### References

- 2021 AMI Online Salon. AMI Meeting 2021. (n.d.). Retrieved June 24, 2022, from <https://meetings.ami.org/2021/project/erection-and-detumescence/>
- Deveci, S. Priapism. In: *UpToDate*, Post TW (Ed), UpToDate, Waltham, MA. (Accessed on June 21, 2022.)
- Halls, J. E., Patel, D. V., Walkden, M., & Patel, U. (2012). Priapism: pathophysiology and the role of the radiologist. *The British journal of radiology*, 85 Spec No 1(Spec Iss 1), S79–S85. <https://doi.org/10.1259/bjr/62360925>
- Priapism. Priapism | France | PDF | PPT | Case Reports | Symptoms | Treatment. (n.d.). Retrieved June 24, 2022, from <https://www.omicsonline.org/france/priapism-peer-reviewed-pdf-ppt-articles/>



 @browardem