

Ehlers-Danlos syndrome – a historical review

Liakat A. Parapia and Carolyn Jackson

Department of Haematology, Bradford Teaching Hospitals NHS Foundation Trust, and University of Bradford, Bradford, UK

Summary

Ehlers-Danlos syndrome is an inherited heterogeneous group of connective tissue disorders, characterized by abnormal collagen synthesis, affecting skin, ligaments, joints, blood vessels and other organs. It is one of the oldest known causes of bruising and bleeding and was first described by Hippocrates in 400 BC. Edvard Ehlers, in 1901, recognized the condition as a distinct entity. In 1908, Henri-Alexandre Danlos suggested that skin extensibility and fragility were the cardinal features of the syndrome. In 1998, Beighton published the classification of Ehlers-Danlos syndrome according to the Villefranche nosology. From the 1960s the genetic make up was identified. Management of bleeding problems associated with Ehlers-Danlos has been slow to progress.

Keywords: Ehlers-Danlos, history, haemostasis, haemorrhage.

Ehlers-Danlos syndrome (EDS) is an inherited heterogeneous group of connective tissue disorders, displaying hyperextensibility of the skin, hypermobility of joints, tissue fragility demonstrated by easy bruising and delayed wound healing with atrophic scarring (Steinman *et al*, 2002). The syndrome is named after Edvard Ehlers, a Danish dermatologist, (1863–1937) and Henri-Alexandre Danlos a French dermatologist (1844–1912). In 1936 an English physician, Frederick Parkes-Weber, suggested that the disorder be named ‘Ehlers-Danlos syndrome’ (Enerson, 2004).

It was noted by Hippocrates in 400 BC in his writing ‘Airs, Waters and Places’, that Nomads and Scythians had lax joints and multiple scars. These were thought to have been caused by cauterization which had been applied in an attempt to stiffen up the joints (Littre, 1840).

It was not until 1657 that a Dutch surgeon, Job Janszoon van Meek’ren, observed a boy of Spanish origin who had extreme hyperextensibility of the skin. The boy, George Albes, was presented regularly at the Academy of Leyland, where he demonstrated the remarkable abnormality of his skin. He had the ability to stretch the skin of his chin, reaching his chest, or

covering his eyes, and the skin over his knees could be ‘pulled out to the length of half an ell’. However this phenomenon, unusually, was limited to the right side of his body (Beighton, 1970).

Paganini (1782–1840), the world famous ‘Virtuso in Excelsis’, performed unprecedented feats as a violinist; he had hypermobile joints, a slender physique, thoracic deformity and joint laxity, all features consistent with EDS (Mckusick, 1972).

The first comprehensive description of a syndrome displaying laxity and fragility of the skin associated with hypermobility of the large joints was published in 1892 when Dr Tschernogobow presented two patients at the Moscow Venereology and Dermatology Society (Tschernogobow, 1892). The first patient was a 17-year-old male with epilepsy who suffered from ‘fragility and hyperelasticity of the skin, and a failure to hold sutures. He also had hypermobility and luxation of joints, and molluscoid pseudo tumours of the knees, elbows, and other areas’, the combination of all the above features are suggestive of EDS (Tschernogobow, 1892). Jansen (1955) gave further credit to Tschernogobow for his first detailed clinical description.

During the late nineteenth century, some patients with EDS displayed their hyperextensibility as performers at travelling shows with titles such as ‘elastic lady’, described by Gould and Pyle (1897) or ‘The India Rubber Man’, as mentioned by Wile (1883).

In 1901, Edvard Lauritz Ehlers (1863–1937), a Danish dermatologist gave further recognition to the syndrome, when he published details of a patient with lax joints, hyperextensible skin and a tendency to bruising. The patient gave a history of delayed walking and frequent subluxations of the knees. This case was demonstrated at the Dermatological Society of Denmark in 1899 (Beighton, 1970).

A further case of EDS was identified by Henri-Alexandre Danlos, a French physician (1844–1912). In 1908, Danlos re-examined a patient who had previously been examined by Hallopeau and de Lepinay with a diagnosis of ‘juvenile pseudo-diabetic xanthoma’ (Beighton, 1970). The patient presented with lesions on the elbows and knees. However, Danlos disagreed with this diagnosis and Pautier (1908) a pathologist assisted Danlos with further investigations. He suggested the skin lesions were vascular and inflammatory due to trauma (Beighton, 1970).

Correspondence: Prof. L. Parapia, Director, Haemophilia Centre, Bradford Teaching Hospitals Foundation Trust, Bradford Royal Infirmary, Duckworth Lane, Bradford BD9 6RJ, UK.
E-mail: parapia@doctors.org.uk

Following these descriptions, isolated case reports of EDS appeared during the early part of the twentieth century (Beighton, 1970). Tobias (1934) reported the first case from the United States. Ronchese (1936) discovered 24 cases in a literature review and reported on three of his own. Mckusick (1956) compiled his monograph documenting less than 100 reports. By 1966, when his third edition was published the total number of reports had risen to 300. Weber (1936) reported six examples in England, the earliest was a boy presented at the old dermatological society in London in 1900 by Sir Malcolm Morris, although his diagnosis was not conclusive. Weber (1936) tried to delineate these conditions, highlighting skin hyperextensibility and fragility, together with joint laxity in his original patients, and the eponym Ehlers-Danlos syndrome was appropriated to this condition. Johnson and Falls (1949) concluded that EDS was probably inherited as an autosomal dominant trait, following a large kindred investigation of 32 patients. Jansen (1955), after reviewing all the published pedigrees, suggested that a genetic defect of collagen of the connective tissue probably accounted for the phenotype. Sestak (1962) supported this conclusion.

The first molecular defect was discovered by Pinnell *et al* (1972) with a finding of lysyl hydroxylase deficiency in an autosomal recessive form of Ehlers-Danlos syndrome. Patients were particularly prone to scoliosis and rupture of the ocular globe; Lichtenstein *et al* (1972) confirmed this was the first disorder of collagen.

Classification of EDS began in the late 1960s (Beighton, 1970; Mckusick, 1972) and, in 1988 an international nosology of connective tissue that defined nine subcategories of EDS was proposed (Beighton *et al*, 1998). With recent developments and increased medical expertise, a simplified classification of EDS has been revised into six major types according to the Villefranche nosology (Table I) (Beighton *et al*, 1998). Based on this refined classification, one in 5000 people is said to be affected by Ehlers-Danlos syndrome (Pyeritz, 2000). It affects

males and females equally of all racial backgrounds (Ceccolini & Schwartz, 2005).

The majority of patients have a bleeding diathesis, which is seen in all subtypes (Table I). The symptoms may be mild, consisting simply of a tendency to bruise easily, or they may be severe, with the occurrence of haematoma formation and bleeding from the nose, gut, lungs and urological tract (Beighton, 1970). Laboratory investigations of clotting factors, platelet aggregation and bleeding time are usually within normal limits in patients with connective tissue disorders (De Paepe & Malfait, 2004).

EDS type IV (vascular) has the worst prognosis because of its association with severe and often fatal rupture of the bowel, other organs, and large arteries (Pepin *et al*, 2000). EDS type IV can be a cause of cerebrovascular bleeding in young adults. The mean age of intracranial aneurismal rupture, spontaneous carotid-cavernous sinus fistula and cervical artery aneurysm is 28 years (North *et al*, 1995).




Fig 1. Lax skin of the abdomen. Written permission received from patient.

Table I. Revised classification of the Ehlers-Danlos syndrome based on the Villefranche nosology (Beighton *et al*, 1998).

Type	Mode of inheritance	Defect	Examples of clinical presentations
Classical (EDS I and II)	AD	Abnormal type V collagen	Skin laxity, scars (Fig 4), joint hypermobility, easy bruising, muscle hypotonia, hernias.
Hypermobility (EDS III)	AD	Unknown	Skin laxity (Fig 1), velvet skin, joint hypermobility, recurrent joint dislocations.
Vascular (EDS IV)	AD	Abnormal type III collagen	Arterial rupture, easy bruising (Fig 5), hypermobility of small joints, varicose veins.
Kyphoscoliosis (EDS VI)	AR	Deficiency of LH	Joint laxity, muscle hypotonia in infants, scoliosis from birth, sclera fragility.
Arthroclasia (part of EDS VII)	AD	Deficiency of chains in type I collagen	Joint hypermobility (Figs 2 and 3) and dislocations, skin laxity, easy bruising, muscle hypotonia, kyphoscoliosis.
Dermatosparaxis (was included in EDS VII)	AR	Deficiency of enzyme in type I collagen	Sagging redundant skin, soft, dough skin texture, easy bruising, hernias, premature rupture of fetal membranes.

AD, autosomal dominant; AR, autosomal recessive; LH, lysyl hydroxylase.

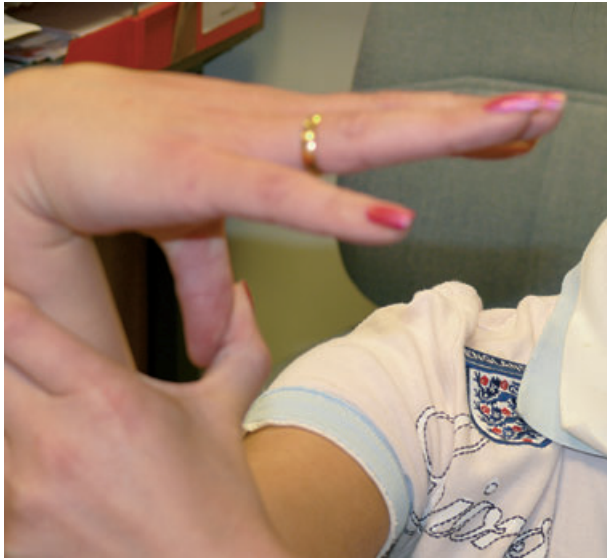

Fig 2. Joint hypermobility. Written permission received from patient.



Fig 3. Hyperextensibility of joints. Written permission received from patient.

Unlike other types of EDS, the skin is not hyperelastic, but rather thin and translucent, showing a visible pattern over the chest, abdomen and extremities (Beighton, 1993; Steinman *et al*, 2002).

Approximately 12% of neonates with vascular EDS are born with clubfoot and 3% have congenital dislocation of the hips (Germain, 2002; Pepin & Byers, 2005). Children may present with pneumothorax, inguinal hernia and recurrent joint

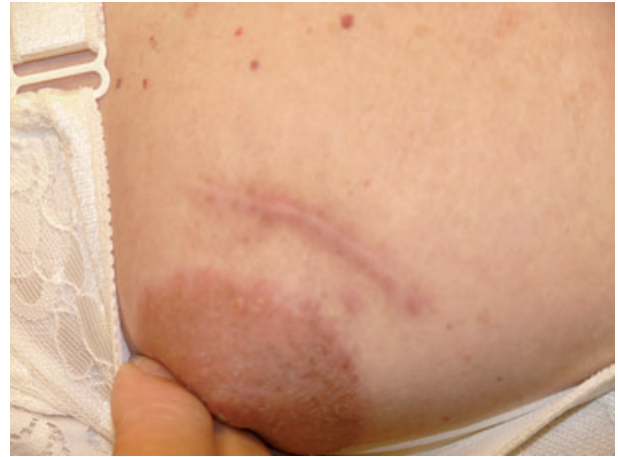

Fig 4. Abnormal scarring after surgery. Written permission received from patient.

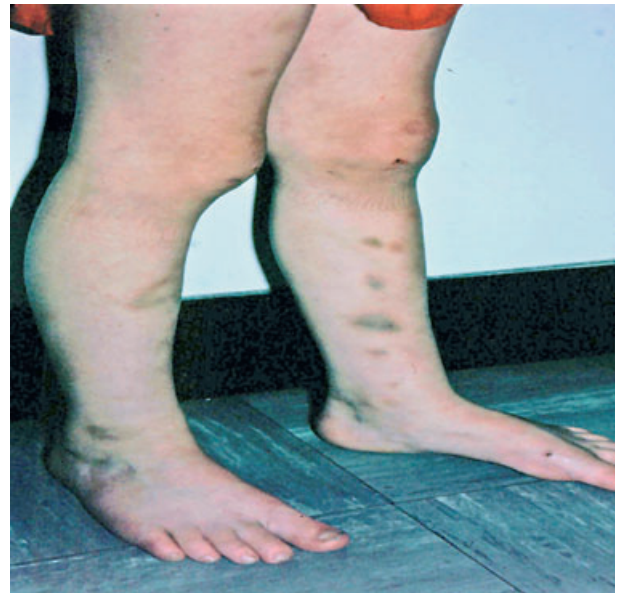

Fig 5. Spontaneous bruising of legs. Written permission received from patient.

dislocation. Excessive bruising in children can often be a presenting symptom to paediatricians, therefore it is imperative that a careful evaluation of the medical and family history and thorough physical examination is performed, paying attention to the skin features that are characteristic of EDS (De Paepe & Malfait, 2004). Facial features in infants with vascular-type EDS may initiate suspicion of the diagnosis, including prominent eyes (due to the lack of subcutaneous adipose tissue around the eyes), small lips, a pinched nose, hollow cheeks and lobeless ears (De Paepe & Malfait, 2004).

Vascular-type EDS can be identified by mutations in *COL3A1* (Jones, 1997; Beighton *et al*, 1998; Sybert, 2001). This particular gene provides instructions for making the

components of collagen. Molecular genetic testing to identify mutations in *COL3A1* is available to patients with biochemically confirmed diagnosis of vascular EDS (Dagleish, 1998).

Progress in the management of EDS has been slow as there is no specific treatment. Tranexamic acid postoperatively has been used to reduce episodes of bleeding (Bolton-Maggs *et al.*, 2004). There are reports of improvements in the bleeding time in patients treated with DDAVP (James *et al.*, 2001). For the vascular type of EDS, prophylactic measures are also of special importance, including the avoidance of contact sports or isometric exercises (Pepin & Byers, 2002). Refraining from drugs which interfere with platelet function is also advised. Management of EDS has been reviewed in the British Journal of Haematology (Bolton-Maggs *et al.*, 2004).

References

- Beighton, P. (1970) *The Ehlers-Danlos Syndrome*. William Heinemann Medical Books Ltd, pp. 1–194.
- Beighton, P. (1993) The Ehlers-Danlos syndrome. In: *Mckusick's Heritable Disorders of Connective Tissue* (ed. by P. Beighton), pp. 189–251. University of Cape Town Medical School, Cape Town, South Africa.
- Beighton, P., De Paepe, A., Steimann, B., Tsipouras, P. & Wenstrup, R.J. (1998) Ehlers-Danlos syndrome: revised nosology, Villfranche, 1997. Ehlers-Danlos National Foundation (USA) and Ehlers-Danlos Support Group (UK). *American Journal of Medical Genetics*, **77**, 31–37.
- Bolton-Maggs, P.H., Perry, D.J., Chalmers, E.A., Parapia, L.A., Wilde, J.T., Williams, M.D., Collins, P.W., Kitchen, S., Dolan, G. & Mumford, A.D. (2004) The rare coagulation disorders-review guidelines for management from the United Kingdom Haemophilia Centre Doctors Organisation. *Haemophilia*, **10**, 593.
- Ceccolini, E. & Schwartz, R. (2005) Ehlers-Danlos syndrome. (online article). Omaha, Neb: <http://www.eMedicine.com>. Updated 10 February 2005. Available at: <http://www.medicine.com/derm/topic696.htm> (Accessed 23 June 2005).
- Dagleish, R. (1998) The human collagen mutation database 1998. *Nucleic Acids Research*, **26**, 253–255.
- De Paepe, A. & Malfait, F. (2004) Bleeding and bruising in patients with Ehlers-Danlos syndrome and other collagen vascular disorders. *British Journal of Haematology*, **127**, 491–500.
- Enerson, O.D. (2004) Ehlers-Danlos syndrome. Oslo, Norway: who named it? (biographical dictionary of medical eponyms) Ehlers Danlos syndrome. Available at: <http://www.whonamedit.com/synd.cfm/2017.html> (Accessed 12 December 2004).
- Germain, D.P. (2002) Clinical and genetic features of vascular Ehlers-Danlos syndrome. *Annals of Vascular Surgery*, **16**, 391–397.
- Gould, G.M. & Pyle, W.L. (1897) *Anomalies and Curiosities of Medicine*. W.B. Saunders & Co., Philadelphia, PA, 217pp.
- James, R., Lee, D. & Parapia, L.A. (2001) The Therapeutic Potential of Desmopressin in Ehlers-Danlos Syndrome. *Blood Coagulation & Fibrinolysis*, **12**, A21.
- Jansen, L.H. (1955) Le mode de transmission de la maladie d'Ehlers-Danlos. *Journal de génétique humaine*, **4**, 204–218.
- Johnson, S.A.M. & Falls, H.F. (1949) Ehlers-Danlos syndrome. A clinical and genetic study. *Archives of Dermatology and Syphilology*, **60**, 82.
- Jones, K. (1997) *Smiths Recognisable Patterns of Human Malformation*. 5th edn. WB Saunders, Philadelphia, PA, pp. 482–485.
- Lichtenstein, J., Nigra, T.P., Sussman, M.D., Martin, G.R. & Mckusick, V.A. (1972) Molecular defect in a form of the Ehlers-Danlos syndrome: hydroxylysine deficient collagen (abstract). *American Journal of Human Genetics*, **24**(6 part 1), 27a.
- Littre, E. (1840) *Oeuvres Complete d' Hippocrate*. J.B. Bailliere, Paris. **Vol. 2**, p. 75.
- Mckusick, V.A. (1956) *Heritable Disorders of Connective Tissue*. 1st edn. C.V. Mosby, St Louis, MO, p. 167.
- Mckusick, V.A. (1972) *Heritable Disorders of Connective Tissue*. The C.V. Mosby Company, St Louis, MO.
- North, K.N., Whiteman, D.A., Pepin, M.G. & Byers, P.H. (1995) Cerebrovascular complications in Ehlers-Danlos syndrome type IV. *Annals of Neurology*, **38**, 960–964.
- Pautier, M. (1908) note histologique sur un cas de cutis elastica, avec pseudo-tumeurs aux genoux et aux coudes, presente par M. Danlos. *Bulletin de la Société française de dermatologie et de syphiligraphie*, **19**, 72.
- Pepin, M. & Byers, P. (2002) Ehlers-Danlos syndrome, Vascular type. <http://www.geneclinics.org/servlet/access?db=geneclinics&site=gt&id=8888891&key=krgt8V163hnxr>
- Pepin, M. & Byers, P. (2005) Ehlers-Danlos syndrome, vascular type (online) article. GeneReviews. Seattle, WA: <http://www.genetests.org>. Revised 25 January 2005. Available at: <http://www.genetests.org/servlet/access?db=geneclinics&site=gt&id=8888890&key=urbQYAIvOehP3&gry=&fcn-y&fw=sVjh&filename=/pofiles/eds4/index.html> (Accessed 3 February 2005).
- Pepin, M., Schwarze, U., Superti-Furga, A. & Byers, P.H. (2000) Clinical and genetic features of Ehlers-Danlos syndrome type IV, the vascular type. *New England Journal of Medicine*, **342**, 673–680.
- Pinnell, S.R., Krane, S.M., Kenzora, J.E. & Glimcher, M.J. (1972) A heritable disorder of connective tissue: hydroxylysine-deficient collagen disease. *New England Journal of Medicine*, **286**, 1013–1020.
- Pyeritz, R.E. (2000) Ehlers-Danlos syndrome. In: *Cecil Textbook of Medicine* 21st edn. (ed. by L. Goldman & J.C. Bennett), pp. 1119–1120. W.B. Saunders, Philadelphia, PA. **Vol 1**.
- Ronchese, F. (1936) Dermatorrhesis, with dermatochalasis and arthrochalasis (the so-called Ehlers-Danlos syndrome). *American Journal of Diseases of Children*, **51**, 1403.
- Sestak, Z. (1962) Ehlers-Danlos syndrome and Cutis laxa: an account of families in the Oxford area. *Annals of Human Genetics*, **25**, 313–321.
- Steinman, B., Royce, P. & Superti-Furga, A. (2002) The Ehlers-Danlos syndrome. In: *Connective Tissue and its Heritable Disorders* (ed. by P. Royce & B. Steinman), pp. 431–523. Wiley-Liss, Inc., New York.
- Sybert, V. (2001) Selected hereditary diseases. In: *Textbook of Neonatal Dermatology* (ed. by L. Eichenfield, I. Freiden & N. Esterly), pp. 458–459. WB Saunders, Philadelphia, PA.
- Tobias, N. (1934) Danlos syndrome associated with congenital lipomatosis. *Archives of Dermatology and Syphilology (Paris)*, **30**, 540.
- Tschernogobow, A. (1892) Cutis Laxa (Presentation at first meeting of Moscow). *Dermatologic and Venereology Society*, Nov 13 (1891). *Monatshefte für Praktische Dermatologie*, **14**, 76.
- Weber, F.P. (1936) The Ehlers-Danlos syndrome. *British Journal of Dermatology and Syphilis*, **48**, 609.
- Wile, H. (1883) The Elastic Skin Man. *Medical News (NY)*, **43**, 705.