



60th Anniversary World Congress—ICA 2018
International College of Angiology
In conjunction with
13th Japan Endovascular Symposium
“The Beginning and Challenges of ICA Post John B. Chang, MD Era”



August 20-21, 2018

**Jikei University School of Medicine
Tokyo, Japan**

Program Chairman

**Prof. Kailash Prasad, MBBS (Hons), MD, PhD, DSc, FRCPC, FACC,
FIACS, FICA**

Chairman, Local Organizing Committee

Prof. Takao Ohki, MD, PhD, FICA

Chairman, Scientific Committee

Prof. Otmar M. Pachinger, MD, FESC, FAHA, FICA

Scientific Program

International Journal of Angiology

ISSN 1061-1711

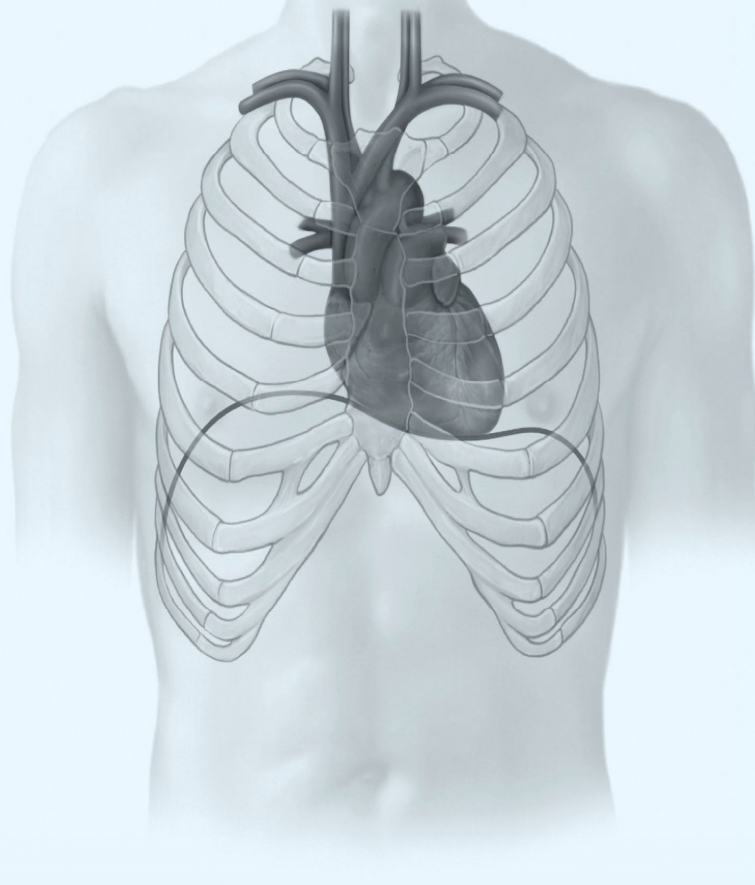
Editor-in-Chief
John A. Elefteriades, MD, FICA

Number 2 • Volume 27 • Pages 57–120

Official Journal of the
International College of
Angiology

An Official Journal of the
International College of
Surgeons

An Official Journal of the
Asian Society for Vascular
Surgery



60th Anniversary World Congress - ICA 2018
International College of Angiology
in conjunction with
13th Japan Endovascular Symposium

Jikei University School of Medicine
Tokyo, Japan - August 20-21, 2018

Board of Directors

Kailash Prasad, MBBS (Hons), MD, PhD, DSc, *Chairman*
Randall W. Franz, MD, RVT, *First Vice Chairman*
John A. Elefteriades, MD, *Second Vice Chairman*

Pertti T. Aarnio, MD, PhD
Elie D. Aboulaflia, MD
John D. Corson, MB, ChB
Iwan Dakota, MD, PhD
Victor A. Ferraris, MD, PhD
Ernesto P. Molmenti, MD, PhD, MBA
Takao Ohki, MD, PhD
Otmar M. Pachinger, MD
Sibu P. Saha, MD, MBA
Rajinder P. Sharma, MD
Josef Veselka, MD, PhD
Wei Zhou, MD

Officers of the Scientific Council

Ernesto P. Molmenti, MD, PhD, MBA, *President*
Josef Veselka, MD, PhD, *President-Elect*
Iwan Dakota, MD, PhD, *Secretary General*
Wei Zhou, MD, *Treasurer*

Vice Presidents

Andriea P. Andreev, MD
Sofia, Bulgaria
Nobuyoshi Azuma, MD, PhD
Asahikawa, Japan
Semih I. Barlas, MD
Istanbul, Turkey
Jürgen Falkensammer, MD
Vienna, Austria
Glenn R. Faust, MD
East Meadow, New York
L. Michael Graver, MD
New Hyde Park, New York

Petr Hájek, MD, PhD
Prague, Czech Republic
K.V. Krishnasastry, MD
Lake Success, New York
Choi-Keung Ng, MD
Innsbruck, Austria
Ramdas P. Pai, MD
Los Angeles, California
Anwar Santoso, MD, PhD
Jakarta, Indonesia
Thomas F. Whayne, Jr., MD, PhD
Lexington, Kentucky

Honorary Fellows

Eugene Braunwald, MD
Alain F. Carpentier, MD
Csaba Dzsiniich, MD
Michael Grimm, MD
Larry H. Hollier, MD
Pekka-T. Harjola, MD

Francis Robicsek, MD, PhD
Wilhelm Sandmann, MD
Michael B. Silva, Jr., MD
Frank J. Vieth, MD
Stephen Westaby, BSc, PhD, MS

Past Presidents

Algy de Medeiros, MD (1965-1966)
A. Michael Boyd, FRCS (1966-1967)
Ernesto Castro-Farinas, MD (1967-1968)
Angelo M. May, MD (1972-1975)
Albert Senn, MD (1976-1978)
Fritz Kaindl, MD (1979-1981)
Robert Raskind, MD (1984-1985)
Earl R. Olsen, MD (1986-1989)
Hans J. Hachen, MD (1989-1990)
John B. Chang, MD (1991-1995)
Kailash Prasad, MD, PhD (1995-1997)

Tatsuki Katsumura, MD, PhD (1997-1999)
Pertti T. Aarnio, MD, PhD (1999-2001)
Jose Alemany, MD (2001-2003)
Elie D. Aboulaflia, MD (2003-2005)
John A. Elefteriades, MD (2005-2007)
John D. Corson, MB, ChB (2007-2009)
Sibu P. Saha, MD, MBA (2009-2011)
Takao Ohki, MD, PhD (2011-2013)
Otmar M. Pachinger, MD (2013-2015)
Rajinder P. Sharma, MD (2015-2017)

Executive Director

Denise M. Rossignol, BS

International College of Angiology Scientific Committee

Responsible for review and selection of all scientific papers pro-offered for the Annual World Congress within budgetary and space limitations, responsible for the organization of special symposia and workshops.

Otmar M. Pachinger, M.D., Chairman
Innsbruck, Austria

Scientific Committee Co-Chairpersons

Pertti T. Aarnio, M.D., Ph.D.

Kauniainen, Finland

Iwan Dakota, M.D., Ph.D.

Jakarta, Indonesia

John A. Elefteriades, M.D.

New Haven, Connecticut

Glenn R. Faust, M.D.

East Meadow, New York

Randall W. Franz, M.D.

Columbus, Ohio

L. Michael Graver, M.D.

New Hyde Park, New York

Ernesto P. Molmenti, M.D., Ph.D., MBA

Manhasset, New York

Takao Ohki, M.D., Ph.D.

Tokyo, Japan

Sibu P. Saha, M.D., MBA

Lexington, Kentucky

Rajinder P. Sharma, M.D.

West Bloomfield, Michigan

Josef Veselka, M.D., Ph.D.

Prague, Czech Republic

Wei Zhou, M.D.

Tucson, Arizona

Young Investigator Award Recipients

Robert N.A. Gasser, M.D., Ph.D. (1988)

David Wilkinson, M.B., Ch.B. (1988)

Simon Ashley, B.M., FRCS (1989)

G. Galloni, M.D. (1989)

Tony Katras, M.D. (1989)

Dimitrios N. Psathakis, M.D. (1989)

Joseph F. Polak, M.D. (1989)

Daniel Duprez, M.D., Ph.D. (1991)

Philippe Bull, M.D. (1992)

Patricia Cristodor, M.D. (1992)

Manfred Grisold, M.D. (1992)

Bruno Papaleo, M.D. (1992)

F.C. Rada, M.D. (1992)

Patricia Amado, M.D. (1993)

Jutta Berglöff, M.D. (1993)

Claudia Dimofte, M.D. (1993)

Antti Korpela, M.D. (1993)

R.S. More, MRCP (1993)

Antero Sahlman, M.D. (1993)

I. Schafhalter, M.D. (1993)

Nilanjana Maulik, Ph.D. (1994)

J. Melichercik, M.D. (1994)

Robert W. Chang, B.S. (1995)

T. Ikonen, M.D. (1995)

A.R.J. Rajakumar, M.B.B.S. (1995)

Satoshi Sakai, M.D. (1996)

Bernd Wolfgarten, M.D. (1996)

Gernold Wozniak, M.D. (1996)

Jalal Zamani, M.D. (1996)

Sabine Horn, M.D. (1997)

Roberto Baglini, M.D. (1997)

Maziar Rahmani, M.D. (1997)

Sailaritta Vuorisalo, M.D., Ph.D. (1998)

Atsushi Ishida, M.D., Ph.D. (1999)

Dai Wangde, M.D. (1999)

Wolf Drescher, M.D. (2000)

Takashi Yamaki, M.D. (2000)

Mitsuhiro Yamamura, M.D. (2000)

Paul Lee, Ph.D. (2001)

Thomas Zeller, M.D. (2001)

Shoiji Fukuda, M.D., Ph.D. (2002)

Rossella DiStefano, M.D. (2003)

Randy A. Stevens, M.D. (2004)

Nadia Cosentino, M.D. (2005)

Erick McNair, M.Sc. (2005)

Manika Das, Ph.D. (2006)

Suresh Varma Penumathsa (2006)

Mahesh Thirunavukkarasu (2006)

Joseph F. Ndisang, PharmD, PhD (2007)

Ramesh Vidavalur, M.D. (2007)

Aruna Poduri, Ph.D. (2010)

John Samas, M.D. (2010)

Xuan Zhang, B.S. (2010)

Jang Yong Kim, M.D. (2011)

Ivy Cheng, B.S. (2013)

Gautham Chitrigari, M.B.B.S. (2013)

Brandon Sumpio (2013)

Sisca Natalia Siagian, M.D. (2015)

Jakub Honek, M.D. (2016)

Pavol Tomasov, M.D. (2016)

Denisa Jahnlova, M.D. (2016)

Christopher F. Tanga, D.O. (2017)

Cyril Štěchovský, M.D. (2017)

Professor John B. Chang Research Achievement Award Recipients

Kailash Prasad, M.D., Ph.D. (1995)

Zhong Gao Wang, M.D. (1996)

Vikrom S. Sottirai, M.D., Ph.D. (1997)

Pertti T. Aarnio, M.D., Ph.D. (1998)

Kensuke Esato, M.D. (1999)

Bauer E. Sumpio, M.D. (2000)

Jose Alemany, M.D. (2001)

Hendrick B. Barner, M.D. (2002)

Tatsuki Katsumura, M.D., Ph.D. (2003)

John A. Elefteriades, M.D. (2004)

Francis Robicsek, M.D. (2005)

John D. Corson, M.B., Ch.B. (2006)

Sibu P. Saha, M.D., MBA (2009)

Victor A. Ferraris, M.D., Ph.D. (2010)

J. Ernesto Molina, M.D., Ph.D. (2011)

Otmar M. Pachinger, M.D., Ph.D. (2012)

Elie D. Aboulafia, M.D. (2013)

Edward Ross, M.D. (2014)

Josef Veselka, M.D., Ph.D. (2016)

Thomas F. Whayne, Jr., M.D., Ph.D. (2017)

Takao Ohki, M.D., Ph.D. (2018)

ICA Lifetime Achievement Award

Kailash Prasad, MBBS (Hons), M.D., Ph.D., D.Sc. (2015)

John B. Chang, M.D. (Posthumously 2016)

International Journal of Angiology

*Official Journal of the International College of Angiology
An Official Publication of the International College of Surgeons
An Official Publication of the Asian Society for Vascular Surgery*

Editor-in-Chief

John A. Elefteriades, *Connecticut*

Consulting Editor

Kailash Prasad, *Canada*

Editorial Advisory Board

Braunwald, *Massachusetts*

Peter P. Liu, *Canada*

Michael F. O'Rourke, *Australia*

Stephen Westaby, *United Kingdom*

Senior Editors

Pertti T. Aarnio, *Finland*

John D. Corson, *New Mexico*

Victor A. Ferraris, *Kentucky*

Larry H. Hollier, *Louisiana*

Frank Manetta, *New York*

Otmar M. Pachinger, *Austria*

Pravin M. Shah, *California*

Bauer E. Sumpio, *Connecticut*

Editorial Board

Elie D. Aboulafia, *Michigan*

Andreia P. Andreev, *Bulgaria*

Nobuyoshi Azuma, *Japan*

Semih I. Barlas, *Turkey*

Jeffrey S. Borer, *New York*

Eric Choi, *Pennsylvania*

Anthony J. Comerota, *Ohio*

Iwan Dakota, *Indonesia*

Gert J. DeBorst, *The Netherlands*

Alik Farber, *Massachusetts*

Glenn R. Faust, *New York*

Randall W. Franz, *Ohio*

Gary Giangola, *New York*

L. Michael Graver, *New York*

Michael H. Hall, *New York*

Naoki Haruta, *Japan*

Hans M. Hoffmeister, *Germany*

Thomas Jahnke, *Germany*

Robert Kalimi, *New York*

Michael C. Kim, *New York*

Mark Kissin, *New York*

K.V. Krishnasastri, *New York*

Sean Kwon, *New York*

Gregg Landis, *New York*

Byung-Boong Lee, *Virginia*

J. Ernesto Molina, *Minnesota*

Ernesto P. Molmenti, *New York*

Debabrata Mukherjee, *Texas*

Stefan Müller-Hülsbeck, *Germany*

H. Müller-Wiefel, *Germany*

Aravinda Nanjundappa, *West Virginia*

Takao Ohki, *Japan*

Alexander N. Orekhov, *Russia*

Ramdas G. Pai, *California*

Thomas Panetta, *New York*

Jeffrey Prem, *Ohio*

Dinker B. Rai, *New York*

Chand Ramaiah, *Tennessee*

Sibu P. Saha, *Kentucky*

Anwar Santoso, *Indonesia*

Darren B. Schneider, *New York*

Richard W. Schutzer, *New York*

Nicolas W. Shammis, *Iowa*

Rajinder P. Sharma, *Michigan*

Hiroshi Shigematsu, *Japan*

Ahmed S. Shoker, *Canada*

Tahir Tak, *Minnesota*

Eiji Tamiya, *Japan*

Sanjay Tyagi, *India*

Josef Veselka, *Czech Republic*

Malka Yahalom, *Israel*

Mitsuhiro Yamamura, *Japan*

Wei Zhou, *Arizona*

External Reviewers

Paul Ganguly, *Saudi Arabia*

Editors Emeritus

Hendrick B. Barner, *Missouri*

K. Buyukozturk, *Turkey*

Raymond A. Dieter, Jr., *Illinois*

Hans O. Myhre, *Norway*

Francis Robicsek, *North Carolina*

Managing Editor

Denise M. Rossignol, BS, *Vermont*



International College of Angiology 60th Anniversary World Congress Organizing Committee

Program Chairman

Kailash Prasad, MBBS (Hons), MD, PhD, DSc, FRCPC, FACC, FIACS, FICA

Professor Emeritus of Physiology, College of Medicine, University of Saskatchewan, Saskatoon, Canada
Chairman, Board of Directors, International College of Angiology
Consulting Editor, *International Journal of Angiology*
Department of Physiology
College of Medicine, University of Saskatchewan
Saskatoon, Saskatchewan, Canada

Chairman, Scientific Committee

Otmar M. Pachinger, MD, FESC, FAHA, FICA

Professor Emeritus, Distinguished Professor of Cardiology, Medical University of Innsbruck, Innsbruck, Austria; Member, Board of Directors, International College of Angiology; Chairperson, Scientific Committee, International College of Angiology; Senior Editor, *International Journal of Angiology*; President, Austrian Heart Foundation, Innsbruck, Austria.

Executive Director

Denise M. Rossignol, BS

Executive Director and CME Program Administrator, International College of Angiology; Managing Editor, *International Journal of Angiology*, Jay, Vermont.

Chairman, Local Organizing Committee

Takao Ohki, MD, PhD, FICA

Professor of Surgery; Member, Board of Directors, International College of Angiology; Editor, *International Journal of Angiology*; Chairman, Department of Surgery and Professor and Chief, Division of Vascular Surgery, Jikei University School of Medicine, Tokyo, Japan.

Co-Chairperson, Local Organizing Committee

Koji Maeda, MD, PhD

Department of Surgery, Division of Vascular Surgery, Jikei University School of Medicine, Tokyo, Japan.

Congress Secretariat

Noriko Fujii

N-Practice Co., Ltd., Osaka, Japan.

SCIENTIFIC PROGRAM-AT-GLANCE

MONDAY, 20 AUGUST 2018		TUESDAY, 21 AUGUST 2018	
09.00 09.10	OPENING CEREMONY—INTRODUCTIONS <i>Lecture Hall 1, 3rd Floor</i> <i>Master of Ceremonies</i> Takao Ohki, Japan	08.30 09.20	COOK VASCULAR SYMPOSIUM—EVAR & SFA TREATMENTS <i>(Co-Sponsored by Cook Japan)</i> <i>Lecture Hall 1, 3rd Floor</i>
	WELCOME ADDRESS Fujio Mitarai, Chairman & CEO, Canon, Inc.		Chairperson: Shigeo Ichihashi, Japan Sciencing Zenith—Why we Should be Using Zenith Stent Grafts Naoki Fujimura, Japan Is It Possible? “Leave Nothing Behind Concept” for SFA Treatment Tatsuya Nakama, Japan
09.10 09.30	PRESIDENTIAL ADDRESS <i>Lecture Hall 1, 3rd Floor</i> Chairperson: Kailash Prasad, Canada Takao Ohki, Japan	09.20 09.50	ORATION LECTURES <i>Lecture Hall 1, 3rd Floor</i> Chairpersons: Nobuyoshi Azuma, Japan Takao Ohki, Japan
09.30 10.15	The Endovascular Revolution at Jikei and in Japan Takao Ohki, Japan	09.20 09.35	Thoracic Aortic Aneurysms: Practical Genetics for the Surgeon—Prof. Kailash Prasad Oration Lecture John A. Elefteriades, USA
09.30 09.45	MEMORIAL LECTURES <i>Lecture Hall 1, 3rd Floor</i> Chairpersons: Takao Ohki, Japan Kailash Prasad, Canada	09.35 09.50	Scrutinizing the General Applicability of the CE Approved Chimney Procedure for Short Neck and Juxtarenal Aortic Pathologies—109 Fenestrated Endovascular Aneurysm Repair Cases Revisited—Prof. Otmar M. Pachinger Oration Lecture Jürgen Falkensammer, Austria
09.45 10.00	Setting a New Direction in the Development of Disease: AGE-RAGE Stress—Prof. John B. Chang Memorial Lecture Kailash Prasad, Canada	09.50 10.20	HOT TOPICS IN ANGIOLOGY 2 <i>Lecture Hall 1, 3rd Floor</i> Chairpersons: Hideyuki Shimizu, Japan Josef Veselka, Czech Republic
10.00 10.15	Spontaneous Coronary Artery Dissection (SCAD)—Current State of Diagnosis and Management—Prof. Albert Senn Memorial Lecture Otmar M. Pachinger, Austria	09.50 10.05	In-Hospital Based Outcomes of STEMI after Application of a Regional STEMI Network in the Metropolitan Area of a Developing Country Iwan Dakota, Indonesia
10.15 11.00	Composition of Carotid Stenosis and Restenosis—Prof. Hans J. Hachen Memorial Lecture Josef Veselka, Czech Republic	10.05 10.20	Emerging Models of Cardiothoracic Surgical Training: Challenges and Opportunities Sibu Saha, USA
10.15 11.00	HOT TOPICS IN ANGIOLOGY 1 <i>Lecture Hall 1, 3rd Floor</i> Chairpersons: Hiroshi Shigematsu, Japan Wei Zhou, USA	10.20 10.30	BREAK <i>Exhibition Hall 7F</i>
10.15 10.30	Key Messages of the EVS Mesenteric Ischemia Guidelines Martin Björck, Sweden	10.30 11.30	ORAL SESSION 3 CORONARY VEINS, ETC. <i>Lecture Hall 1, 3rd Floor</i>
10.30 10.45	Overview of the 59th Annual Meeting of the Japanese College of Angiology in Hiroshima Masao Yoshizumi, Japan		Chairpersons: Hiroyuki Ishibashi, Japan Otmar M. Pachinger, Austria Commentators: Kuniomi Ooi, Takahiro Ohmine, Akira Miyamoto, Takumi Yasugi, Japan
10.45 11.00	The Development Status and Trend of JSVS Tetsuro Miyata, Japan	10.30 10.40	Results of Open and Endovascular Surgery for the Treatment of Renal Artery Aneurysms Yuri Murakami, Japan
11.00 11.15	BREAK <i>Exhibition Hall 7F</i>	10.40 10.50	The Interplay of AGE-RAGE Axis in Coronary Stent Restenosis: A Prospective Study Erick McNair, Canada
11.15 11.55	ORAL SESSION 1 CRITICAL LIMB ISCHEMIA <i>Lecture Hall 1, 3rd Floor</i> Chairpersons: Katsuyuki Hoshina, Japan Randall W. Franz, USA Commentators: Toshifumi Kudo, Hiroshi Banno, Wataru Higashiura, Koji Maeda, Japan	10.50 11.00	Internal Jugular Venous Flow in Cerebral Small Vessel Disease: A Study on White Matter Hyper-intensities and Cognitive Dysfunction Zulfa Indah K. Fadhly, Indonesia
11.15 11.25	New Evaluation Method for Critical Lower Limb Ischemia using Laser Blood-Flowmeter BFD Clinical Lab Sotaro Katsui, Japan	11.00 11.10	Rivaroxaban for Managing Recurrent Venous Thromboembolism in Venous Filter Thrombosis and Malignancy Yeo Zhi Ta Alan, Singapore
11.25 11.35	Undesirable Vascular Response during Peripheral Angioplasty in Systemic Lupus Erythematosus Vito Anggarino Damay, Indonesia	11.10 11.20	Novel Oral Anticoagulants for Managing Recurrent Venous Thromboembolism in Malignancy—A Case Series: Benedict Cesar I. Azucena, Singapore
11.35 11.45	Current Management of Chronic Mesenteric Ischemia David Epstein, USA		

SCIENTIFIC PROGRAM-AT-A-GLANCE

11.45 11.55	Malondialdehyde Induces a Pro-Inflammatory Activation of T-Cells from Human Atherosclerotic Plaque through both a Dependent and Independent Mechanism Mizanur Rahman, Sweden	11.20 11.30	Status of Cardiovascular Medicine Associated with Commercial and Recreational Underwater Diving Thomas F. Wayne, Jr., USA
11.55 12.35	ORAL SESSION 2 ENDOVASCULAR TREATMENT <i>Lecture Hall 1, 3rd Floor</i> <i>Chairpersons:</i> Yuji Kanaoka, Japan Silbu P. Saha, USA <i>Commentators:</i> Masanori Inoue, Kunihiro Shigematsu, Nobuya Zempo, Takashi Murakami, Japan	11.30 11.40	Aortic Wall Enhancement —Possibility of a New Prognostic Indicator Eisaku Ito, Japan
11.55 12.05	Restoration of Vision by Endovascular Reperfusion in Takayasu's Arteritis —Case Series Sanjay Tyagi, India	11.40 11.50	BREAK <i>Exhibition Hall 7F</i>
12.05 12.15	Open Surgery versus Hybrid Endovascular Treatment for Complete Revascularization in Infrarenal Aortoiliac Occlusive Disease Won-Min Jo, South Korea	11.50 12.40	LUNCHEON SEMINAR 2 <i>(Co-Sponsored by Sumitomo Bakelite Co., LTD)</i>
12.15 12.25	Endovascular Intervention after Infected Open Revascularization Richard Schutzer, USA		<i>Chairperson:</i> Takao Ohki, Japan
12.25 12.35	Early and Mid-Term Outcomes of Primary Carotid Endarterectomy Robert Hacker, USA		Reo Takizawa, Japan Sung Gwon Kang, Japan
12.35 12.45	BREAK <i>Exhibition Hall 7F</i>	12.40 12.50	BREAK <i>Exhibition Hall 7F</i>
12.45 13.35	LUNCHEON SEMINAR 1 <i>(Co-Sponsored by W.L. Gore & Associates Co. LTD)</i> <i>Chairperson:</i> Takao Ohki, Japan Masayuki Hara, Japan <i>Commentators:</i> Martin Björck, MD, PhD, Sweden	12.50 14.20	SYMPOSIUM 3 <i>Lecture Hall 1, 3rd Floor</i> <i>Chairpersons:</i> Ikuo Fukuda, Japan Jürgen Falkensammer, Austria <i>Commentators:</i> Yukio Obitsu, Tomoyasu Sato, Naoki Hayashida, Kinya Matsui, Japan
	The Value of Excluder IBE —Preservation of IIA and Prevention of Type Ib Endoleak	12.50 13.05	Four Reasons we should Intervene Earlier with Ascending Aortic Aneurysms John A. Elefteriades, USA
	The Price of Sacrificing the Internal Iliac Artery Blood Flow —What Have we Learned from Clinical Experiences and Who Do the Clinical Practice Guidelines Recommend?	13.05 13.20	Effect of Stroke Prevention Techniques in Hybrid Aortic Arch Repair Masaaki Kato, Japan
13.35 13.40	BREAK <i>Exhibition Hall 7F</i>	13.20 13.35	Proximal Bare Stent May Reduce Bird-Beak Configuration which is Associated with Distal Migration of Stent Grafts in the Aortic Arch Hiroshi Banno, Japan
13.40 14.40	SYMPOSIUM 1 ABDOMINAL AORTIC ANEURYSMS <i>Lecture Hall 1, 3rd Floor</i> <i>Chairpersons:</i> Makoto Sumi, Japan John A. Elefteriades, USA <i>Commentators:</i> Noritake Akaba, Takahiro Ohmine, Wataru Higashiura, Japan	13.35 13.50	Surgical Intervention after TEVAR: Strategy and Outcome — Tokyo Medical University-Cardiovascular Surgery Hitoshi Ogino, Japan
13.40 13.55	Endoleak Management after EVAR Shigeo Ichinashi, Japan	13.50 14.05	Double Barrel Stent Graft to Shorten Aortic Coverage in Endovascular Treatment of Thoracoabdominal Aneurysm (TAAA) Piotr M. Kasprzak, Austria
13.55 14.10	Early Sac Shrinkage is a Good Surrogate Marker of Durable Success after Endovascular Aneurysm Repair in Japanese Patients Naoki Fujimura, Japan	14.05 14.20	Segmental Artery Coil Embolization prior to Extensive Thoracic and Thoracoabdominal Endovascular Aortic Repair Takashi Murakami, Japan
14.10 14.25	A Multicenter Experience with Abdominal Aortic Endograft Infections in Japan Hideaki Obara, Japan	14.20 15.10	TEATIME SEMINAR 2 <i>(Co-Sponsored by Japan Lifeline Co., LTD)</i>
14.25 14.40	EVAR for Ruptured Abdominal Aortic Aneurysms Hidemitsu Ogino, Japan		<i>Chairperson:</i> Hideaki Obara, Japan <i>Utilities of AFX2 Stent Graft System</i> Hiroshi Banno, Japan <i>In-Vitro Evaluation of a Suitable Proximal Neck Length for Snorkel EVAR with AFX Infra-Renal Cuff:</i> Kenjiro Kaneko, Japan
14.40 15.30	TEATIME SEMINAR 1 LATEST INFORMATION ON IMAGE GUIDED SYSTEMS <i>(Co-Sponsored by Canon Medical Systems Corporation)</i>	15.10 15.25	BREAK <i>Exhibition Hall 7F</i>
		15.25 16.10	SYMPOSIUM 4 CRITICAL LIMB ISCHEMIA <i>Lecture Hall 1, 3rd Floor</i> <i>Chairpersons:</i> Kimihiko Komori, Japan Jackie P. Ho, Singapore <i>Commentators:</i> Shin Ishimaru, Yoshinori Inoue, Hiroyoshi Komai, Yoichi Nozaki, Japan

SCIENTIFIC PROGRAM-AT-A-GLANCE

	Chairperson: Takao Ohki, Japan		Treatment Strategy for Critical Limb Ischemia—How to Select Open Surgery or Endovascular Treatment Nobuyoshi Azuma, Japan	15.25 15.40	
	Naoki Fujimura, Japan Kanako K. Kumamaru, Japan		Autogenous Stem Cells for Critical Limb Ischemia—Technique and Results Randall W. Franz, USA	15.40 15.55	
15.30 15.45	BREAK Exhibition Hall 7F		Optimal Endpoint of Below the Knee (BTK) Intervention for Wound Healing Makoto Utsunomiya, Japan	15.55 16.10	
15.45 17.15	SYMPOSIUM 2 CAROTID AND PERIPHERAL ARTERIAL DISEASE Lecture Hall 1, 3 rd Floor		PROF. JOHN B. CHANG RESEARCH ACHIEVEMENT AWARD LECTURE Lecture Hall 1, 3 rd Floor	16.10 16.40	
	Chairpersons: Hideaki Obara, Japan Kailash Prasad, Canada Commentators: Taku Kokubo, Naoki Fujimura, Atsubumi Murakami, Japan		Chairperson: Otmar M. Pachinger, Austria The Road to Conquer Arch Aneurysm Takao Ohki, Japan		
15.45 16.00	Zilver Post-Market Surveillance Study of Paclitaxel Eluting Stents for Treating Femoropopliteal Artery Disease in Japan: 5-Years Results Hiroyoshi Yokoi, Japan		CLOSING CEREMONY Lecture Hall 1, 3 rd Floor	16.40 16.50	
16.00 16.15	Beyond Stroke—What Have We Learned about Carotid Disease Wei Zhou, USA				
16.15 16.30	Pathogenesis in Clinical Significance of Buerger's Disease and PAD Takehisa Iwai, Japan				
16.30 16.45	Variation in Atherosclerotic Plaque Feature in Swine Artery Induced with Partial Ligation, Denudation and External Irrigation Jackie P. Ho, Singapore				
16.45 17.00	Treatment of Peripheral Vascular Disease via Percutaneous Brachial Artery Access Randall W. Franz, USA				
17.00 17.15	Endovascular Approaches for Complex BTK Chronic Total Occlusion (CTO) Lesion Hiroshi Ando, Japan				
17.15 18.15	e-POSTER PRESENTATIONS Lecture Hall 1, 3 rd Floor				
	Chairpersons: Makoto Mo, Japan Thomas F. Whayne, Jr., USA				
	Commentators: Katsuhiko Oka, Seiji Onitsuka, Masayuki Hirokawa, Hideaki Maeda, Japan				
17.15 17.22	Treatment of Deep Vein Thrombosis in May-Thurner Syndrome with Non-Vitamin K Oral Anticoagulants: A Case Report Toh Ching Han, Singapore	17.15 18.15		ICA BUSINESS MEETING Board of Directors Jikei Bldg. 2	
17.22 17.29	Anticoagulation for Antiphospholipid Syndrome in a Patient with Severe Thrombocytopenia: Case Report Prathika Parmalingam, Singapore				
17.29 17.36	Bilateral Unproved Deep Vein Thrombosis in an Elderly Gentleman with Hyperhomocysteinemia Joey Ying Hao Wong, Singapore				
17.36 17.43	The Association of High Blood Homocysteine and the Risk of Increased Severity of Ischemic Stroke Events Salim Harris, Indonesia				
17.43 17.50	Comparison between Sensitivity and Specificity of Ankle Brachial Index and Carotid Intima-Media Thickness for Detecting Significant Coronary Artery Disease Novi Anggriyani, Indonesia				
17.50 17.57	EVAR—First Strategy for Ruptured Aortic Aneurysm: A Clinical Analysis of 20 Cases Daiki Uchida, Japan				
			GALA DINNER Exhibition Room, 7 th Floor Jikei University	17.30 19.00	

60th Anniversary World Congress • International College of Angiology 2018



in conjunction with 13th Japan Endovascular Symposium Jikei University School of Medicine

Tokyo, Japan
August 20-21, 2018

Scientific Program
Monday, 20 August 2018
09.00 h. – 09.10 h.

Opening Ceremony and Welcome Address

Master of Ceremonies
Introduction By:

Takao Ohki, MD, PhD, FICA

Professor of Surgery; Member, Board of Directors and Chairman, Local Organizing Committee, 60th Anniversary World Congress, International College of Angiology; Editor, *International Journal of Angiology*; Chairman, Department of Surgery and Professor and Chief, Division of Vascular Surgery, Jikei University School of Medicine, Tokyo, Japan.

Program Chairman and Chairman, Board of Directors

Kailash Prasad, MBBS (Hons), MD, PhD, DSc, FRCPC, FACC, FIACS, FICA

Professor Emeritus, Department of Physiology, College of Medicine, University of Saskatchewan, Saskatoon, Canada; Chairman, Board of Directors, and Program Chairman, 60th Anniversary World Congress, International College of Angiology; Consulting Editor, *International Journal of Angiology*.

President

Ernesto P. Molmenti, MD, PhD, MBA, FICA

Member and President, Board of Directors, International College of Angiology; Editorial Board, *International Journal of Angiology*; Vice Chairman, Department of Surgery; Director, Adult and Pediatric Kidney Transplantation; Professor of Surgery and Medicine, Northwell Health, Manhasset, New York, USA.

Chairman, Scientific Committee

Otmar M. Pachinger, MD, FESC, FAHA, FICA

Professor Emeritus, Distinguished Professor of Cardiology, Medical University of Innsbruck, Innsbruck, Austria; Member, Board of Directors, International College of Angiology; Chairperson, Scientific Committee, International College of Angiology; Senior Editor, *International Journal of Angiology*; President, Austrian Heart Foundation, Innsbruck, Austria.

Welcome Address

Fujio Mitarai

Chairman and CEO, Canon, Inc.

09.10 h. – 09.30 h.

Presidential Address

The Endovascular Revolution at Jikei and in Japan

Introduction By:

Kailash Prasad, MBBS (Hons), MD, PhD, DSc, FRCPC, FACC, FIACS, FICA

Professor Emeritus, Department of Physiology, College of Medicine, University of Saskatchewan, Saskatoon, Canada; Chairman, Board of Directors, and Program Chairman, 58th Annual World Congress, International College of Angiology; Consulting Editor, *International Journal of Angiology*.

Presentation By:

Takao Ohki, MD, PhD, FICA

Professor of Surgery; Member, Board of Directors International College of Angiology; Editor, *International Journal of Angiology*; Chairman, Department of Surgery and Professor and Chief, Division of Vascular Surgery, Jikei University School of Medicine, Tokyo, Japan.

09.30 h. – 10.15 h.

Memorial Lectures

Chairpersons:

Takao Ohki, MD, PhD, FICA

Professor of Surgery; Member, Board of Directors and Chairman, Local Organizing Committee, 60th Anniversary World Congress, International College of Angiology; Editor, *International Journal of Angiology*; Chairman, Department of Surgery and Professor and Chief, Division of Vascular Surgery, Jikei University School of Medicine, Tokyo, Japan.

Kailash Prasad, MBBS (Hons), MD, PhD, DSc, FRCPC, FACC, FIACS, FICA

Professor Emeritus, Department of Physiology, College of Medicine, University of Saskatchewan, Saskatoon, Canada; Chairman, Board of Directors, and Program Chairman, 60th Anniversary World Congress, International College of Angiology; Consulting Editor, *International Journal of Angiology*.

**Monday, 20 August 2018
Memorial Lectures (Continued)**

09.30 h. – 09.45 h.

**Setting a New Direction in the Development of Disease: AGE-RAGE Stress
Professor John B. Chang, MD Memorial Lecture**

Presentation By:

Kailash Prasad, MBBS (Hons), MD, PhD, DSc, FRCPC, FACC, FIACS, FICA

Professor Emeritus, Department of Physiology, College of Medicine, University of Saskatchewan, Saskatoon, Canada; Chairman, Board of Directors, and Program Chairman, 60th Anniversary World Congress, International College of Angiology; Consulting Editor, *International Journal of Angiology*.

Advanced glycation end products (AGE) and its cell-bound receptor (RAGE) have been implicated in the pathophysiology of numerous diseases. Presently the method to assess the involvement of AGE-RAGE axis in the development of disease is inadequate. AGE induces adverse effects directly and through its interaction with RAGE to produce diseases. The body has defense mechanisms that reduce the levels of AGE (enzymatic-and receptor-mediated degradation of AGE, reduction in formation of AGE), and soluble receptor for AGE (sRAGE) that antagonizes RAGE receptor. I have coined AGE and RAGE as “stressors”. Stress is defined as a process of altered biochemical homeostasis produced by physiological, psychological or environmental stressors. I have coined the defense mechanisms as “anti-stressors.” AGE- RAGE stress is defined as a shift in the balance between stressors and anti-stressors in favor of stressors. Simply the AGE-RAGE stress is the ratio of stressors/anti-stressors, the stressors being greater than anti-stressors. Methods have been developed by me to assess the AGE-RAGE stress. The ratio of AGE/sRAGE is a simplest, practical and important determinant of AGE-RAGE stress. A high ratio of AGE/sRAGE would indicate the presence of disease and associated complications. A high ratio of AGE/sRAGE is a risk factor for cardiovascular diseases AGE-RAGE stress can be reduced by various treatments.

In conclusion, high levels of AGE-RAGE stress is involved in the development of diseases and their complications. Reduction in AGE-RAGE stress would prevent regress and slow the progression of diseases and their complications.

09.45 h. – 10.00 h.

**Spontaneous Coronary Artery Dissection (SCAD)—Current State of Diagnosis and Management
Professor Albert Senn Memorial Lecture**

Presentation By:

Otmar M. Pachinger, MD, FESC, FAHA, FICA

Professor Emeritus, Distinguished Professor of Cardiology, Medical University of Innsbruck, Innsbruck, Austria; Member, Board of Directors, International College of Angiology; Chairperson, Scientific Committee, International College of Angiology; Senior Editor, *International Journal of Angiology*; President, Austrian Heart Foundation, Innsbruck, Austria.

Spontaneous coronary artery dissection (SCAD) has emerged as an important cause of acute coronary syndrome, myocardial infarction, and sudden death, particularly among young women and individuals with few conventional atherosclerotic risk factors.

SCAD is defined as spontaneous separation of the coronary artery wall by intramural hemorrhage that is not iatrogenic or related to trauma. Separation can occur between the intima and media, or between the media and adventitia. SCAD is typically reserved for the non-atherosclerotic variant.

The prevalence ranges from 1-4% of ACS overall– #1 cause peri-partum MI (43%)– etiology of 9-35% MI in women <50 ys. the presentation is not benign:

- STEMI ~ 50%
- VF ~ 15%
- Multivessel: 10-25%
- LAD > LCX > RCA
- Mid-distal vessel > proximal
- Initial troponin often normal

The etiology of SCAD is multifactorial, frequently associated with underlying predisposing arteriopathy (fibromuscular dysplasia, pregnancy- related, connective tissue disorders, systemic inflammatory disease, hormonal therapy, coronary artery spasm, and precipitating stressors).

Algorithm for the angiographic diagnosis and confirmation of SCAD will be presented. Intracoronary imaging modalities such as OCT and IVUS play an important role. The challenges for treatment are the choice of revascularization (CABG, PCI) but conservative management has highest priority! There are late issues related to stents and CABG and these procedures should be limited to patients with active ongoing ischemia or hemodynamic instability.

Monday, 20 August 2018
Memorial Lectures (Continued)

10.00 h. – 10.15 h.
Composition of Carotid Stenosis and Restenosis
Professor Hans H. Hachen Memorial Lecture
Presentation By:

Josef Veselka, MD, PhD, FICA

Professor of Internal Medicine; Member and President-Elect, Board of Directors, International College of Angiology; Editor, *International Journal of Angiology*; Chief, Department of Cardiology, 2nd School of Medicine, Charles University, University Hospital Motol, Prague, Czech Republic.

•
10.15 h. – 11.00 h.
HOT TOPICS IN ANGIOLOGY 1
Chairpersons:

Hiroshi Shigematsu, MD

Vascular Center, Sanno Medical Center, Tokyo, Japan; Editorial Board, *International Journal of Angiology*.

Wei Zhou, MD, FACS, FICA

Professor of Surgery; Member and Treasurer, Board of Directors, International College of Angiology; Co-Chairperson, Scientific Committee, International College of Angiology; Editorial Board, *International Journal of Angiology*; Chief, Vascular Surgery, Department of Surgery, University of Arizona, Tucson, Arizona, USA.

•
10.15 h. – 10.30 h.
Key Messages of the European Society for Vascular Surgery (ESVS) Mesenteric Ischemia Guidelines
Presentation By:

Martin Björck, MD, PhD

Professor of Vascular Surgery, Department of Surgical Sciences, Consultant, Section of Vascular Surgery, University Hospital, Uppsala, Sweden.

10.30 h. – 10.45 h.
Overview of the 59th Annual Meeting of the Japanese College of Angiology in Hiroshima
Presentation by:

Masao Yoshizumi, MD

Hiroshima University, Graduate School of Biomedical and Health Sciences, Hiroshima, Japan.

10.45 h. – 11.00 h.
The Development Status and Trend of the Japanese Society for Vascular Surgery (JSVS)
Presentation by:

Tetsuro Miyata, MD

Vascular Center, Sanno Hospital and Sanno Medical Center, Tokyo, Japan.

•
11.00 h. – 11.15 h. — BREAK
Exhibition Hall 7F

Monday, 20 August 2018

11.15 h. – 11.55 h.

ORAL SESSION 1

CRITICAL LIMB ISCHEMIA

*Chairpersons:***Katsuyuki Hoshina, MD**

Tokyo University, Tokyo, Japan

Randall W. Franz, MD, FACS, FICA, RVT, RPVI

Chief, Vascular and Endovascular Surgery, Medical Director, Grant Vascular and Vein Center; Assistant Professor of Surgery, Ohio State University; Professor of Surgery, Ohio University, Columbus, Ohio, USA; First Vice Chairman and Member, Board of Directors, International College of Angiology; Co-Chairperson, Scientific Committee, International College of Angiology; Editorial Board, *International Journal of Angiology*.

*Commentators:***Toshifumi Kudo, MD**

Division of Vascular Surgery, Tokyo Medical and Dental University, Tokyo, Japan.

Hiroshi Banno, MD

Nagoya University Hospital, Nagoya, Japan.

Wataru Higashiura, MD

Department of Radiology, Okinawa Prefectural Chubu Hospital, Okinawa City, Japan.

Koji Maeda, MD, PhD

Department of Surgery, Division of Vascular Surgery, Jikei University School of Medicine, Tokyo, Japan.

11.15 New Evaluation Method for Critical Lower Limb Ischemia using Laser Blood-Flowmeter BFD Clinical-Lab:

Sotaro Katsui, MD¹, Uchiyama Hidetoshi, MD¹, Yohei Yamamoto, MD², Toshifumi Kudo, MD², Yoshinori Inoue, MD², Ohnuki Masahiro, MD¹, ¹Department of Vascular and Endovascular Surgery, Tsuchiura Kyodo General Hospital, Ibaraki, Japan; ²Department of Surgical Specialties, Tokyo Medical and Dental University, Tokyo, Japan.

Background:

We previously reported a new method of evaluating critical limb ischemia (CLI) based on relative cold vasodilation (rCIVD) after local heating using a laser, speckle-contrast imaging device.

Objectives:

In order to simplify the procedure, we tested the BFD Clinical-Lab (Cosmotec, Inc.), which is a laser blood-flowmeter with a skin adhesive probe.

Methods:

We performed the laser blood-flowmeter thermal load (LTL) test on 66 limbs of 34 patients who were admitted with peripheral arterial disease (PAD) from October 2016 to April 2018. The definition of CLI was a Fontaine classification of III or IV degree, with transcutaneous oxygen tension (tcPO₂) of less than 30 mm Hg. The LTL test evaluated the minute blood flow decrease value (slope) following the peak of transient increase of rCIVD, which seemed to occur by relative cooling following local heating by a medical, electro-thermal, co-therapeutic device. This test classified each limb into the plateau group (group P; slope < 0.3 PU/min) with small slope change, or the decrease group (group D; slope ≥ 0.3 PU/min) with large slope decrease. We evaluated the CLI detection rate of group P using the receiver operating characteristic curve.

Results:

We detected CLI in 20 limbs (30.3%). There were 26 limbs in group P and 40 limbs in group D. The median values [25 - 75%] of tcPO₂ in group P and group D were 21 [range: 9-26] mmHg and 48 [range: 37-56] mmHg, respectively. Group P had a significantly lower TcPO₂ value than group D (p < 0.05). The CLI detection rate of group P had an 80.0% sensitivity and a 78.3% specificity.

Conclusions:

It was possible to detect rCIVD using the BFD Clinical-Lab, whose measurement is more simplified, suggesting its utility as a new evaluation method for CLI.

Monday, 20 August 2018
11.15 h. – 11.55 h.
ORAL SESSION 1
CRITICAL LIMB ISCHEMIA (Continued)

11.25 Undesirable Vascular Response during Peripheral Angioplasty on Systemic Lupus Erythematosus: Vito Anggarino Damay, MD, FICA, Wendy Wiharja, MD, Raymond Pranata, MD, Melisa Aziz, MD, Emanoel Oepangat, MD, Faculty of Medicine, University of Pelitas Harapan, Tangerang, Banten, Indonesia; Department of Cardiology and Vascular Medicine, Siloam Hospitals Lippo Village, Tangerang, Banten, Indonesia.

Background

Systemic lupus erythematosus (SLE) is associated with premature cardiovascular complications along with other comorbidity of autoimmune origin. Vascular events in SLE patients are often associated with disease duration and other metabolic comorbidities. Of patients within the SSCS (Swiss SLE Cohort Study), 13.3% had one or more vascular events: 8.3% CHD, 5% CVD and only 1.2% PAD.

Objectives

Review of a case of acute limb ischemia (ALI) in a young female with SLE.

Methods

Data was collected by clinical examination, laboratory and imaging studies.

Results

A 14-y.o. female presented with discoloration of her left toe 1 week before admission. Two weeks prior to admission, her toe was pale and blue. She has history of intermittent claudication 2 months prior to admission. One month prior to admission she was diagnosed with SLE. On physical examination: BP (110/70mmHg); Pulse (90 bpm); RR (20x/minute), temperature (36.6C) and cardiopulmonary and abdominal examination were unremarkable. Local examination of left toe indicated: black discoloration, low pulsation, localized tenderness (+) and sensation (+). Laboratory results showed ANA (+), complement C3 (103 mg/dL), C4 (7.4 mg/dL), CRP (1.16 mg/dL), DS-DNA (+), RIB (+) and D-Dimer (2.28 uG/mL). CT angiogram indicated near total occlusion of the popliteal artery and ALI was confirmed. We decided to perform an arteriography, which revealed total occlusion of the popliteal artery. During PTA, a guidewire easily went through the lesion. However, after multiple dilatations with a balloon catheter, there was still significant recoil, thus the vessel was unable to open completely. Cilostazol and lumbrokinase were given to the patient following the procedure and treatment. The patient was discharged without any further complaints, but the toe was still discolored with sensory and motor still intact. One week following discharge, there was no complaint of claudication and the discoloration improved slightly. We plan to do another arteriography for evaluation and another attempt at angioplasty.

Conclusion

ALI is a rare but potentially devastating complication of SLE. We therefore urge clinicians have a high index of suspicion, in order for treatment to commence early. A combination of angioplasty and antiplatelet therapy with an oral thrombolytic agent is promising in such cases.

11.35 Current Management of Chronic Mesenteric Ischemia: David Epstein, MD, FACS, RVPI, FICA, Ohio Health Heart and Vascular Surgeons, Grant Medical Center, Columbus, Ohio, USA.

Background

This presentation will be a review of current management of chronic mesenteric ischemia, and will review historical treatment techniques including open surgery and endovascular surgery. Indications for treatment and outcomes of endovascular techniques will be discussed. Will also review current experience at our institution.

Objectives

Understand current diagnosis and work up of chronic mesenteric ischemia. Better understanding of the vascular anatomy in mesenteric vascular disease. Compare and contrast risks and benefits of endovascular and open treatment of chronic mesenteric ischemia. Review more recent literature on treatment of chronic mesenteric ischemia.

Methods

Reviewed the current literature on treatment of chronic mesenteric ischemia, and a review of our experience at our institution for endovascular treatment of chronic mesenteric ischemia.

Results

Pending

Conclusion

Endovascular treatment of chronic mesenteric ischemia has good outcomes and is now the preferred first line treatment for this disease.

Monday, 20 August 2018
11.15 h. – 11.55 h.
ORAL SESSION 1
CRITICAL LIMB ISCHEMIA (Continued)

11.45 Malondialdehyde Induces a Pro-Inflammatory Activation of T-Cells from Human Atherosclerotic Plaque through both a Dependent and Independent Mechanism: Mizanur Rahman, MD¹, Johnny Steuer, MD², Peter Gillgren, MD², Anquan Liu, MD¹, Johan Frostegård, MD^{1,3}; ¹Institute of Environmental Medicine, Karolinska Institute, Stockholm, Sweden; ²Section of Vascular Surgery, Department of Surgery, Södersjukhuset, Institution of Clinical Science and Education, Karolinska Institute, Stockholm, Sweden; ³Division of Emergency Medicine, Karolinska University Hospital, Huddinge, Sweden.

Objective

Dendritic cells (DCs) and T cells are abundant in atherosclerotic plaques. Activated DCs and T cells could play an important role in plaque rupture and thus cardiovascular disease (CVD). Oxidized low density lipoprotein (OxLDL) activates immune cells including T cells from Atherosclerotic plaques but it is not known that which components of OxLDL play role. We therefore study lipid oxidation product MDA, conjugated with human serum albumin (MDA-HSA).

Method

DCs were differentiated from human blood monocytes and stimulated with MDA-HSA; autologous T cells from human blood or plaques were co-cultured with the simulated DCs or T cells stimulated directly with MDA in presence of absence of anti-MDA antibodies or mitochondrial reactive oxygen species inhibitor. T cells activation was investigated by FACScan. Transcription factors and cytokines were measured by RT-qPCR and ELISA respectively. MDA modified peptide sequence from in vitro HSA atherosclerotic patients' plasma was analyzed by mass spectrometry.

Results

MDA-HSA induced a pro-inflammatory T cell activation and pro-inflammatory cytokine production. MDA-HSA induced toll like receptors 2 and 4 in both T cells and DC. Both ROS inhibitor and anti-MDA antibodies inhibited MDA-HSA-induced direct T cell activation. Further, MDA-HSA induced apoptosis in both DCs and T cells. In vitro, 30 peptides sequences in HSA and 9 peptides sequences in HSA from atherosclerotic patients' plasma were modified by MDA.

Conclusions

Atherosclerotic plaque T cells activated by MDA in both DC dependent and independent mechanisms, inducing proinflammatory cytokines. This could play a role in plaque rupture and thus risk of CVD. Antibodies to MDA or ROS inhibitor is a therapeutic possibility to reduce inflammation in atherosclerosis and thus against CVD.

11.55 h. – 12.35 h.
ORAL SESSION 2
ENDOVASCULAR TREATMENT

Chairpersons:

Yuji Kanaoka, MD, PhD, FICA

Kawasaki Medical School, Okayama, Japan

Sibu P. Saha, MD, MBA, FICA

Professor of Surgery and Bioengineering; Member, Board of Directors and Scientific Committee, International College of Angiology; Editorial Board, *International Journal of Angiology*; Chief, Division of Cardiovascular and Thoracic Surgery, University of Kentucky, Lexington, Kentucky, USA.

Commentators:

Masanori Inoue, MD

Department of Radiology, Keio University School of Medicine, Tokyo, Japan.

Kunihiro Shigematsu, MD

International University of Health and Welfare, Mita Hospital, Tokyo, Japan.

Nobuya Zempo, MD

Department of Cardiovascular Surgery, Kansai Medical University Hospital, Hirakata City, Japan.

Takashi Murakami, MD, PhD

Department of Cardiovascular Surgery, Osaka City University Graduate School of Medicine, Osaka, Japan.

11.55 Restoration of Vision by Endovascular Reperfusion in Takayasu's Arteritis—Case Series: Sanjay Tyagi, MD, DM(Cardiology), FAMS, FESC, FACC, Member, Editorial Board, *International Journal of Angiology*; Director, Professor and Head; Mohit D. Gupta, MP Girish, Swati Tyagi, Ankit Bansal, Department of Cardiology, GB Pant Institute of Postgraduate Medical Education and Research, Maulana Azad Medical College, New Delhi, India.

Purpose

Takayasu's arteritis (TA) is a rare, inflammatory vasculitis affecting the aorta and its branches. Stenotic occlusive lesions of multiple arch arteries can cause severe cerebral ischemia leading to impaired vision. Bypass graft surgery has been used in such situations, but has a high morbidity and mortality rate. Endovascular revascularization by angioplasty is a less invasive option. However, its use in improving diminution of vision caused by TA has rarely been reported.

Material and Methods

We report on three consecutive cases with severe diminution of vision in the upright posture where we attempted to improve vision by improving perfusion by stent-supported angioplasty. The diagnosis of TA was made according to the criteria of the American College of Rheumatology. Patients with raised inflammatory markers were given oral glucocorticoids. We attempted restoration of sight by improving cerebral blood flow by percutaneous endovascular revascularization. Initially aortic arch angiography and selective angiography was performed to localize the site and severity of stenosis.

Results

Percutaneous transluminal angioplasty was performed under local anesthesia through the femoral artery. All three patients (ages 27-37 years) were successfully re-vascularized with substantial improvement in vision. There was no reported complications. The patients were continued on oral steroids, aspirin and clopidogrel. On follow-up examination, one patient developed a recurrence of visual symptoms due to restenosis, which was successfully treated by cutting balloon angioplasty. All three patients continue to be asymptomatic on follow-up of 9-24 months.

Conclusion

This case series shows that stent-supported angioplasty is a minimally invasive technique which is safe and effective in restoring impaired vision caused by severe cerebral hypo-perfusion in TA.

Monday, 20 August 2018
11.55 h. – 12.35 h.
ENDOVASCULAR TREATMENT (Continued)

12.05 Open Surgery versus Hybrid Endovascular Treatment for Complete Revascularization in Infrarenal Aortoiliac Occlusive Disease: Won-Min Jo, MD, PhD, Byoung-Ju Min, MD, Jinwook Hwang, MD, Jae Sung Shin, MD, Department of Thoracic and Cardiovascular Surgery, Ansan Hospital, Korea University Medical Center, Ansan City, Gyeonggi-do, South Korea.

BACKGROUND

Aorto-biiliac or aorto-bifemoral bypass surgery under laparotomy has been the gold standard treatment for aortoiliac occlusive disease (AIOD). This surgery provides excellent long-term patency. However, it is also associated with a considerable perioperative mortality and morbidity rate. Due to an increase in the number of old high-risk patients who require surgery, these mortality and morbidity rates have not decreased significantly.

OBJECTIVES

This study aimed to retrospectively investigate the clinical effectiveness of hybrid endovascular treatment (non-laparotomy surgery with endovascular intervention; Group 2) versus open laparotomy surgery (aorto-biiliac or aorto-bifemoral bypass; Group 1) for synchronous complete revascularization in AIOD.

METHODS

From January 2010 to December 2016, 95 patients were enrolled (Group 1: 46, Group 2: 49; mean follow-up period, 39.7 months). The patency and limb salvage rates for The Atlantic Inter Society Consensus Classification (TASC) II C and D patients were analyzed using Kaplan-Meier curves.

RESULTS

The patients were predominantly male (87.4%), and their mean age was 69.76 years. There were no significant differences in demographics; the most common risk factor and symptoms were arterial hypertension and claudication in both groups. Only one perioperative death was observed, in Group 1. The 1-, 2- and 3-year primary patency rates were 97.8%, 97.8%, and 94.8% in Group 1, and 87.0%, 75.5%, and 69.2% in Group 2, respectively, which were significantly different ($p=.013$). However, the secondary patency rates were not significantly different ($p=.708$); the 1-, 2- and 3-year limb salvage rates for TASC II C and D patients were also not significantly different (Group 1: 100%, 100%, and 96.7%, Group 2: 100%, 100%, and 89.5%, respectively, $p=.182$).

CONCLUSIONS

Although our study showed marginally lower primary patency rate for complete revascularization in hybrid treatment than in open laparotomy surgery, the limb salvage rates were not significantly different. Early mortality rate was lower with hybrid endovascular treatment. Therefore, non-laparotomy surgery with endovascular interventional treatment could be a good alternative for synchronous complete revascularization in high-risk patients.

Monday, 20 August 2018
11.55 h. – 12.35 h.
ENDOVASCULAR TREATMENT (Continued)

12.15 Endovascular Intervention after Infected Open Revascularization: Richard W. Schutzer, MD, FICA,
Department of Cardiovascular Surgery, New York Presbyterian Hospital, Columbia University Medical Center, New York, New York;
Editor, *International Journal of Angiology*.

Over the past decade, the paradigm for peripheral arterial disease has transitioned. Current treatment frequently involves an endovascular first approach. Open revascularization is often reserved for specific situations, such as repeated endovascular failure, limited runoff, or extremely long disease segments. This challenging population for open revascularization presents additional problems, especially when complications are encountered. One such problem involves surgical site infection. Estimated to occur up to 22.8% of the time, these infections can be devastating. Although some infections can be treated solely with antibiotics, others lead to graft thrombosis or infection, requiring explanation. In a limb already compromised from ischemia, this may ultimately lead to amputation. Options in the treatment of this ischemia include redo bypass in “uninfected fields,” and use of alternate conduits such as cryopreserved veins. This paper includes a series of patients faced with this challenging situation. Limb salvage was ultimately achieved with endovascular revascularization as either a temporizing or permanent measure.

12.25 Early and Mid-Term Outcomes of Primary Carotid Endarterectomy: Robert Hacker, MD, FACS, RVT, RPVI,
Sadeep Bose, MD, Mercy Health—Heart and Vascular Institute, Toledo, Ohio, USA.

Background

The current literature supports that patch angioplasty after carotid endarterectomy reduces the rate of restenosis when compared to primary closure. As a result, primary endarterectomy has fallen out of favor and the collective memory of training surgeons. Recent evidence suggests that primary carotid endarterectomy performed by a modern day vascular surgeon does not this same level of restenosis as previously observed. Furthermore, primary closure shortens operative time and eliminates complications associated with graft implantation.

Objectives

This study was performed to add to the new generation of surgeons to demonstrate the safety and efficacy of primary carotid endarterectomy.

Methods

Over a 32-month period, all carotid endarterectomies performed by a single vascular surgeon were carried out with a primary closure and monitored by somatosensory evoked potentials (SSEP) with a selective-shunting strategy. Patients were followed up post-operatively with a carotid duplex and physical exam at 30 days and 1 year. Patients were monitored for complications including bleeding, infection, and evidence of restenosis, stroke, and mortality.

Results

Over a study period of 32 months, 28 primary carotid endarterectomies were performed, primarily for asymptomatic carotid stenosis (72%). One patient required placement of a shunt due to SSEP changes upon clamping of the internal carotid artery (ICA). Average ICA clamp time was 39 minutes with an average total operative time of 113 minutes. There were no intra- or post-operative strokes. There was no stenosis >50% based on duplex velocities on follow-up ultrasound at 30 days and on those who met the 1 and 2 year follow-up. Two patients had new asymptomatic contralateral occlusions. There was one mortality, a patient who died after his second CEA due to a MVC unrelated to his operation.

Conclusion

Primary carotid endarterectomy is a safe and efficacious surgical procedure that is not inferior to patch angioplasty. This surgical technique should be considered as one closure option when treating vascular patients.

12.35 h. – 12.45 h. — BREAK

Exhibition Hall 7F

12.45 h. – 13.35 h.

LUNCHEON SEMINAR 1

(Co-Sponsored by W.L. Gore & Associates Co., LTD.)

Chairperson:

Takao Ohki, MD, PhD, FICA

Professor of Surgery; Member, Board of Directors International College of Angiology; Editor, *International Journal of Angiology*; Chairman, Department of Surgery and Professor and Chief, Division of Vascular Surgery, Jikei University School of Medicine, Tokyo, Japan.

The Value of Excluder IBE—Preservation of IIA and Prevention of Type Ib Endoleak: Masayuki Hara, MD, Department of Surgery, Division of Vascular Surgery, Jikei University School of Medicine, Tokyo, Japan.

The Price of Sacrificing the Internal Iliac Artery Blood Flow—What Have We Learned from Clinical Experiences and What do the Clinical Practice Guidelines Recommend? Martin Björck, MD, PhD, Professor of Vascular Surgery, Department of Surgical Sciences, Consultant, Section of Vascular Surgery, University Hospital, Uppsala, Sweden.

13.35 h. – 13.40 h. — BREAK

Exhibition Hall 7F

13.40 h. – 14.40 h.

SYMPOSIUM 1

ABDOMINAL AORTIC ANEURYSMS

Chairpersons:

Makato Sumi, MD, PhD, FICA

Department of Surgery, Division of Vascular Surgery, Jikei University School of Medicine, Tokyo, Japan.

John A. Elefteriades, MD, FACS, FICA

William W.L. Glenn Professor of Cardiothoracic Surgery; Second Vice Chairman and Member, Board of Directors, International College of Angiology; Co-Chairperson, Scientific Committee, International College of Angiology; Editor-in-Chief, *International Journal of Angiology*; Director, Aortic Institute at Yale-New Haven, Yale University School of Medicine, New Haven, Connecticut, USA.

Commentators:

Taku Kokubo, MD

Department of Vascular Surgery, Edogawa Hospital, Tokyo, Japan.

Naoki Fujimura, MD

Department of Vascular Surgery, Saiseikai Central Hospital, Tokyo, Japan.

Atsubumi Murakami, MD

International University of Health and Welfare Hospital, Tokyo, Japan.

13.40 Endoleak after EVAR: Shigeo Ichihashi, MD, Department of Radiology, Nara Medical University, Nara, Japan.

13.55 Early Sac Shrinkage is a Good Surrogate Marker of Durable Success after Endovascular Aneurysm Repair in Japanese Patients: Naoki Fujimura, MD, PhD, Department of Vascular Surgery, Saiseikai Central Hospital, Tokyo, Japan.

14.10 A Multicenter Experience with Abdominal Aortic Endograft Infections in Japan: Hideaki Obara, MD, FICA, Department of Surgery, Keio University School of Medicine, Tokyo, Japan.

14.25 EVAR for Ruptured Abdominal Aortic Aneurysm: Hidemitsu Ogino, MD, Director, Department of Surgery, Narita Tomisato Takushukai Hospital, Tomisato-City, Japan.

Monday, 20 August 2018

14.40 h. – 15.30 h.

TEATIME SEMINAR 1

LATEST INFORMATION ON IMAGE GUIDED SYSTEMS

(Co-Sponsored by Canon Medical Systems Corporation)

Chairperson:

Takao Ohki, MD, PhD, FICA

Professor of Surgery; Member, Board of Directors International College of Angiology; Editor, *International Journal of Angiology*; Chairman, Department of Surgery and Professor and Chief, Division of Vascular Surgery, Jikei University School of Medicine, Tokyo, Japan.

Naoki Fujimura, MD, PhD

Department of Vascular Surgery, Saiseikai Central Hospital, Tokyo, Japan.

Kanako K. Kumamaru, MD, PhD

Department of Radiology, Juntendo University School of Medicine, Tokyo, Japan.

15.30 h. – 15.45 h. — BREAK

Exhibition Hall 7F

15.45 h. – 17.15 h.

SYMPOSIUM 2

CAROTID AND PERIPHERAL ARTERIAL DISEASE

Chairpersons:

Hideaki Obara, MD, FICA

Department of Surgery, Keio University School of Medicine, Tokyo, Japan.

Kailash Prasad, MBBS (Hons), MD, PhD, DSc, FRCPC, FACC, FIACS, FICA

Professor Emeritus, Department of Physiology, College of Medicine, University of Saskatchewan, Saskatoon, Canada; Chairman, Board of Directors, and Program Chairman, 60th Anniversary World Congress, International College of Angiology; Consulting Editor, *International Journal of Angiology*.

15.45 Zilver PTX Post-Market Surveillance Study of Paclitaxel Eluting Stents for Treating Femoropopliteal Artery Disease in Japan: 5-Year Results: Hiroyoshi Yokoi, MD, Professor, International University of Health and Welfare; Director, Cardiovascular Center, Fukuoka Sanno Hospital, Fukuoka, Japan.

16.00 Beyond Stroke—What Have We Learned about Carotid Disease? Wei Zhou, MD, FACS, FICA, Professor of Surgery; Member and Treasurer, Board of Directors, International College of Angiology; Co-Chairperson, Scientific Committee, International College of Angiology; Editorial Board, *International Journal of Angiology*; Chief, Vascular Surgery, Department of Surgery, University of Arizona, Tucson, Arizona, USA.

16.15 Pathogenesis in Clinical Significance of Buerger's Disease and Peripheral Arterial Disease (PAD): Takehisa Iwai, MD, PhD, Director and Head, Tsukuba Vascular Center and Buerger's Disease Research Institute, Moriya City, Japan.

16.30 Variation in Atherosclerotic Plaque Feature in Swine Artery Induced with Partial Ligation, Denudation and External Irrigation: Jackie P. Ho, MBBS, FRCS, FCS, FHKAM, Associate Professor, Department of Surgery, Yong Loo Lin School of Medicine, National University of Singapore, Singapore; Consultant, Department of Cardiac, Thoracic and Vascular Surgery, National University Heart Center, Singapore.

16.45 Treatment of Peripheral Vascular Disease via Percutaneous Brachial Artery Access: Randall W. Franz, MD, FACS, FICA, RVT, RPVI, Chief, Vascular and Endovascular Surgery, Medical Director, Grant Vascular and Vein Center; Assistant Professor of Surgery, Ohio State University; Professor of Surgery, Ohio University, Columbus, Ohio, USA; First Vice Chairman and Member, Board of Directors, International College of Angiology; Co-Chairperson, Scientific Committee, International College of Angiology; Editorial Board, *International Journal of Angiology*.

Objective: This review was conducted to evaluate the types of endovascular procedures that can be performed via brachial artery access. Technique is described. Complications and occurrence rates were reported.

Methods: A retrospective ten-year chart review at a tertiary facility from January 1, 2005 through June 30, 2015 was completed. Patients who underwent attempted brachial artery access were eligible for review.

Results: A total of 265 access cases in 179 patients were reviewed. Access success rate was 98.9%. Intervention was performed in 223 cases (84.2%) with the remaining cases being diagnostic angiograms (14.9%). Angioplasty was the most common intervention (59%, 154 cases) with stents, atherectomy, coiling, and percutaneous thrombectomy having also been performed. Complications included hematoma (2.3%) and pseudoaneurysm (1.5%). Interventions were performed on all major vessels as distal as the dorsalis pedis. Sheath sizes ranged from 4 French to 7 French. Intervention was performed in bilateral lower extremities in 38 (14.5%) cases.

Conclusions: Brachial access is a reliable and effective option for treatment of peripheral vascular disease and should be considered when femoral access is difficult or contraindicated. Additionally, bilateral lesions may be approached easily through one brachial artery access site making this approach advantageous when expecting bilateral lesions. A complication rate similar to femoral access should be expected.

17.00 Endovascular Approaches for Complex below the Knee (BTK) Chronic Total Occlusion (CTO) Lesion: Hiroshi Ando, MD, Kasukabe Chuo General Hospital, Saitama, Japan.

Monday, 20 August 2018
17.15 h. – 18.15 h.
e-POSTER PRESENTATIONS

Chairpersons:

Makoto Mo, MD

Chief, Cardiovascular Surgery, Yokohama Minami Kyosai Hospital, Yokohama, Japan.

Thomas F. Whayne, Jr., MD, PhD, FICA

Professor of Medicine (Cardiology); Vice President, International College of Angiology; Gill Heart Institute, University of Kentucky, Lexington, Kentucky, USA.

Commentators:

Katsuhiko Oka, MD

Kyoto Prefectural University of Medicine, Kyoto, Japan.

Seiji Onitsuka, MD

Department of Surgery, Kurume University School of Medicine, Kurume, Japan.

Masayuki Hirokawa, MD, PhD

Director, Ochanomizu Vascular and Vein Clinic, Tokyo, Japan.

Hideaki Maeda, MD

Second Department of Surgery, Nihon University School of Medicine, Itabashi Hospital, Tokyo, Japan.

17.15 Treatment of Deep Vein Thrombosis in May-Thurner Syndrome with Non-Vitamin K Oral Anticoagulants: A Case Report: Toh Ching Han¹ and Ashish Anil Sule, MBBS, MD, MRCP, FAMS, FICA, FRCP²; Regional Secretary, International College of Angiology; ¹Lee Kong Chian School of Medicine, Nanyang Technological University, Singapore; ²Department of General Medicine, Subspecialty of Vascular Medicine and Hypertension, Tan Tock Seng Hospital, Singapore.

Background

May-Thurner syndrome (MTS) describes an anatomical variant where the left common iliac vein (CIV) is compressed by the overlying right common iliac artery and the underlying lumbar vertebrae, leading to stenosis in the left CIV. Patients with MTS have varied presentation, ranging from symptoms of venous hypertension, to deep vein thrombosis (DVT). Endovascular intervention followed by anticoagulation currently constitute the mainstay of management of MTS associated with recurrent DVT.

Objectives

Warfarin appears to be the anticoagulant of choice in most studies done in patients with MTS. There is little evidence of treatment using non-vitamin K oral anticoagulants. This case report serves to illustrate a patient with MTS who was successfully treated with pharmaco-mechanical catheter directed therapy, followed by anticoagulant using rivaroxaban.

Methods

This paper discusses a case of MTS in a 64-year-old Indian woman who presented with left lower limb swelling and was found on duplex ultrasound to have extensive DVT. Computed tomography showed underlying narrowing of the left CIV.

Results

She underwent pharmaco-mechanical catheter directed therapy, involving stent placement in the left CIV, and subsequently started on rivaroxaban. She developed a partial thrombosis of the external iliac vein at 5 months post-procedure, and a partial stent thrombosis at 1 year post-procedure whilst on rivaroxaban, requiring repeat stenting and continuation of anticoagulation. The patient was followed-up clinically with no recurrence of symptoms related to MTS, no post-thrombotic syndrome, and no clinically significant bleeding as a side effect of rivaroxaban.

Conclusion

This case report shows that rivaroxaban is a safe agent that can be successfully used in the treatment of DVT in the context of MTS after stenting, with the avoidance of side effects of major bleeding that are associated with warfarin.

Monday, 20 August 2018
e-POSTER PRESENTATIONS (Continued)

17.22 Anticoagulation for Antiphospholipid Syndrome in a Patient with Severe Thrombocytopenia: Case Report:
Prathika Parmalingam, MBBS, MRCP, MMED, Senior Resident; Ashish Anil Sule, MBBS, MD, MRCP, FAMS, FICA, FRCP, Regional Secretary, International College of Angiology; Department of General Medicine, Tan Tock Seng Hospital, Singapore.

Background

Antiphospholipid syndrome (APS) can be associated with thrombocytopenia. When thrombocytopenia is marked, the safety of anticoagulation may be of concern to physicians.

Case presentation

We report on a case of a 19-year-old Indian gentleman diagnosed with primary APS in April 2017.

He had asymptomatic thrombocytopenia detected in 2016 during a health screening, which was under investigation. In 2017, he developed right calf swelling and was diagnosed with deep vein thrombosis extending from the popliteal vein to the distal femoral vein. Low molecular weight heparin (enoxaparin) was initiated. Investigations revealed an isolated prolonged activated partial thromboplastin time (57.3 seconds) which was not correctable. Lupus anticoagulant, anti-b2 glycoprotein and anti-cardiolipin were positive (strongly present, 106 RU/mL and 26 GPL Units respectively). ANA, ds-DNA and ESR were normal. His platelet count was $80 \times 10^9/L$. Hepatitis markers, retroviral screen and peripheral blood film were sent, and all returned results were normal. B12 and folate levels were borderline (179 pmol/L and 8 nmol/L respectively) and replaced. He had no clinical features of connective tissue disease.

Upon initiating the patient on warfarin, his platelet count down trended to $41 \times 10^9/L$. He was started on oral prednisolone 1mg/kg/day (70mg/day) and his platelet count up-trended to 153 after 6 days. Prednisolone was tapered off over a 2 week period and his platelet count dropped once again to the 30-70s range. Haematology was consulted and suggested to continue anticoagulation if there was no bleeding, with no need for definite therapy. Patient is currently on warfarin and platelet count has remained stable since (range 83-106).

Conclusion

This patient had APS with thrombocytopenia, likely immune-mediated. Anticoagulation was needed in this setting as the patient was deemed to be at high risk of recurrent thrombosis with his antiphospholipid antibody profile.

This case highlights the challenges in continuing anticoagulation for APS associated with severe thrombocytopenia. Immunosuppressive therapy (steroids/steroid-sparers) is generally reserved for cases of severe thrombocytopenia (as in our patient), or catastrophic APS.

Monday, 20 August 2018
e-POSTER PRESENTATIONS (Continued)

17.29 Bilateral Unprovoked Deep Vein Thrombosis in an Elderly Gentleman with Hyperhomocysteinemia: Joey Ying Hao Wong, MBBS, NTU-Imperial Lee Kong Chian School of Medicine, Singapore; Ashish Anil Sule, MBBS, MD, MRCP, FAMS, FICA, FRCP, Senior Consultant, General Medicine, Vascular Medicine and Hypertension, Tan Tock Seng Hospital, Singapore.

Background

Homocysteine is derived from the biosynthesis of methionine through a series of steps. It is an intermediate substance between methionine and cysteine. Causes of elevated hyperhomocysteinemia can be classified into genetic and secondary causes such as end-stage renal disease, hypothyroidism, malignancy and drugs. Elevated homocysteine levels are known to be associated with arterothrombotic and venous thromboembolisms. However, cases of homocysteinemia with venous thrombosis rarely occur.

Objectives

This case report aims to illustrate the rare case of bilateral deep vein thrombosis (DVT) of the lower limbs in a patient with hyperhomocysteinemia. We will discuss homocysteinemia in relation to folate and Vitamin B12, and whether this has clinical significance to change outcomes.

Methods

This paper discusses a 64-years-old Chinese gentleman who was admitted on 8th November 2016 for an acute onset of shortness of breath and a non-compressible right popliteal vein. He was found to have non-ST elevated myocardial infarction and an unprovoked bilateral DVT of the lower limbs after ultrasound Doppler of the bilateral lower limbs.

Results

Given that extensive bilateral DVT with no apparent cause in a middle aged gentleman is rare, and our patient was previously ambulant with no recent hospital admissions, further tests were done to work up and rule out states of hypercoagulability (thrombophilia screen) and malignancy. An ultrasound of the abdomen and kidneys did not reveal any significant abnormalities. Furthermore, the thrombophilia screen for Protein C, Protein S, Factor V Leiden and lupus anti-coagulants were also normal. Homocysteine levels were then tested and he was found to have intermediately high homocysteine levels of >50umol/L (reference range 5-15). He was subsequently treated with subcutaneous heparin before transitioning to long term warfarin, and started on vitamin-B12 and folate supplementation.

Conclusion

In conclusion, the association of homocysteinemia with venous thromboembolism, though rare, can still occur. There is still much more clinical data needed in terms of screening for homocysteinemia in venous thromboembolism; and whether it will make a difference in outcomes with treatment options of supplementation and anti-coagulation.

Monday, 20 August 2018
e-POSTER PRESENTATIONS (Continued)

17.36 The Association of High Blood Homocysteine and the Risk of Increased Severity of Ischemic Stroke Events: Salim Harris, MD, PhD, Al Rasyid, MD, PhD, Mohammad Kurniawan, MD, Taufik Mesiano, MD, Rakhmad Hidayat, MD, Neurology Department, Faculty of Medicine, University of Indonesia, Jakarta, Indonesia.

Stroke is the leading cause of death and disability in the world as well as in Indonesia. Stroke burden is the result of the disability and functional outcomes of stroke survivors. Initial stroke severity is an important factor that affects short- and long-term stroke outcomes. Factors that affect the risk of stroke incidence such as blood homocysteine may also affect stroke severity. This study was conducted in Cipto Mangunkusumo Hospital from July 2017 to January 2018 using a cross-sectional design. There were 77 acute ischemic stroke patients included in this study and were evaluated for stroke risk factors and initial NIHSS examination. Patients were divided into three groups, which include normal blood homocysteine levels (< 9 $\mu\text{mol/L}$), low-moderate blood homocysteine levels (9-15 $\mu\text{mol/L}$), and high blood homocysteine levels (>15 $\mu\text{mol/L}$). The acquired data was analyzed using Kruskal-Wallis test in SPSS version 17. A significant difference of initial NIHSS and blood homocysteine levels ($\chi^2(2) = 13.328, p = 0.001$) were seen with a mean rank of 25.86 for normal blood homocysteine levels, 33.69 for mild-moderate blood homocysteine levels and 48.94 for high blood homocysteine levels. The patients were then divided into two groups based on the NIHSS (≤ 5 and > 5) to calculate the risk correlation of blood homocysteine levels and NIHSS by logistic regression and odds ratio. We found that patients with high blood homocysteine levels had a 14.4 times higher risk of having NIHSS > 5 compared to those with low blood homocysteine levels ($p=0.002$, 95% CI [2.714-76.407]), and 3.9 times higher risk compared to those with low-moderate blood homocysteine levels ($p=0.011$, 95% CI [1.371-11.246]). We concluded that homocysteine is a risk factor for a higher stroke severity. Future studies to evaluate the usefulness of homocysteine-lowering therapy in stroke patients are recommended.

17.43 Comparison Between Sensitivity and Specificity of Ankle Brachial Index and Carotid Intima-Media Thickness for Detecting Significant Coronary Artery Disease: Novi Anggriyani, MD, FICA¹, Joceline Theda Kadarman, MD¹, Wahyu Wiryawan, MD², ¹Faculty of Medicine, Diponegoro University, Semarang, Indonesia; ²Division of Cardiothoracic and Vascular Surgery, Department of Surgery, Diponegoro University, Semarang, Indonesia.

Background

The current gold standard for the diagnosis of Coronary Artery Disease (CAD) is coronary angiography. Not all patients can undergo a coronary angiography procedure, because of its contrast agent. Furthermore, it is an invasive procedure wherein the patient is exposed to radiation, and therefore, it is necessary to use a safer diagnostic device with minimal side effects for the detection of CAD. *Ankle-Brachial Index (ABI)* and *Carotid Intima-Media Thickness (CIMT)* are simple noninvasive tools without the exposure to radiation, both of which have good correlation with CAD.

Objectives

To compare the sensitivity and specificity of ABI and CIMT for diagnosing significant CAD.

Methods

This study consists of 60 people who had a coronary angiography procedure in Permata Medika Hospital Semarang, then ABI and CIMT value were measured. The data used in the study was primary and secondary data. ABI was measured by oscillometric method and the normal value is 0.9 to 1.3; while CIMT was measured by ultrasonography, normal value is less than 0.9 mm, was access in common carotid artery and carotid bulb. This was a diagnostic test study to compare ABI and CIMT with the gold standard coronary angiography procedure for detection of significant CAD.

Results

There were 43 males and 17 females included in this study. Compared to coronary angiography, ABI has a sensitivity 35.71% and specificity 94.44% in detecting significant CAD. The diagnostic test result of the common carotid artery CIMT sensitivity and specificity respectively is 73.81% and 77.78%; while in carotid bulb, the sensitivity is 95.24% and specificity is 61.11%.

Conclusion

ABI and CIMT are simple noninvasive tools without radiation which can be used to detect significant CAD. The measurement of ABI and CIMT values can be done and repeated easily. The most sensitive test is CIMT which was examined in the carotid bulb, whereas ABI is the most specific one.

Monday, 20 August 2018
e-POSTER PRESENTATIONS (Continued)

18.00 EVAR-First Strategy for Ruptured Aortic Aneurysm: A Clinical Analysis of 20 Cases: Daiki Uchida, MD, Takamitsu Tatsukawa, MD, Ai Tochikubo, MD, Naoya Kuriyama, MD, Shinsuke Kikuchi, MD, Atsuhiko Koya, MD, Nobuyoshi Azuma, MD, FICA, Professor and Chairman; Vice President, Scientific Council, International College of Angiology; Editor, International Journal of Angiology; Division of Vascular Surgery, Asahikawa Medical University, Asahikawa, Japan.

Background

Ruptured abdominal aneurysm (rAAA) is one of the highest life-threatening diseases in a surgical emergency and its treatment with endovascular aneurysm repair (EVAR) with increasing frequency. In our institution, we have treated patients with EVAR-first strategy since 2011.

Objectives

We aimed to evaluate our EVAR-first strategy and clinical early outcome in rAAA patients.

Methods

Patients with rAAA who underwent emergency EVAR between January 2011 and April 2018 were included in this study. There were 16 (80%) men and 4 (20%) women with a mean age of 76.7 ± 10.8 years. Rutherford's classification R3 and R4 level which presents in severe shock were detected in 12 (60%) cases. Five were transferred by medical helicopter and the inter-hospital collaboration system (Join, Allm Inc.) was applied in 9 (45%) cases. Preoperative CT showed a mean AAA maximum diameter, proximal neck length, and proximal neck diameter of 69.0 ± 11.4 mm, 20.9 ± 3.5 mm, and 27.3 ± 13.7 mm respectively.

Results

There were no intraoperative deaths. The early mortality rate was 5%, and the technical success rate was 100%. Intra- aortic occlusion balloon was used to control unstable hemodynamics and the Gore Excluder endograft was used in 18 (90%) patients. Sac embolization to control continuous bleeding was performed in 7 (35%) patients. Type2 endoleak was detected in 2 (10%) of the patients. Laparotomy (intraoperative or delayed) for abdominal compartment syndrome (ACS) was required in 8 (40%) patients. As major complications, 6 (30%) patients had acute renal failure requiring hemodialysis, 4 (20%) patients had ileus, 2 (10%) patients had bowel necrosis and 1 (5%) patient had paraplegia. Mean length of intensive care unit stay was 8.0 (range 1–30) days, and mean length of hospital stay was 33.1 (range 1–60) days. Ten (50%) patients were discharged from the hospital to directly home.

Conclusions

Based on this clinical case series, our EVAR-first strategy for rAAA patients was feasible and acceptable in mortality and morbidity rates.

•
17.15 h. – 18.15 h.
ICA BUSINESS MEETING
Board of Directors
Jikei Building 2

Tuesday, 21 August 2018

08.30 h. – 09.20 h.

MORNING SEMINAR

COOK VASCULAR SYMPOSIUM—EVAR & SFA TREATMENTS

(Co-Sponsored by Cook Japan)

Chairperson:

Shigeo Ichihashi, MD

Department of Radiology, Nara Medical University, Nara, Japan.

Sciencing Zenith—Why We Should be Using Zenith Stent Grafts: Naoki Fujimura, MD, PhD, Department of Vascular Surgery, Saiseikai Central Hospital, Tokyo, Japan.

Is It Possible? “Leave Nothing Behind Concept” for SFA Treatment: Tatsuya Nakama, MD, Tokyo Bay Urayasu Ichikawa Medical Center, Tokyo, Japan.

09.20 h. – 09.50 h.

ORATION LECTURES

Chairpersons:

Nobuyoshi Azuma, MD, FICA

Professor and Chairman, Department of Vascular Surgery, Asahikawa Medical University, Asahikawa, Japan; Vice President, Scientific Council, International College of Angiology; Editor, *International Journal of Angiology*.

Takao Ohki, MD, PhD, FICA

Professor of Surgery; Member, Board of Directors International College of Angiology; Editor, *International Journal of Angiology*; Chairman, Department of Surgery and Professor and Chief, Division of Vascular Surgery, Jikei University School of Medicine, Tokyo, Japan.

09.20 h. – 09.35 h.

Thoracic Aortic Aneurysms: Practical Genetics for the Surgeon

Professor Kailash Prasad Oration Lecture

Presentation By:

John A. Eleftheriades, MD, FACS, FICA

William W.L. Glenn Professor of Cardiothoracic Surgery; Second Vice Chairman and Member, Board of Directors, International College of Angiology; Co-Chairperson, Scientific Committee, International College of Angiology; Editor-in-Chief, *International Journal of Angiology*; Director, Aortic Institute at Yale-New Haven, Yale University School of Medicine, New Haven, Connecticut, USA.

09.35 h. – 09.50 h.

Scrutinizing the General Applicability of the CE Approved Chimney Procedure for Short Neck and Juxtarenal Aortic Pathologies – 109 Fenestrated Endovascular Aneurysm Repair Cases Revisited

Professor Otmar M. Pachinger Oration Lecture

Presentation By:

Jürgen Falkensammer, MD, FICA^{1,2}

Vice President, Scientific Council, International College of Angiology, Miriam Uhlmann, MD¹, Elisabeth Pelanek-Völk, MD¹, Markus Plimon, MD¹, Afshin Assadian, MD¹, ¹Department of Vascular and Endovascular Surgery, Wilhelminenspital Vienna, Austria; ² Medical Faculty of the Sigmund Freud University, Vienna, Austria.

Aim

Chimney procedures or parallel grafts (ChEVAR) have been described over the last years as an alternative for fenestrated endovascular aneurysm repair (FEVAR) to treat juxtarenal aortic aneurysms. So far, ChEVAR was an outside instruction for use (IFU) application with different visceral and aortic grafts, often used in emergency situations. Recently, an aortic stent graft system alongside a visceral stent graft has received CE approval to treat juxtarenal aneurysms and aneurysms with short necks. Thus, this appears to be an appealing of the shelf alternative for short neck aneurysms. The aim of this study was to revisit our FEVAR procedures performed with one device – the fenestrated ANACONDA system - at our institution and to assess their aortic morphology for applicability of ChEVAR according to the IFU of the above mentioned system.

Patients and Methods

From April 2013 to February 2017, 109 patients were treated with a fenestrated Anaconda at our institution, 91 were male, 18 were female, mean age was 74+/- 6 years. For all patients in the fenestrated programme at our institution, preoperative CT scans which were used for FEVAR graft planning were measured in all diameters and angles according to the IFU for the Medtronic Endurant stent graft system. Patients included in the study were treated for aortic aneurysm with short necks, juxtarenal aneurysms, thoraco-abdominal aneurysms and dissections as well as Penetrating Atherosclerotic Ulcers (PAU).

Results

Of the 109 patients included in the study, 15 patients had a short (<15 mm) and/or diseased neck, 68 had a juxtarenal aneurysm treated. Eleven patients had a thoraco-abdominal pathology with an additional thoracic stent to generate a healthy landing zone for the FEVAR and 15 patients were re-do cases after failed EVAR (mid- and long-term failure). Of these 109 patients, 20 (18.3) met the IFU of Medtronic Endurant Chimney inclusion criteria: 1 patient with a short neck, 3 patients with a diseased neck, 11 patients with a pararenal aneurysm and 5 patients needing re-do after a failed EVAR.

Conclusion

The CE approved Medtronic Endurant ChEVAR does not appear to be broadly applicable for patients needing a FEVAR to treat their aortic pathologies. Only 18.3% of all patients in our series were eligible for both methods.

09.50 h. – 10.20 h.
HOT TOPICS IN ANGIOLOGY 2

Chairpersons:

Hideyuki Shimizu, MD

Department of Cardiovascular Surgery, Keio University School of Medicine, Tokyo, Japan.

Josef Veselka, MD, PhD, FICA

Professor of Internal Medicine; Member and President-Elect, Board of Directors, International College of Angiology; Editor, *International Journal of Angiology*; Chief, Department of Cardiology, 2nd School of Medicine, Charles University, University Hospital Motol, Prague, Czech Republic.

09.50 In-Hospital Based Outcomes of STEMI after Application of a Regional STEMI Network in the Metropolitan Area of a Developing Country: Iwan Dakota, MD, PhD, FACC, FESC, FICA, Secretary General and Member, Board of Directors, International College of Angiology; Member, Editorial Board, *International Journal of Angiology*; Head, Peripheral Vascular Intervention, Vascular Division, Department of Cardiology and Vascular Medicine, University of Indonesia, School of Medicine, Jakarta, Indonesia; Director of General Affairs and Human Capital, National Cardiovascular Center, Harapan Kita Hospital, Jakarta, Indonesia.

Background

ST-segment elevation myocardial infarction (STEMI) networks are associated with improvement in mortality. Long-term outcomes of STEMI patients in developing countries with STEMI networks are unknown.

Purpose

We evaluated the characteristics of STEMI patients during two different periods (before and half-decade after the establishment of a regional STEMI network) in a high volume primary PCI center in Jakarta, Indonesia.

Methods

A total of 86,489 patients were admitted to the emergency department of an academic tertiary care cardiac hospital from January 2008 to January 2016. We compared the characteristics and outcomes of STEMI patients from two different periods; January 2008 to July 2009 (before application of the network, N=624); and January 2015 to January 2016 (N= 1052). The hospital has coordinated a regional STEMI network since 2010.

Results

Compared with data from 2008/2009, STEMI patients admitted during 2015/2016 had more primary PCI procedures [N=589; (56%) vs. N=176; (28%), p<0.001], lower proportion of non-perfused patients (37% vs. 59%, p<0.001), and shorter median door-to-device (DTD) time (82 vs. 94 minute, p<0.001). The overall in-hospital mortality for STEMI patients was lower during the recent time period (7.1% vs. 9.6%; adjusted odds ratio 0.72, 95% CI 0.50 to 1.03, p=0.07).

Conclusion

The STEMI network implemented a few years ago in the region has resulted in improvement of processing the care of patients with STEMI, leading to a reduction of in-hospital mortality.

10.05 Emerging Model of Cardiothoracic Surgical Training: Challenges and Opportunities: Siby P. Saha, MD, MBA, FICA, Professor of Surgery and Bioengineering; Member, Board of Directors and Scientific Committee, International College of Angiology and Member, Editorial Board, *International Journal of Angiology*; Chief, Division of Cardiovascular and Thoracic Surgery, University of Kentucky, Lexington, Kentucky, USA.

10.20 h. – 10.30 h. — BREAK
Exhibition Hall 7F

Tuesday, 21 August 2018

10.30 h. – 11.40 h.

ORAL SESSION 3

CORONARY, VEINS, ETC.

*Chairpersons:***Hiroyuki Ishibashi, MD**

Second Department of Surgery, Aichi Medical University, Aichi, Japan.

Otmar M. Pachinger, MD, FESC, FAHA, FICAProfessor Emeritus, Distinguished Professor of Cardiology, Medical University of Innsbruck, Innsbruck, Austria; Member, Board of Directors, International College of Angiology; Chairperson, Scientific Committee, International College of Angiology; Senior Editor, *International Journal of Angiology*; President, Austrian Heart Foundation, Innsbruck, Austria.

10.30 Results of Open and Endovascular Surgery for the Treatment of Renal Artery Aneurysms: Yuri Murakami, MD, Masamichi Momose, MD, Makiko Omori, MD, Reo Takizawa, MD, Takeshi Baba, MD, Masayuki Hara, MD, Koji Maeda, MD, PhD, Hiromasa Tachihara, MD, Takao Ohki, MD, PhD, FICA, Professor of Surgery: ³Member, Board of Directors, International College of Angiology; Editor, *International Journal of Angiology*; Chairman, Department of Surgery and Professor and Chief; Division of Vascular Surgery, Jikei University School of Medicine, Tokyo, Japan.

Objective: Owing to the increased usage of imaging modalities, visceral aneurysm is encountered with increased frequency. In this study, we retrospectively evaluated the outcomes of renal artery aneurysms (RAA).

Method: Between March 2007 and April 2018, invasive treatment for renal artery aneurysms was performed in 53 patients. We retrospectively evaluated the outcomes of open surgical repair (OSR) and endovascular therapy (EVT) for RAA. Basically, an aneurysm that involved the major branches were treated with OSR, whereas an aneurysm capable of securing a landing zone without sacrificing a major branch vessel were treated with EVT. Data was gathered from a prospectively entered data base as well as medical chart review.

Results: OSR and EVT were performed in 31 (58.5%) and 22 patients (41.5%), respectively. The mean age was 57.7 years old with no significant difference between OSR and EVT. Six patients (11.3%) presented as symptomatic aneurysm including abdominal pain and the remainder were asymptomatic. Five patients (16.1%) that underwent OSR had bilateral aneurysms. No significant difference in sac diameter was observed between OSR and EVT. There were no difference in co-morbidities including preoperative creatinine levels among two groups. Among EVT group, coil embolization was performed in 15 patients (68.2%), coil embolization combined with bare metal stent in 1(4.5%), and stent graft in 6 (27.3%). Mean operative time, blood loss, and hospital stay were significantly higher in OSR compared with EVT (P <0.005). In contrast, fluoroscopic time and volume of contrast agent were significantly higher in EVT (P <0.05). The 30-day mortality was 0% in both groups. A rise of more than 30% of preoperative creatinine level was not observed after EVT but was seen in 3 patients after OSR. However, no hemodialysis was required in any cases. Secondary intervention was performed in 1 case of OSR (3.2%). Overall survival rate and freedom from aneurysm related death rate at long term period were 100% in both groups.

Conclusions: The outcomes of surgery for RAA were excellent. Our strategy for the treatment of RAA seems to be reasonable.

Tuesday, 21 August 2018
CORONARY, VEINS, ETC. (Continued)

10.40 The Interplay of AGE-RAGE Axis in Coronary Stent Restenosis: A Prospective Study: Erick D. McNair, PhD, FICA, Naorin Islam, MSc, Rhonda Bryce, MD, Colin Pearce, MD, Department of Pathology and Laboratory Medicine, College of Medicine, University of Saskatchewan, Saskatoon, Saskatchewan, Canada.

Background

Coronary in-stent restenosis (ISR) remains a major adverse outcome for the long-term success for percutaneous coronary intervention (PCI). Although drug eluting stents (DES) have significantly attenuated the incidence and prevalence of ISR, it still occurs in approximately 10% of patients. DES requires the prolonged use of dual antiplatelet drugs to avoid stent thrombosis. The interaction of advanced glycation end products (AGE) and receptors for advanced glycation end products (RAGE) has been implicated in balloon injury and de-endothelialization-induced neointimal hyperplasia in animal models. Subsequent treatment with soluble receptors for advanced glycation end products (sRAGE) decreased neointimal hyperplasia-induced by balloon injury and de-endothelialization in animal models. Reactive oxygen species (ROS) are produced by various sources during and post-PCI. The radial forces exerted on the arterial wall from balloon inflation and stent deployment induce the generation of vascular ROS that may play a role in post-PCI changes, including restenosis, stent thrombosis and endothelial dysfunction. Taken together, PCI, endothelial injury, sRAGE, AGE, and ROS appear to predict the development of post-PCI restenosis. We hypothesize that post-PCI ISR is associated with low serum levels of sRAGE, high serum levels of AGE, and high AGE/sRAGE ratios. Furthermore, we expect a positive correlation between serum levels of AGE and AGE/sRAGE with oxidative stress (MDA) and a negative correlation between serum levels of sRAGE and MDA. We also question if these associations depend on stent type and will explore possible differences by stent type subgroups.

Objectives

This study aimed to correlate the pre-and 6-month post-percutaneous coronary intervention (PCI) serum concentrations of advanced glycation end products (AGE) and soluble receptors for advanced glycation end products (sRAGE), the AGE/sRAGE ratio, and serum malondialdehyde (MDA) levels with in-stent restenosis (ISR) among patients receiving either a drug eluting stent (DES) or a bare metal stent (BMS).

Methods

Sixty consecutive non-diabetic, Caucasian, male patients, diagnosed with a non-ST-elevation myocardial infarction who received either a DES (n=30) or BMS (n=30) via PCI were enrolled. Baseline levels of serum AGE, sRAGE, AGE/sRAGE ratios, MDA, and angiographic parameters were determined at stenting and at six months follow-up. Patients with and without restenosis at six months were compared on both baseline and six month biomarker levels; these comparisons of sRAGE and MDA levels were also undertaken within stent types.

Results

Pre-PCI serum AGE levels and AGE/sRAGE ratios were higher in ISR patients compared to Non-ISR patients, while the pre-PCI and post-PCI serum sRAGE levels were lower in ISR patients compared to Non-ISR patients. The pre- and post-PCI levels of MDA were also higher in ISR patients. Comparing stent types, relative levels of MDA between those with and without stenosis at the respective time, points were similar although changes between time points appeared type-specific.

Conclusion

Post-PCI restenosis correlates with low serum values of sRAGE and high serum values of AGE, MDA and AGE/sRAGE ratio, which are present at stenting. The associations of baseline sRAGE and MDA levels with restenosis outcome appears consistent between stent types.

Tuesday, 21 August 2018
CORONARY, VEINS, ETC. (Continued)

10.50 Internal Jugular Venous Flow in Cerebral Small Vessel Disease: A Study on White Matter Hyper-intensities and Cognitive Dysfunction: Zulfa Indah K. Fadhly, MD¹, Salim Harris, MD, PhD¹, Diatri Nari Lastri, MD¹, Benny Zulkarnaen, MD², Joedo Prihartono³, Departments of ¹Neurology, ²Radiology, ³Public Health, Faculty of Medicine, University of Indonesia and Dr. Cipto Mangunkusumo National Referral Hospital, Jakarta, Indonesia.

Background: *Cerebral Small Vessel Disease* (CSVD) is a subtype of ischemic stroke with the highest prevalence (45%).^{1,2} It affects blood vessels < 50 µm in diameter.³ The most common clinical manifestations of CSVD is cognitive dysfunction (45%). On MRI examination, one of the most common CSVD lesions is *white matter hyper intensities* (WMH).⁴ WMH is known to be associated with internal jugular vein (IJV) flow abnormalities.⁵ Studies of IJV flow profile in CSVD have not been performed.

Objectives: The aim of this study is to assess the flow and velocity of the IJV in CSVD.

Methods: Cross-sectional studies of 40 CSVD patients with cognitive dysfunction and WMH lesion on MRI examination. The cognitive instruments used are MoCA-Ina, TMT-A, TMT-B and *Grooved Peg Board*. WMH is classified based on the Fazekas scale. Bilateral IJV flow examination was performed using *Doppler* Ultrasound at supine (0°) and standing (90°). The parameters assessed are the cross-sectional area, flow and velocity. For further analysis, the results of IJV flow in CSVD are compared with previous studies on healthy volunteers.⁶

Results: A total of 40 subjects with the average age of 60.8 + 9.0 years participated in the study. Impaired cognitive domains are memory, psychomotor, and executive function. The majority of lesional degrees are Fazekas 1 (67.5%). The cross-sectional area of the bilateral IJV are smaller at standing ($p < 0.001$), while the velocity is higher ($p < 0.001$). The flow at supine is higher than at standing ($p < 0.001$). When compared with the study on healthy volunteers, CSVD patients had a larger IJV cross-sectional area, higher flow and velocity both at supine and standing ($p < 0.001$).

Conclusions: IJV flow increases in CSVD.

References:

1. Harris S, Kurniawan M, Rasyid A, et al. *Cerebral Small Vessel Disease in Indonesia: Lacunar Infarction Study from Indonesian Stroke Registry 2012 - 2014*. 2017.
2. Badan Penelitian dan Pengembangan Kesehatan. Riset Kesehatan Dasar (RISKESDAS) 2013. *Lap Nas 2013* 2013; 1–384.
3. Pantoni L. Definition and classification of small vessel diseases. In: *Cerebral Small Vessel Disease*. 2011, pp. 1–3.
4. DeBette S, Markus HS. The clinical importance of white matter hyperintensities on brain magnetic resonance imaging: systematic review and meta-analysis. *Bmj* 2010; 341: 1–9.
5. Zamboni P, Galeotti R, Menegatti E, et al. Chronic cerebrospinal venous insufficiency in patients with multiple sclerosis. *J Neurol Neurosurg Psychiatry* 2009; 80: 392–399.
6. Ciuti G, Righi D, Forzoni L, et al. Differences between internal jugular vein and vertebral vein flow examined in real time with the use of multigate ultrasound color doppler. *Am J Neuroradiol* 2013; 34: 2000–2004.

Tuesday, 21 August 2018
CORONARY, VEINS, ETC. (Continued)

11.00 Rivaroxaban for Managing Recurrent Venous Thromboembolism in Venous Filter Thrombosis and Malignancy: Yeo Zhi Ta Alan¹, Nicole Kiren Cheong Wen Xian¹, Ashish Anile Sule, MBBS, MD, MRCP, FICA, FAMS, FRCP², ¹Yong Loo Lin School of Medicine, National University of Singapore, Singapore; ²Department of General Medicine, Vascular Medicine and Hypertension, Tan Tock Seng Hospital, Singapore.

Background: Malignancy is a well-studied risk factor in the development of recurrent venous thromboembolism (VTE) with an annual risk of 21-27%.¹ Currently, low molecular weight heparin (LMWH) is the gold standard for long-term anticoagulation management of acute VTE in malignancy. With the introduction of novel oral anticoagulants (NOACs), several trials have been done to study the use of NOACs in the treatment of recurrent VTE in on-cancer patients, but very few have been done in cancer patients. A recent meta-analysis² with a subgroup analysis reported the incidence of recurrent VTEs in cancer patients to be 3.9% in patients on NOACs compared to 6.0% with standard therapy (LMWH). However, there are no randomized controlled trials (RCTs) performed specifically to evaluate the use of NOACs in treating recurrent VTEs for solid organ malignancy patients.

Objectives: This case report aims to highlight a successful example of using NOACs such as rivaroxaban to treat recurrent VTE in patients with solid organ malignancy as an alternative to LMWH.

Methods: We describe the case of a 56-year old woman with a history of Stage 4 breast cancer and recurrent VTE despite an inferior vena cava (IVC) filter placement, and who declined LMWH due to the difficulty in performing self-injections. The patient was started on 15mg of rivaroxaban daily for a total of 18 months.

Results: Over the total follow-up period of 18 months, there were no occurrences of new VTE or major bleeding. D-dimer trends also remained stable, ranging from 0.28-0.64.

Conclusion: This case report illuminates the possibility of using rivaroxaban for recurrent VTE in solid organ malignancy with IVC filter thrombosis, indicating the need for further trials.

References

¹Hutten BA, Prins MH, Gent M, Ginsberg J, Tijssen JG, Buller HR (2000) Incidence of recurrent thromboembolic and bleeding complications among patients with venous thromboembolism in relation to both malignancy and achieved international normalized ration: a retrospective analysis. *J Clin Oncol Off J Am Soc Clin Oncol* 18:3078-3083.

²Vedovati MC, Germini F, Agnelli G, Becattini C (2015) Direct oral anticoagulants in patients with VTE and cancer: a systemic review and meta-analysis. *Chest* 147:475-483.

Tuesday, 21 August 2018
CORONARY, VEINS, ETC. (Continued)

11.10 Novel Oral Anticoagulants for Managing Recurrent Venous Thromboembolism in Malignancy—A Case Series: Benedict Cesar I. Azucena, MD², Nicole Kiren Cheong Wen Xian, MBBS¹, Yeo Zhi Ta Alan, MBBS¹, Ashish Anile Sule, MBBS, MD, MRCP, FICA, FAMS, FRCP², ¹Yong Loo Lin School of Medicine, National University of Singapore, Singapore; ²Department of General Medicine, Vascular Medicine and Hypertension, Tan Tock Seng Hospital, Singapore.

Background: Malignancy is a well-studied risk factor in the development of recurrent venous thromboembolism (VTE) with an annual risk of 21-27%.¹ Currently, low molecular weight heparin (LMWH) is the gold standard for long-term anticoagulation management of recurrent VTE in malignancy. With the introduction of novel oral anticoagulants (NOACs), several trials have been studied the use of NOACs in the treatment of recurrent VTE in on-cancer patients, but very few have been done in cancer patients. A recent meta-analysis² with a subgroup analysis reported the incidence of recurrent VTEs in cancer patients to be 3.9% in patients on NOACs compared to 6.0% with standard therapy (LMWH). Currently, randomized controlled trials have yet to be conducted to specifically evaluate the usage of NOACs to treat recurrent VTE in patients with cancer.

Objectives: This case series proposes that NOACs may be a comparable alternative to LMWH in the treatment of recurrent VTE in malignancy, highlighting two such examples of successfully using NOACs as long-term anticoagulation for two breast cancer patients with recurrent VTEs.

Methods: We reviewed two cases of patients with a background of breast cancer, who presented with recurrent VTE and were initially started on LMWH for long-term anticoagulation. However, owing to difficulties in LMWH administration, they were switched to NOACs – 6 months of apixaban and 18 months rivaroxaban respectively.

Results: There were no incidences of VTE over the mean follow-up period of 12 months. There were also no occurrences of major bleeding in either patient.

Conclusion: This case series illuminates the possibility of using NOACs for recurrent VTE in solid organ malignancy, indicating the need further trials.

References

¹Hutten BA, Prins MH, Gent M, Ginsberg J, Tijssen JG, Buller HR (2000) Incidence of recurrent thromboembolic and bleeding complications among patients with venous thromboembolism in relation to both malignancy and achieved international normalized ration: a retrospective analysis. *J Clin Oncol Off J Am Soc Clin Oncol* 18:3078-3083.

²Vedovati MC, Germini F, Agnelli G, Becattini C (2015) Direct oral anticoagulants in patients with VTE and cancer: a systemic review and meta-analysis. *Chest* 147:475-483.

Tuesday, 21 August 2018
CORONARY, VEINS, ETC. (Continued)

11.20 Status of Cardiovascular Medicine Associated with Commercial and Recreational Underwater Diving:
Thomas F. Whayne, Jr., MD, PhD, FICA, Professor of Medicine (Cardiology); Vice President, International College of Angiology; Gill Heart Institute, University of Kentucky, Lexington, Kentucky, USA.

Purpose: Underwater diving has critical commercial applications as well as economic importance for the recreational dive industry, whose participants avidly support, relax with, and benefit from this exciting activity. However, the value and excitement come with significant cardiovascular (CV) risk, awareness of which began during construction of the Brooklyn Bridge. Increased understanding of that CV risk, how to decrease it, and how to manage problems that occur with underwater diving are the combined purpose of this presentation.

Materials and Methods: Understanding by the medical care provider (MCP) of the CV risks of underwater diving, how to advise their patients when advice is sought, and how to deal with unfortunate events, where correct decisions can be lifesaving or critical in avoiding permanent disability, are essential. Basic CV physiology of underwater diving is considered along with discussion of possible problems, how to avoid them, and how to facilitate best available emergency treatment.

Results: The major CV risks associated with underwater diving are air embolism and decompression sickness (DCS); both involve air bubbles in the CV system, large ones in the case of air embolism and very small ones in the case of DCS. Rapid diagnosis is facilitated by knowledge of the dive just like a medical history. This then leads to prediction of probable associated CV problems. Key immediate and usually available early steps are the administration of 100% oxygen and rehydration with intravenous (IV) normal saline. Subsequently and as soon as arrangements can be made, both air embolism and DCS require hyperbaric oxygen therapy (HBOT) with placement of the victim in a hyperbaric recompression chamber. HBOT at 1.5 atmospheres absolute for 60 minutes appears safe and not associated with oxygen toxicity. Other measures not well-backed by evidence-based medicine include IV perfluorocarbon emulsion, steroids, platelet inhibitors, and statins.

Conclusion: Timely diagnosis of diving emergencies requires significant understanding of CV physiology by the MCP and rapid application of that knowledge is critical to patient well-being.

Tuesday, 21 August 2018
CORONARY, VEINS, ETC. (Continued)

11.30 Aortic Wall Enhancement—Possibility of a New Prognostic Indicator: Eisaku Ito, MD¹, Naoki Toya, MD, FICA¹, Soichiro Fukushima, MD¹, Takeyuki Misawa, MD², Takao Ohki, MD, PhD, FICA³, Professor of Surgery; ¹Department of Surgery, Division of Vascular Surgery, The Jikei University Kashiwa Hospital, Tokyo, Japan; ²Department of Surgery, The Jikei University Kashiwa Hospital, Tokyo, Japan; ³Member, Board of Directors, International College of Angiology; Editor, *International Journal of Angiology*; Chairman, Department of Surgery and Professor and Chief, Division of Vascular Surgery, Jikei University School of Medicine, Tokyo, Japan.

Purpose

Endoleaks after endovascular aneurysm repair (EVAR) for abdominal aortic aneurysm (AAA) results in aneurysm expansion. However, prediction of aneurysm shrinkage remains difficult. Aneurysm wall enhancement (AWE) in a cerebral aneurysm is a known predictor for expansion/rupture. However, it is unknown whether AWE is associated with aneurysm growth after EVAR. We retrospectively assessed the relationship between AWE and AAA growth.

Materials and Methods

From August 2011 to July 2016, data on 176 EVAR's for AAA were retrospectively collected. AWE was defined as an increase of more than 20 Hounsfield units (HUs) in mean CT values when images in delayed enhanced scans were compared with those in unenhanced scans. The primary endpoint was aneurysm expansion and shrinkage (> 5mm).

Results

There were 127 men (80.9%) and median age was 75 years (45-93) old. The median follow-up period after EVAR was 23.6 months (6-59). There were 62 cases with aneurysm shrinkage after EVAR, 63 cases with stable aneurysm size, and 32 cases with aneurysm expansion. In the AWE negative group, there were 29 cases (28.2%) with aneurysm shrinkage and 26 cases (25.2%) with expansion. On the other hand, in the AWE positive group, there were 33 cases (53.2%) with aneurysm shrinkage and 6 cases (18.8%) with expansion. (Chi-square test: $p < 0.001$)

Conclusion

AWE may play an important role in aortic surgery as a new prognostic predictor.

•
11.40 h. – 11.50 h. — BREAK

Exhibition Hall 7F

•
11.50 h. – 12.40 h.

LUNCHEON SEMINAR 2

(Co-Sponsored by Sumitomo Bakelite Co., LTD.)

Chairpersons:

Takao Ohki, MD, PhD, FICA

Professor of Surgery; Member, Board of Directors International College of Angiology; Editor, *International Journal of Angiology*; Chairman, Department of Surgery and Professor and Chief, Division of Vascular Surgery, Jikei University School of Medicine, Tokyo, Japan.

•
Reo Takizawa, MD

Department of Surgery, Division of Vascular Surgery, Jikei University School of Medicine, Tokyo, Japan.

Sung Gwon Kang

S & G BIOTECH, Inc.

•
12.40 h. – 12.50 h. — BREAK

Exhibition Hall 7F

Tuesday, 21 August 2018

12.50 h. – 14.20 h.

SYMPOSIUM 3

TAA

Chairpersons:**Ikuo Fukuda, MD, PhD**

Thoracic and Cardiovascular Surgery, Hirosaki University Graduate School of Medicine, Hirosaki, Aomori, Japan.

Jürgen Falkensammer, MD, FICA

Vice President, Scientific Council, International College of Angiology, Department of Vascular and Endovascular Surgery, Wilhelminenspital Vienna, Austria; Medical Faculty of the Sigmund Freud University, Vienna, Austria.

Commentators:**Yukio Obitsu, MD**

International University of Health and Welfare Hospital, Tokyo, Japan.

Tomoyasu Sato, MD

Department of Interventional and Diagnostic Radiology, Tsuchiya General Hospital, Hiroshima, Japan.

Naoki Hayashida, MD

Department of Cardiovascular Surgery, Chiba Cardiovascular Center, Ichihara-city, Chiba, Japan.

Kinya Matsui, MD

Director, Cardiovascular Surgery, Ogasawara Memorial Sapporo Hospital, Hokkaido, Sapporo, Japan.

12.50 Four Reasons we should Intervene Earlier with Ascending Aortic Aneurysms: John A. Elefteriades, MD, FACS, FICA, William W.L. Glenn Professor of Cardiothoracic Surgery; Second Vice Chairman and Member, Board of Directors, International College of Angiology; Co-Chairperson, Scientific Committee, International College of Angiology; Editor-in-Chief, *International Journal of Angiology*; Director, Aortic Institute at Yale-New Haven, Yale University School of Medicine, New Haven, Connecticut, USA.

13.05 Effect of Stroke Prevention Techniques in Hybrid Aortic Arch Repair: Masaaki Kato, MD, Department of Cardiovascular Surgery, Morinomiya Hospital, Osaka, Japan.

13.20 Proximal Bare Stent May Reduce Bird-Beak Configuration which is Associated with Distal Migration of Stent Grafts in the Aortic Arch: Hiroshi Banno, MD, Department of Surgery, Division of Vascular Surgery, Nagoya University Hospital Graduate School of Medicine, Nagoya, Japan.

13.35 Surgical Intervention after TEVAR: Strategy and Outcomes—Tokyo Medical University-Cardiovascular Surgery: Hitoshi Ogino, MD, PhD, Department of Cardiovascular Surgery, Tokyo Medical University Hospital, Tokyo, Japan.

13.50 Double Barrel Stent Graft to Shorten Aortic Coverage in Endovascular Treatment of Thoracoabdominal Aneurysm (TAAA): Piotr M. Kasprzak, MD, Kyriakos Oikonomu, MD, Wilma Schierling, MD, Karin Pfister, MD, Department of Vascular Surgery, University Medical Center Regensburg, Regensburg, Germany.

Purpose: To report the early experience with a new, custom-made, thoracic reduction stent graft (2-in-1-stent graft, Cook®) to shorten coverage of the thoracic aorta in patients who need off-the-shelf branched stent graft (T-branch, Cook®) for exclusion of thoraco-abdominal aortic aneurysms (TAAAs) with additional seal in the descending aorta >30mm.

Materials and Methods: The double barrel 2-in-1 stent graft is an in-folded stent graft consisting of an external and an internal part with different diameters (outer diameter between 38 and 44mm, inner diameter 32mm). Length of the 2-in-1 stent graft is 69 - 84 mm compared to 160 - 200 mm of a standard tapered stent graft.

Results: From January 2015 to December 2017, 10 patients (8 male, 2 female, mean age 73 years) were treated electively for TAAAs with a custom-made 2-in-1 stent graft and a T-branch device. Implantation of the 2-in-1-stent graft was successful in all patients achieving sufficient seal with a considerable reduction of the aortic coverage compared to a standard reducing device. Proximal sealing to the aortic wall and the T-branch device was excellent. No endoleak was detected due to the 2-in-1 stent graft. There were two Type II- and one Type Ic (due to renal side-branch) endoleak. No spinal cord injury (SCI) occurred peri-operatively and until patients were discharged.

Conclusions: The new, in-folded double barrel 2-in-1 stent graft allows considerable shortening of coverage of the thoracic aorta. This might be a worthwhile alternative to reduce the risk for SCI especially in electively treated patients with a diameter of more than 30 mm in the sealing zone for the T-branch.

Tuesday, 21 August 2018
SYMPOSIUM 3 (Continued)
TAA

14.05 Segmental Artery Coil Embolization prior to Extensive Thoracic and Thoracoabdominal Endovascular Aortic Repair: **Takashi Murakami, MD, PhD**, Akimasa Morisaki, MD, PhD, Hiromichi Fujii, MD, PhD, Yosuke Takahashi, MD, PhD, Yoshito Sakon, MD, Kokoro Ymane, MD, Noriaki Kishimoto, MD, Toshihiko Shibata, MD, PhD, Department of Cardiovascular Surgery, Osaka City University Graduate School of Medicine, Osaka, Japan.

Background

Spinal cord injury (SCI) is a catastrophic complication after thoracic and thoracoabdominal aortic repair. Recently, prevention of SCI by pre-operative pre-conditioning with segmental artery coil embolization (SACE) was reported in a limited case series.

Objectives

A retrospective review our experiences of SACE to explore its utility, feasibility and safety.

Methods

All patients who underwent pre-operative SACE prior to thoracic and thoracoabdominal endovascular aortic repair from October 2015 to May 2018 were reviewed for analysis. Patients who were deemed to have a relatively high risk of SCI were indicated for SACE. CT angiogram was performed and target segmental arteries were selected. During SACE, when the angiogram of each target segmental artery revealed anterior spinal artery, a balloon occlusion test was performed to prevent SCI induced by this procedure. Definitive repair of this aortic pathology was performed at least 4 weeks after the SACE.

Results

There were 9 patients eligible for this study. Mean age was 72 years old and all patients were male. Two patients were diagnosed with thoracoabdominal aortic pathology and 7 as extensive thoracic aortic pathology, including one case of chronic aortic dissection and the others of true aneurysm. The most distal end of the stent graft coverage was Th 8 in one, Th 11 in 4, Th 12 in 2, and L2 in 2 patients. Most patients had multiple co-morbidities, such as aortic atheroma, previous open aortic repair and old myocardial infarction. The number of patent segmental arteries was from 2 to 16 (Median 4). The number of targeted segmental arteries for embolization were 2 to 8 (median 4). Reasons to avoid coil embolization were; (1) 19 SAs located proximal aorta, (2) 24 SAs adjacent to the atheroma or mural thrombus and (3) 2 SAs were anatomically difficult. One targeted segmental artery was not embolized due to the technical difficulties, and the others were successfully done. Anterior spinal artery from the embolized segmental artery was found in 4 patients. A procedure-related complication was a temporary contrast induced nephropathy in one patient. Complete repair was performed in 8 patients without paraplegia.

Conclusion

SACE prior to TEVAR was safely performed in carefully selected target segmental arteries. Real impact on prevention for SCI needs to be clarified in the future study.

•
14.20 h. – 15.10 h.
TEATIME SEMINAR 2
(Co-Sponsored by Japan Lifeline Co., LTD.)
Chairperson:

Hideaki Obara, MD, FICA

Department of Surgery, Keio University School of Medicine, Tokyo, Japan.

•
Features and Utilities of AFX2 Stent Graft System: **Hiroshi Banno, MD**, Department of Surgery, Division of Vascular Surgery, Nagoya University Graduate School of Medicine, Nagoya, Japan.

In-Vitro Evaluation of Suitable Proximal Neck Length for Snorkel EVAR with AFX Infra-renal Cuff System: **Kenjiro Kaneko, MD**, Department of Vascular Surgery, Shin-yurigaoka General Hospital, Komae, Japan.

•
15.10 h. – 15.25 h. — BREAK
Exhibition Hall 7F

Tuesday, 21 August 2018

15.25 h. – 16.10 h.

SYMPOSIUM 4

CRITICAL LIMB ISCHEMIA

Chairpersons:**Kimihiko Komori, MD**

Department of Surgery, Division of Vascular Surgery, Nagoya University Graduate School of Medicine, Nagoya, Japan

Jackie P. Ho, MBBS, FRCS, FCS, FHKAM

Associate Professor, Department of Surgery, Yong Loo Lin School of Medicine, National University of Singapore, Singapore; Consultant, Department of Cardiac, Thoracic and Vascular Surgery, National University Heart Center, Singapore.

Commentators:**Shin Ishimaru, MD**

Director, Center for Endovascular Therapy, Toda Chuo General Hospital, Saitama, Japan.

Yoshinori Inoue, MD

Director, Ambulatory Vascular Surgical Clinic, Tokyo, Japan.

Hiroyoshi Komai, MD

Professor, Unit of Peripheral Vascular Surgery, Department of Surgery, Kansai Medical University, Takii Hospital, Osaka, Japan.

Yoichi Nozaki, MD

Hokko Memorial Hospital, Hokkaido, Japan.

15.25 Treatment Strategy for Critical Limb Ischemia—How to Select Open Surgery or Endovascular Treatment:**Nobuyoshi Azuma, MD, FICA**, Professor and Chairman, Department of Vascular Surgery, Asahikawa Medical University, Asahikawa, Japan; Vice President, Scientific Council, International College of Angiology; Editor, *International Journal of Angiology*.**15.40 Autogenous Stem Cells for Critical Limb Ischemia—Technique and Results: Randall W. Franz, MD, FACS,****FICA, RVT, RPVI**, Chief, Vascular and Endovascular Surgery, Medical Director, Grant Vascular and Vein Center; Assistant Professor of Surgery, Ohio State University; Professor of Surgery, Ohio University, Columbus, Ohio, USA; First Vice Chairman and Member, Board of Directors, International College of Angiology; Co-Chairperson, Scientific Committee, International College of Angiology; Editorial Board, *International Journal of Angiology*; Kaushal J. Shah, MD, FACS, RPVI, Richard H. Pin, MD, FACS, RPVI, Thomas Hankins, CCP, Jodi F. Hartman, MS, Michelle L. Wright, MPH; Columbus and Westerville, Ohio, USA; Camp Hill, Pennsylvania, USA; Dartmouth, Massachusetts, USA.**Objective:** This study was conducted to determine if intra-muscular and intra-arterial stem cell injections delay or prevent major limb amputations, improve ankle-brachial index measurements, relieve rest pain, and improve ulcer healing.**Methods:** A prospective case series with interventions occurring between December 2007 and September 2012 and a 3-month minimum follow-up was conducted at an urban tertiary care referral hospital. Patients with severe limb threatening peripheral arterial disease, without other options for revascularization, were eligible for enrollment. Dual intramuscular and intra-arterial injection of bone marrow mononuclear cells harvested from the iliac crest was performed. Major limb amputation at 3 months was the primary outcome measure. Secondary outcome measures included ankle brachial index measurements, rest pain, and ulceration healing. Kaplan-Meier survivorship was performed to ascertain overall survivorship of the procedure.**Results:** No complications related to the procedure were reported. Of 49 patients (56 limbs) enrolled, two patients (two limbs) died, but had not undergone major amputation, and five limbs (8.9%) underwent major amputation within the first 3 months. Three-month follow-up evaluations were conducted on the remaining 49 limbs (42 patients). Median post-procedure revised Rutherford and Fontaine classifications were significantly lower compared with median baseline classifications. After 3 months, seven patients (nine limbs) died but had not undergone major amputation, and seven limbs (14.3%) underwent major amputation. At a mean follow-up of 18.2 months, the remaining 33 limbs (29 patients) had not undergone a major amputation. Freedom from major adverse limb events (MALE) was 91.1% (95% confidence interval, 79.9-96.2) at 3 months and 75.6% (95% confidence interval, 59.4-86.1) at 12 months.**Conclusions:** This procedure was designed to improve limb perfusion in an effort to salvage limbs in patients for whom amputation was the only viable treatment option. The results of this analysis indicate that it is an effective strategy for limb salvage for patients with severe peripheral arterial disease. (*J Vasc Surg* 2015;62:673-80).**15.55 Optimal Endpoint of Below the Knee (BTK) Intervention for Wound Healing: Makoto Utsunomiya, MD,****PhD**, Division of Cardiovascular Medicine, Toho University, Ohashi Medical Center, Tokyo, Japan.

Tuesday, 21 August 2018**16.10 h. – 16.40 h.****PROFESSOR JOHN B. CHANG RESEARCH ACHIEVEMENT AWARD LECTURE****The Road to Conquer Arch Aneurysm*****Introduction By:*****Otmar M. Pachinger, MD, FESC, FAHA, FICA**

Professor Emeritus, Distinguished Professor of Cardiology, Medical University of Innsbruck, Innsbruck, Austria; Member, Board of Directors, International College of Angiology; Chairperson, Scientific Committee, International College of Angiology; Senior Editor, *International Journal of Angiology*; President, Austrian Heart Foundation, Innsbruck, Austria.

Presentation By:**Takao Ohki, MD, PhD, FICA**

Professor of Surgery; Member, Board of Directors International College of Angiology; Editor, *International Journal of Angiology*; Chairman, Department of Surgery and Professor and Chief, Division of Vascular Surgery, Jikei University School of Medicine, Tokyo, Japan.

16.40 h. – 16.50 h.**Lecture Hall 1, 3F****CLOSING CEREMONY****16.50 h. – 17.20 h.****Lecture Hall 1, 3F****ICA BUSINESS MEETING****Officers and Editorial Board Meeting****17.30 h. – 19.00 h.****Exhibition Room, 7th Floor****Jikei University****GALA DINNER**

ACKNOWLEDGMENTS

The International College of Angiology in cooperation with 13th Japan Endovascular Symposium gratefully acknowledges the educational grants provided in support of this CME activity.

Without the support of all of the following companies, this program would not have been possible:



*Creative Technologies
Worldwide*



Canon

CANON MEDICAL SYSTEMS CORPORATION



Medtronic

MEDICO'S
Hirata

**Boston
Scientific**
Advancing science for life™

INNOVA™

Self-Expanding Stent System

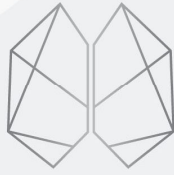The Meaningful
Innovation



販売名：イノーババスキュラーステント
医療機器承認番号：22800BZX00066000

製品の詳細に関しては添付文書等でご確認いただくか、弊社営業担当へご確認ください。
© 2017 Boston Scientific Corporation or its affiliates. All rights reserved.
All trademarks are the property of their respective owners.

ボストン・サイエンティフィック ジャパン株式会社
本社 東京都中野区中野4-10-2 中野セントラルパークサウス
www.bostonscientific.jp
PSST20160322-0308




CERENOVUS

PART OF THE Johnson & Johnson FAMILY OF COMPANIES

CODMAN SPECTRA™

From Start to Finish



CODMAN
SPECTRA™
FAMILY OF COILS

DELTA X SFT™
microcoil

DELTA FILL™
microcoil

MICRUS FRAME™ S
microcoil

MICRUS FRAME™ C
microcoil

depusynthes.jp 製造販売元: ジョンソン・エンド・ジョンソン株式会社 / 販売名: セレサイト マイカスコイル MDC / 承認番号: 22000BZX00973000 / ©J&J K.K. 2017・DSCDV379-01-201716・081817-171006

ETHICON
PART OF THE *Johnson & Johnson* FAMILY OF COMPANIES



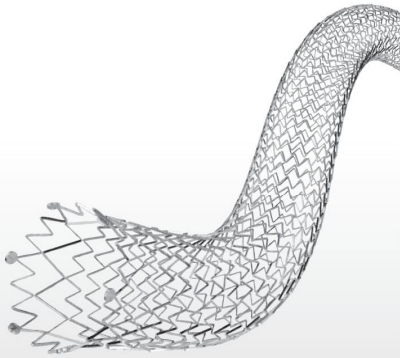
COATED
VICRYL PLUS®

ブレイド抗菌縫合糸

PDS PLUS®

モノフィラメント抗菌縫合糸

TOTAL SOLUTION FOR PERIPHERAL VASCULAR



LIFESTENT[®] SOLO[™]
Vascular Stent System



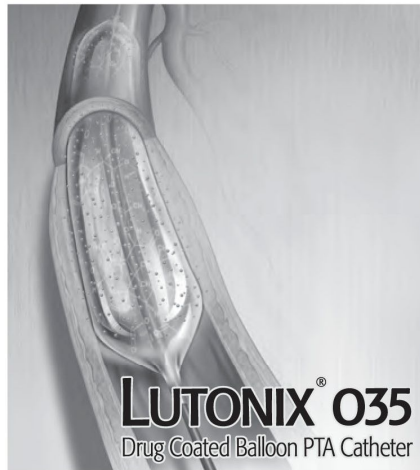
CROSSER[®]
CTO Recanalization Catheter




E-LUMINEXX[®]
Vascular Stent



DORADO[®]
PTA Dilatation Catheter




LUTONIX[®] 035
Drug Coated Balloon PTA Catheter



VASCUTRAK[™]
PTA Dilatation Catheter



ULTRAVERSE[®] 035
PTA Dilatation Catheter



ULTRAVERSE[®] RX
PTA Dilatation Catheter



SEEKER[®]
Crossing Support Catheter

※販売名：LIFESTENT SOLO バスキュラステントシステム
 ※販売名：クロッサーシステム
 ※販売名：バード血管用ステント
 ※販売名：DORADO PTAバルーンカテーテル
 ※販売名：Lutonix ドラッグコーティングバルーンカテーテル（大腿膝高動脈用）

承認番号：22800BZX00216000
 承認番号：22200BZX00595000
 承認番号：21400BZX00105000
 承認番号：22600BZX00281000
 承認番号：22900BZX00252000

※販売名：VASCUTRAK PTAバルーンカテーテル
 ※販売名：ULTRAVERSE 035 PTAバルーンカテーテル
 ※販売名：ULTRAVERSE RX PTAバルーンカテーテル
 ※販売名：SEEKER サポートカテーテル

承認番号：22800BZX00156000
 承認番号：22800BZX00127000
 承認番号：22600BZX00277000
 承認番号：22700BZX00300000

・事前に必ず添付文書を読み、本製品の使用目的、禁忌・禁止、警告、使用上の注意等を守り、使用方法に従って正しくご使用ください。
 本製品の添付文書は、独立行政法人医薬品医療機器総合機構（PMDA）の医薬品医療機器情報提供ホームページでも閲覧できます。
 ・製品の仕様・形状等は、改良等の理由により予告なく変更する場合がございますので、あらかじめご了承ください。

・Bard、バード、LUMINEXX、ルミネックス、E-LUMINEXX、イー・ルミネックス、ULTRAVERSE、ウルトラバース、LIFESTENT、ライフセント、CROSSER、クロッサー、DORADO、ドラド、LUTONIX、ルトニクス、SEEKER、シーカーは、C. R. Bard社の登録商標です。



株式会社メディコン 本社 大阪市中央区平野町2丁目5-8
 ☎06(6203)6541(代)



VASSALLO

*Dive into the
EVT World,
Make a Splash!!*

■承認番号：21300BZZ00438000 ■販売名：HB-IVRガイドワイヤー ■特定保険医療材料請求区分：血管造影用ガイドワイヤー/ 微細血管用 ■クラス分類：IV
■製造販売元：フィルメック株式会社
※ 「VASSALLO」は、フィルメック株式会社の日本国及びその他の国における商標又は登録商標です。

Cordis
A Cardinal Health company

【販売元】 Cardinal Health Japan 合同会社
本社 / 〒163-1034 東京都新宿区西新宿3-7-1 新宿パークタワー

Cordis Circle  

ARTIS pheno

As individual as your patients



Cutting-edge
robotic imaging to
drive minimally
invasive procedures

Patients come in all shapes and sizes. Particularly in modern minimally invasive treatment, patient size, condition, or positioning requirements pose significant challenges to imaging systems. In some cases, treatment may even be impossible.

Engineered to be truly patient-oriented, ARTIS pheno® is a unique floor-mounted robotic C-arm system for individualized preprocedural planning, intraoperative

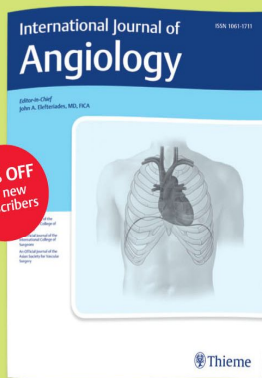
guidance, and immediate checkup – regardless of patient condition or procedure complexity. Furthermore, it also helps you maintain a sterile work environment.

Embrace heterogeneity: no matter how challenging the patient or how demanding the procedure, ARTIS pheno delivers the right images. Improve clinical outcomes and enhance the standing of your institution – with a versatile and intelligent system that adapts to the reality of all your patients.

[siemens.com/artis-pheno](https://www.siemens.com/artis-pheno)

SIEMENS
Healthineers

Please use access code **IJAICA183097357gtS**
to gain free access to the latest issues of IJA for a limited time!




International Journal of Angiology

Editor-in-Chief:
John A. Elefteriades

4 issues p.a., ISSN 1061-1711

Subscribe at www.thieme.com/ija




AORTA

Editor-in-Chief:
John A. Elefteriades

6 issues p.a., ISSN 2325-4637

Submit via
www.editorialmanager.com/aorta



Indian Journal of Cardiovascular Disease in Women

Editor-in-Chief:
Maddury Jyotsna

4 issues p.a., ISSN 2455-7854

Submit via
www.manuscriptmanager.net/ijcdw

Institutional Subscribers esales@thieme.com

Individual Subscribers www.thieme.com



@thiemepublishers



@ThiemeNY



@thieme-group




@thieme.ny

Special introductory rates are only valid for new personal rate subscribers and are limited to the first year of subscription. Orders from individuals must include the recipient's name and private address, and be paid by private funds. Only qualified professionals and students are eligible for personal rate subscriptions.



Stellar journals in thoracic and cardiovascular surgery



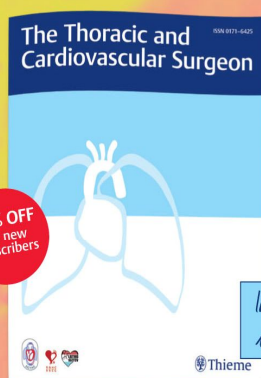
OPEN ACCESS

Journal of Cardiac Critical Care

Editor-in-Chief:
Poonam Malhotra Kapoor

2 issues p.a., ISSN 2456-9224

Submit via
www.manuscriptmanager.net/jccc



20% OFF
for new
subscribers


Indexed
in JCR*

The Thoracic and Cardiovascular Surgeon

Editor-in-Chief:
Markus Heinemann

8 issues p.a., ISSN 0171-6425

Subscribe at www.thieme.com/thoracic



OPEN ACCESS

The Thoracic and Cardiovascular Surgeon Reports

Editor-in-Chief:
Markus Heinemann

ISSN 2194-7643

Submit via
<https://mc.manuscriptcentral.com/tcsreports>

Institutional Subscribers esales@thieme.com

Individual Subscribers www.thieme.com



@thiemepublishers



@ThiemeNY



@thieme-group



@thieme.ny

TPS / 18-077

Special introductory rates are only valid for new personal rate subscribers and are limited to the first year of subscription. Orders from individuals must include the recipient's name and private address, and be paid by private funds. Only qualified professionals and students are eligible for personal rate subscriptions.

*JCR stands for Journal Citation Reports







61st Annual World Congress ICA 2019

International College of Angiology

Save the Date



Columbus, Ohio
October 10-12, 2019
Renaissance Hotel



Join your colleagues from around the world, earn CME, and explore key areas rapidly expanding in cardiovascular medicine and surgery. ICA 2019 is designed to meet the specific educational needs of medical professionals involved with the management and treatment of cardiovascular diseases as they are encountered by primary care physicians, vascular, general, thoracic and cardiovascular surgeons, cardiologists, interventional radiologists, neuroradiologists, fellows and residents of the above specialties, vascular biologists their staff and nurses.

The objective of the Annual World Congress is to offer a serious academic forum to those physicians and allied healthcare personnel interested in research, education and clinical investigation in the field of cardiovascular medicine and surgery. The congress is intended to provide an in-depth review of the spectrum of topics related to the management and treatment of patients with cardiovascular and vascular disease. Special emphasis will be placed upon evolving trends, therapies, and minimally invasive treatment of cardiovascular disease. The ICA is dedicated to establishing educational programs appropriate for practicing physicians and surgeons. The College's aim is to encourage young scientists and clinicians in basic and clinical research through a special forum of a young investigators award program.

This annual world congress will feature an internationally renowned faculty, and recognized leaders will discuss state-of-the-art techniques in the management, diagnosis and treatment of vascular disease. Live video case presentations, didactic lectures, panel discussions, debates and question and answer sessions will highlight the most challenging and controversial topics and procedures performed in interventional medicine. We encourage all of our colleagues to participate in this growing educational program by submission of a formal abstract for a standard oral, poster, or video presentation.

The 2019 program will focus on surgical, percutaneous, and medical management...from peripheral vascular disease to coronary and cerebrovascular disease and abdominal aortic aneurysms. The congress will offer a comprehensive review of what is new in management, techniques, approaches and prevention.

Program Highlights

Advances in Endovascular and Interventional Procedures—Tips and Tricks ■ Carotid Arterial Interventions—CEA vs CAS ■ Advances—Controversies—Latest Concepts in Cardiovascular Medicine and Surgery ■ Debates in Cardiovascular Medicine ■ Up-to-Date Techniques for the Treatment of Peripheral Vascular Disease—Techniques and Results ■ Contemporary Treatment in Venous Disease ■ Thoracic Arch—AAA—Open Procedure vs. Stent vs. Hybrid or Combined? ■ Preventive Cardiology—Atherosclerosis—Risk Management—Prevention and Innovative Alternative Medicines ■ Young Investigator Award Competition ■ Oral, Video, and Poster Presentation Sessions ■ Round Table Discussions

For Additional Information and Abstract Forms, please contact:

International College of Angiology

Email: ica@intlcollegeofangiology.org • Telephone: +802.988.4065 • Fax: +802.988.4066

or

Denise M. Rossignol, Executive Director, International College of Angiology

Email: denisemrossignol@cs.com • ICA Website: <http://www.intlcollegeofangiology.org>

Telephone: +802.988.4065 • Fax: +802.988.4066





Kailash Prasad, MBBS (Hons), MD, PhD, DSc, FRCPC, FACC, FIACS, FICA *Program Chairman*
Prof. Otmar M. Pachinger, MD, FESC, FAHA, FICA, *Chairman, Scientific Committee*
Denise M. Rossignol, BS, *Executive Director*

Prof. Takao Ohki, MD, PhD, FICA, *Chairman, Local Organizing Committee*
Koji Maeda, MD, PhD, *Co-Chairman, Local Organizing Committee*
Jikei University School of Medicine, Tokyo, Japan

Noriko Fujii, N-Practice Co., Ltd., *Local Congress Secretariat*
ICA2018@n-practice.co.jp

International College of Angiology, Inc.
Member, Council for International Organizations of Medical Sciences (CIOMS)
Executive Office: 161 Morin Drive • Jay, Vermont 05859-9283 USA
+802.988.4065 • Fax: +802.988.4066
Email: denisemrossignol@cs.com or ica@intlcollegeofangiology.org
Website: <http://www.intlcollegeofangiology.org>