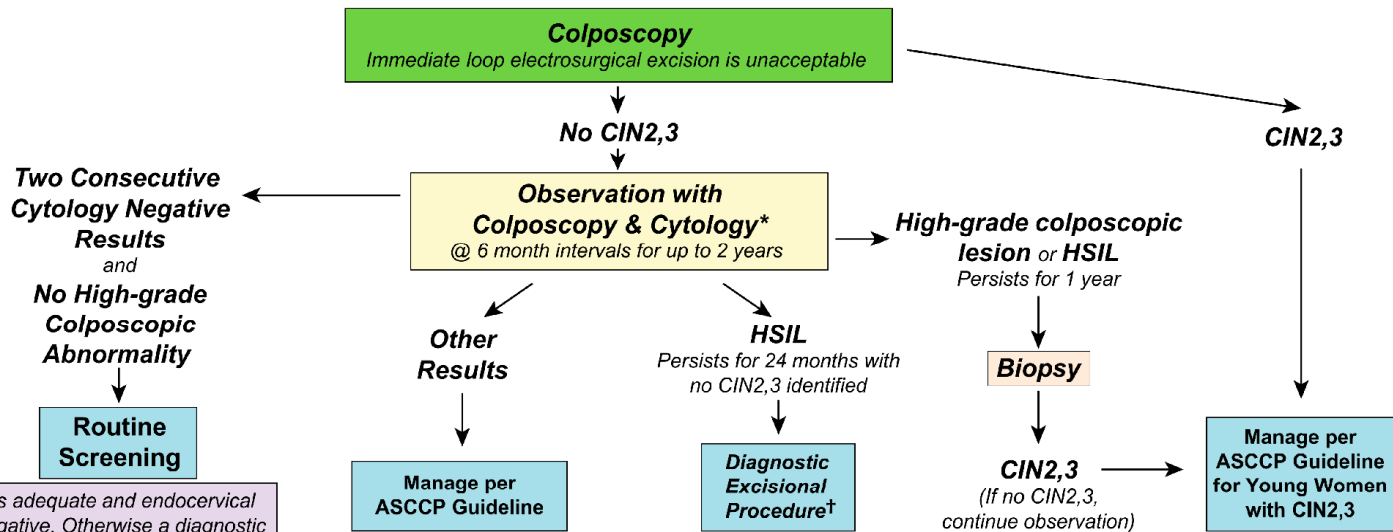


Management of Women Ages 21-24 yrs with Atypical Squamous Cells, Cannot Rule Out High Grade SIL (ASC-H) and High-grade Squamous Intraepithelial Lesion (HSIL)



* If colposcopy is adequate and endocervical sampling is negative. Otherwise a diagnostic excisional procedure is indicated.

† Not if patient is pregnant