

## LETTERS TO THE EDITOR

### Laceration of the eye with a fishing hook

EDITOR.—Perforation of the eye is a challenging emergency in ophthalmology and requires immediate treatment. Visual outcome after penetrating injuries with and without intraocular foreign bodies depends on the visual acuity after injury, age of patient, and the severity of the ocular trauma.<sup>1,2</sup> We report a case of globe laceration following an accident with a fishing hook which was successfully treated without surgery.

#### CASE REPORT

A 12 year old boy presented with visual disturbance and a small lid wound on the left eye at our emergency department. He had been playing with a fishing rod while sitting on a tree, and was trying to hook fruit on the ground. The line recoiled swiftly and pierced the upper lid of the left eye. He jumped from the tree and the hook jerked itself out of the boy's eye. A small wound of the left upper lid was found. The visual acuity was 20/20 in the right eye and 20/25 in the left eye. The anterior segment and the intraocular pressure were normal. The fundus of the right eye was normal. The fundus of the left eye showed a mild localised vitreous haemorrhage superomacular near the temporal vessels. From there the scleral rupture went straight up to the equator. Partly orbital fat could be seen

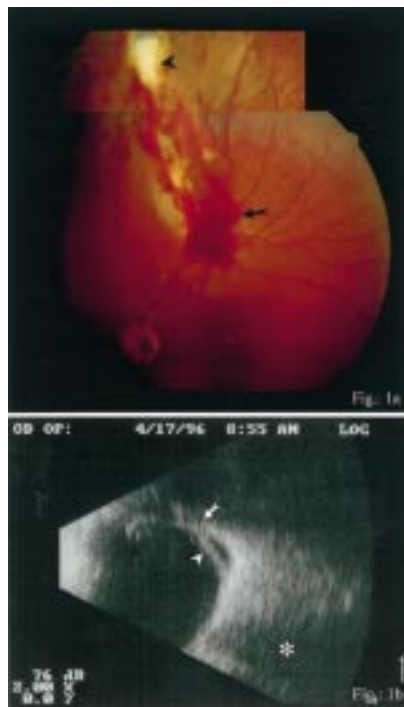


Figure 1 (A) Arrowhead indicates orbital fat in the scleral wound gap. The vitreous haemorrhage is marked with the arrow and the optic nerve head with the asterisk. (B) The arrowhead indicates the detached lamina interna of the vitreous and the arrow shows the area of vitreous incarceration into the scleral wound. The optic nerve is marked with the asterisk.

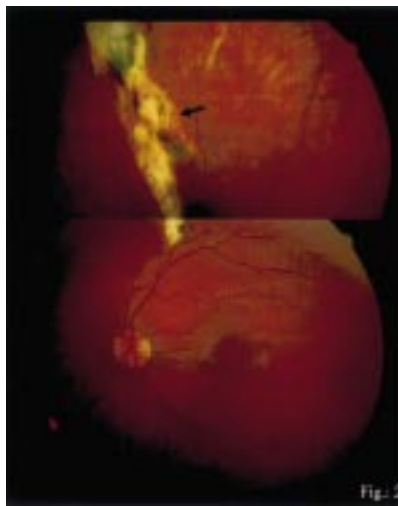


Figure 2 The arrow indicates the huge sclerochorioretinal scar.

through the wound gap (Fig 1A). The ultrasound disclosed a partly detached vitreous with adherence at the site of penetration (Fig 1B). No foreign body was detected by the orbital computed tomograph scan. The patient was admitted to hospital for 8 days and treated with intravenous antibiotics during 1 week followed by an oral antibiotic in the second week. He also received cortisone systemically for 10 days. Three weeks later the visual acuity was 20/20. On funduscopy a sclerochorioretinal scar was disclosed. The edges of the retinal tear were attached and vitreous haemorrhage was completely dissolved (Fig 2). After 1 year of follow up the situation remained unchanged.

#### COMMENT

Although penetrating injuries of the posterior segment often require surgical treatment (that is, pars plana vitrectomy), in this case antibiotic therapy was used in order to prevent an endophthalmitis<sup>3</sup> in combination with orally administered cortisone to reduce the inflammatory reaction. Because of an excellent fundus view, postponing surgery seems to be more appropriate, since surgery implies additional risks (for example, cataract formation, retinal detachment, etc) for the eye.<sup>4-6</sup> Significant predictors for a final visual acuities of 20/50 or better are a visual acuity of 20/800 or better and youth ( $\leq 18$  years).<sup>1</sup> In a mammalian study it was disclosed that simple penetration of the equator with vitreous loss does not lead to retinal detachment.<sup>7</sup> An intact tamponading vitreous at the time of injury seems to prevent fibrous ingrowth due to anti-proliferative effects of the hyalocytes.<sup>8</sup> The findings of this case suggest that surgery is not the first treatment strategy for similar penetrations of the posterior segment.

RALF KROTT  
K ULRICH BARTZ-SCHMIDT  
KLAUS HEIMANN

Department of Vitreoretinal Surgery, University of Cologne, Germany

Correspondence to: Ralf Krott, MD, Department of Vitreoretinal Surgery, University of Cologne, Joseph-Stelzmann-Strasse 9, D-50924 Cologne, Germany.

Accepted for publication 11 June 1999

1 Sternberg P Jr, de Juan E Jr, Michels RG, et al. Multivariate analysis of prognostic factors in penetrating ocular injuries. *Am J Ophthalmol* 1984;98:467-72.

- Negrel AD, Thylefors B. The global impact of eye injuries. *Ophthalmic Epidemiol* 1998;5:143-69.
- Duch-Samper AM, Menezo JL, Hurtado-Sarrio M. Endophthalmitis following penetrating eye injuries. *Acta Ophthalmol Scand* 1997;75:104-6.
- Mietz H, Kirchhof B, Heimann K. Anterior proliferative vitreoretinopathy in trauma and complicated retinal detachment. A histopathologic study. *Ger J Ophthalmol* 1994;3:15-18.
- Okada K, Sakata H, Mizote H, et al. Postoperative posterior retinal holes after pars plana vitrectomy for primary retinal detachment. *Retina* 1997;17:99-104.
- Blodi BA, Paluska SA. Cataract after vitrectomy in young patients. *Ophthalmology* 1997;104:1092-5.
- Hsu HAT, Ryan SJ. Natural history of penetrating ocular injury with retinal laceration in the monkey. *Graefes Arch Clin Exp Ophthalmol* 1986;224:1-6.
- Lazarus HS, Schoenfeld CL, Fekrat S, et al. Hyalocytes synthesize and secrete inhibitors of retinal pigment epithelial cell proliferation in vitro. *Arch Ophthalmol* 1996;114:731-6.

### Intraocular infestation with the worm, *Thelazia callipaeda*

EDITOR.—Ocular infections with helminthic parasites are well described. The commonest organisms are filarial worms that reside in subcutaneous tissue, and are found as skin infestations or masses in the lids. Some are known to live freely in the conjunctival sac. Worms that are visible to the naked eye are often referred to as "eyeworms", and are in the larval or adult stage of their life cycle. *Thelazia callipaeda*, or the oriental eye worm, is a spiruroid nematode which is the causative organism in thelaziasis, a well described condition affecting the external eye.<sup>1</sup> It is primarily a parasite of the conjunctiva in dogs, and is also found in rabbits and humans.<sup>2</sup> Its presence in the conjunctival sac causes lacrimation and irritation, and its frequent excursions across the cornea may cause marked discomfort and, eventually, corneal scarring. The worm also causes paralytic ectropion through its presence in the lower fornix. At least 40 cases of infection in humans have been described from China, Japan, India, Russia, Thailand, and Korea. All of these report extraocular infection only. We report the first case of *Thelazia callipaeda* to cause intraocular infection.

#### CASE REPORT

A 21 year old Chinese woman presented to the ophthalmology department at Shantou Central Hospital, Guangdong, China, complaining of decreased vision in her right eye and a floater in the right visual field. She had no photopsia or field loss, and no pain, redness, or discharge. She had no past ocular or medical history, and was otherwise well.

On examination she had a visual acuity of 6/60 in the right eye, and 6/6 in the left eye. There was no external evidence of trauma; the lids were healthy, the conjunctiva white, the cornea clear, and the anterior chamber quiet. A mild vitreous haze obscured the foveal reflex, and clearly visible within the vitreous cavity was a live, mobile, white worm. There was no retinal abnormality.

One month later she underwent a three port pars plana vitrectomy, and the worm was coaxed into a flute needle and removed intact. The patient made an uncomplicated recovery from surgery. At 6 weeks postoperatively the eye was quiet and she had a visual acuity of 6/24. On detailed examination, the worm was identified as an adult female specimen of *Thelazia callipaeda*. Treatment with ivermectin is recommended for cases of thelaziasis, but in the absence of preoperative and postoperative

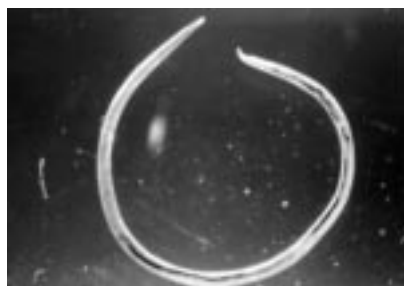

Figure 1 Light micrograph of *Thelazia callipaeda* (magnification  $\times 10$ ).

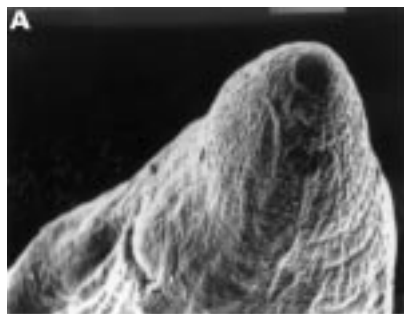

Figure 2 (A) Electron micrograph of tail end of *Thelazia callipaeda* (magnification  $\times 1000$ ). (B) Electron micrograph of head end of *Thelazia callipaeda* (magnification  $\times 1000$ ).

symptoms of inflammation due to infestation, pharmacological treatment was not commenced in this case.

#### COMMENT

*Thelazia callipaeda* ( $\theta\eta\lambda\alpha\zeta\omega$ , to suck) is a member of the phylum Nematoda, order Spirurida, suborder Spirurata, superfamily Spiruroidea. Adult worms look like creamy white threads; males are 4.5–13 mm long and 0.25–0.75 mm in diameter; females are larger, ranging from 6.2 to 17 mm in length and 0.3 to 0.85 mm in diameter (Fig 1). *T. callipaeda* is an unsegmented invertebrate with distinct oral and anal parts.<sup>3</sup> The male is identifiable by its curved posterior (Fig 2A). In both the male and the female, the mouth is without lips (Fig 2B) and consists of two concentric rings of flattened papillae around a central opening. It should be noted that there are no hooks or sharp spines in the mouth or elsewhere on the body, and this raises the question of how this worm entered the eye.

*Gnathostoma spinigerum*, a close relative of *Thelazia*, is quite frequently found within the eye and causes major tissue destruction. Structurally, one of its most distinguishing features is the presence of rows of curved hooks and posteriorly angled spines in a cuff around the mouth used for boring into tissue. *T. callipaeda* does not possess the organs to

enable it to burrow through or bore its way into any body structure.

Little is known about the life cycle of *Thelazia*. The intermediate host is *Amitia variegata*, a fly of the *Drosophila* family.<sup>4</sup> It is known to infect the lacrimal sac, from where it passes into the conjunctival sac. It is probably deposited in the larval form by flies settling on the eyes and this accounts for extraocular infection. The adult worm in our patient's eye was fully developed and healthy. It had caused little inflammatory response, and appeared to thrive in the conditions provided by the vitreous cavity, suggesting the possibility of immune privilege. We cannot explain how this worm entered the eye. We put forward the suggestion that humans may be the definitive host, with dogs and rabbits being the reservoir. For intraocular colonisation, the infective stage is probably the filariform larva, the portal of entry being the skin. An alternative mode of infection may be as the larva or embryonated egg ingested with raw drinking water.

R ZAKIR

Southampton Eye Unit,  
Southampton SO16 6YD

Z ZHONG-XIA

Shantou Central Hospital, Guangdong, China

P CHIODINI

C R CANNING

Southampton Eye Unit,  
Southampton SO16 6YD

Correspondence to: Dr Zakir, West Suffolk Hospital, Bury St Edmunds, Suffolk

Accepted for publication 24 May 1999

- 1 Duke-Elder S, ed. Parasitic keratoconjunctivitis. In: *System of ophthalmology*. Vol VIII, part I. London: Henry Kimpton, 1965:416–17.
- 2 Levine ND. Spirurids. In: *Nematode parasites of domestic animals and man*. 2nd ed. Minneapolis: Burgess Publishing Company, 1980:321–3.
- 3 Beaver PC, Jung RC. The spirurida. In: *Clinical parasitology*. 9th ed. Philadelphia: Lea Febiger, 1984:344–5.
- 4 Yamaguchi T. Optic symptoms. In: *A colour atlas of clinical parasitology*. London: Wolf Medical, 1981:170–1.

#### Macular dystrophy of malattia leventinese. A 25 year follow up

EDITOR.—Macular degeneration is a clinical term used to describe a variety of diseases characterised by progressive loss of central vision associated with abnormalities of Bruch's membrane and the retinal epithelium. This dominantly inherited disorder, characterised by a radial pattern of innumerable small elongated basal laminar drusen, was initially reported in a family from the Leventine Valley (Switzerland).<sup>1,2</sup> The gene responsible for autosomal dominant malattia leventinese has been mapped to the short arm of chromosome 2p16–21.<sup>3,4</sup> We report the case of a woman who developed unusual complications associated with this disease during a 25 year follow up.

#### CASE REPORT

In 1973, ophthalmological examination led to a diagnosis of bilateral hereditary macular dystrophy (malattia leventinese) in a woman born in 1943. Her visual acuity was then 20/20 for both eyes without any correction (Fig 1A).

In 1981, subfoveal neovascularisation led to an irreversible decrease in visual acuity in her right eye, down to 20/1000 (Fig 1B).

In 1996, a dense right vitreous haemorrhage led to a further decrease in acuity. After

resorption, fundus examination disclosed an advanced stage of the macular disease with irregular subretinal metaplasia, hyperplasia of the retinal pigment epithelium and discrete radial basal laminar drusen (Fig 2A). The fundus also showed a wedge-shaped superotemporal area with intraretinal haemorrhages, hard exudates, and sheathed vessels. The fluorescein angiogram showed telangiectatic vessels, shunt vessels, and microaneurysms, in addition to neovascularisation (Fig 2B). After laser photocoagulation, no further intravitreous haemorrhage episode occurred. The left eye had a visual acuity of 20/30 and fundus examination revealed a macula identical to that of the right eye, without complication.

#### COMMENT

In malattia leventinese, the maculopathy is characterised by a radial pattern of innumerable small elongated basal laminar drusen.<sup>5</sup> This maculopathy has been described in a 15 year old patient.<sup>3</sup> The visual acuity of patients suffering from malattia leventinese, however, remains good for quite a long time.<sup>3</sup> Thus, most patients are asymptomatic until the fourth or fifth decade of life, at which point they have a variety of symptoms, including decreased visual acuity, paracentral scotomas, photophobia, and metamorphopsia.<sup>3</sup> The main complication is macular subretinal neovascularisation, reported in some patients.<sup>6</sup> In our present case, such macular subretinal neovascularisation caused a severe decrease in visual acuity down to 20/1000 in 1981. The contralateral eye was unaffected, fortunately conserving an acuity of 20/30.

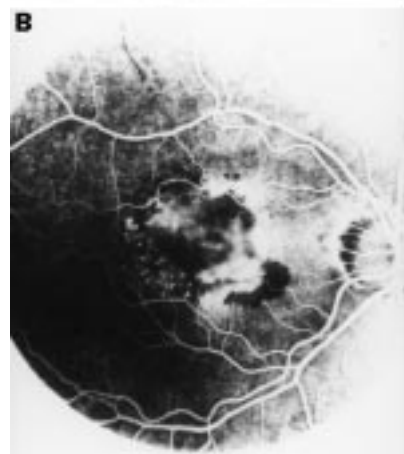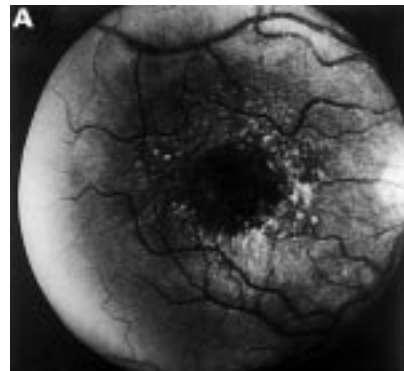
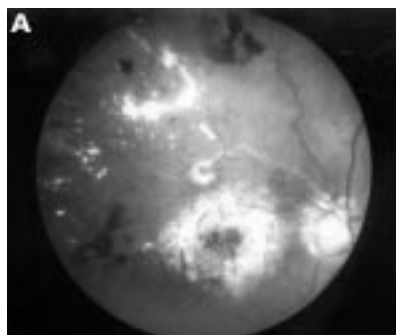

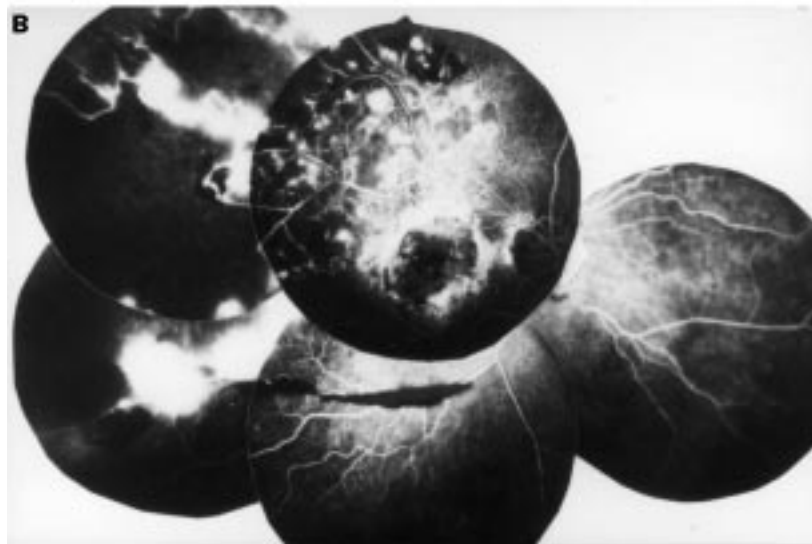
Figure 1 (A) Right eye. Fundus photograph in 1973 shows a radial pattern of innumerable small elongated basal laminar drusen. (B) Right eye. Fluorescein angiogram in 1981 shows submacular neovascularisation with fluorescein leakage.



**Figure 2** (A) Right eye. Photograph in 1996. Advanced stage of the macular disease with irregular subretinal fibrous metaplasia, hyperplasia of the retinal pigment epithelium, and discrete radial basal laminar drusen. Note also a wedge-shaped superotemporal area with intraretinal haemorrhages, hard exudates, and sheathed vessels. (B) Right eye. Fluorescein angiogram in 1996. Note the temporal retinal ischaemia with telangiectatic vessels, shunt vessels, and microaneurysms, in addition to the neovascularisation.



We have here described the first example of peripheral retinal neovascularisation with ischaemia. The aetiology of this ischaemia probably concerns a retinal vein branch occlusion not linked with macular degeneration. The occlusion had developed very discreetly, with the patient aware of no functional sign. In fact, visual acuity was already severely impaired by the neovascular complication of the macula and only the nasal visual field was affected, whence the lack of ocular disturbance. No aetiology could be found for the occlusion. A general check up showed no systemic abnormality.

Thus, this observation suggests the need for great attention to be paid to the retinal periphery in patients suffering from macular dystrophy, whether hereditary or not, so as to prevent the development of potentially serious complications.

This work was supported in part by the Hospices Civils de Lyon and the Université Claude Bernard Lyon I

JEAN-CHRISTOPHE ZECH  
SANDRA ZAUCHE

Hôpital Edouard Herriot, Université Claude Bernard  
Lyon I, Service d'Ophthalmologie, Lyons, France

FRANÇOIS MOURIER  
Hôpital de la Croix Rousse, Lyons, France

HENRI PLAUCHU  
Hôpital de l'Hôtel-Dieu, Service de Génétique,  
Lyons, France

JEAN-DANIEL GRANGE  
Hôpital de la Croix Rousse Lyons, France

CHRISTIANE TREPSAT  
Hôpital Edouard Herriot, Université Claude Bernard  
Lyon I, Service d'Ophthalmologie, Lyons, France

Correspondence to: Dr Jean-Christophe Zech, Hôpital Edouard Herriot, Université Claude Bernard Lyon I, Service d'Ophthalmologie, Pavillon C, Place d'Arsonval 69437 Lyon cedex 03 France.

Accepted for publication 21 May 1999

- 1 Vogt A. Die ophthalmoscopie im rotfreien licht. In: *Graefes saemisch handbuch der gesamten augenheilkunde*. 3rd ed. Berlin: Springer, 1925;3:1-118.
- 2 Forni S, Babel J. Etude clinique et histologique de la malattia leventinese; affection appartenant au groupe des dégénérescences hyalines du pôle postérieur. *Ophthalmologica* 1962;143:313-22.
- 3 Héon E, Piguet B, Munier F, et al. Linkage of autosomal dominant radial drusen (malattia leventinese) to chromosome 2p16-21. *Arch Ophthalmol* 1996;114:193-8.
- 4 Edwards AO, Klein ML, Berselli CB, et al. Malattia leventinese: refinement of the genetic locus and phenotypic variability in autosomal dominant macular drusen. *Am J Ophthalmol* 1998;126:417-24.
- 5 Gass JDM. Basal laminar drusen and macular degeneration In: Gass JDM, ed. *Stereoscopic atlas of macular disease: diagnosis and treatment*. 4th ed. St Louis: Mosby, 1997:110-11.
- 6 Piguet B, Haimovici R, Bird AC. Dominantly inherited drusen represent more than one disorder: a historical review. *Eye* 1995;9:34-41.

#### Acute central retinal vein occlusion successfully treated with intravenous thrombolysis

EDITOR.—Central retinal vein occlusion (CRVO) is a condition which often has profound effects on vision. At present there is little to offer patients in the form of treatment to preserve vision. The visual outcome is largely determined by the severity and duration of the vein occlusion. Management is currently aimed at preventing the complications secondary to retinal ischaemia. The incidence of fellow eye involvement with CRVO is

believed to be in the order of 1%. We present a patient with "second eye" CRVO, who presented with acute reduction in vision and who responded dramatically to intravenous streptokinase.

#### CASE REPORT

A 75 year old white man noticed a sudden reduction in vision in his right eye while walking up a hill. He already had poor vision in his left eye from a CRVO 6 years earlier. He went immediately to eye casualty and was seen within 2 hours from the onset of symptoms. His only risk factor for vein occlusion was ocular hypertension treated with timoptol 0.25% twice daily to both eyes.

On examination, visual acuities were 6/36 right eye and counting fingers left eye, there was no relative afferent pupillary defect and intraocular pressures were 21 mm Hg in both eyes. Examination of the right fundus revealed scattered tiny blot haemorrhages and tortuous veins.

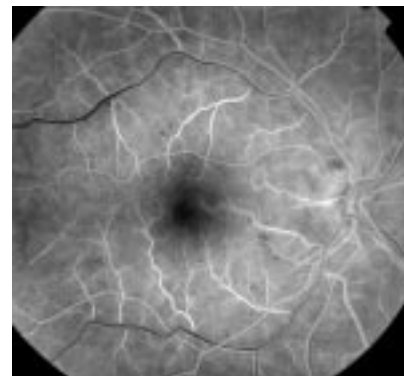A fundus fluorescein angiogram showed pulsatile arterial filling with venous filling delayed until 34.6 seconds (Fig 1). A diagnosis of acute central retinal vein occlusion was made. Because of the previous left CRVO and the short history of symptoms in his right eye, the option of thrombolysis was carefully discussed with the patient, including the small risk of cerebral haemorrhage. Streptokinase,  $1.5 \times 10^6$  units, was infused 7 hours after the onset of symptoms. Within 30 minutes, his visual acuity had improved to 6/9. The patient was empirically anticoagulated with heparin and warfarin, keeping the international normalised ratio between 2 and 3. Repeat fluorescein angiogram showed marked improvement in venous filling and loss of pulsatile arterial filling. In addition, several post thrombolysis haemorrhages were evident (Fig 2). The patient took warfarin for 9 months in total and now remains on aspirin alone. His vision in the right eye remains at 6/9.

#### COMMENT

Central retinal vein occlusion can profoundly affect vision and lead to neovascular complications. Current therapeutic options are limited mainly to the prevention or treatment of secondary complications.

Evidence for thrombus formation in CRVO has been reported by Green *et al* in a prospective histopathological study of patients with CRVO. They demonstrated recanalised thrombus in 89.7% of eyes and fresh thrombus formation in the remaining 10.3%.

Animal studies have shown encouraging responses to thrombolysis in experimental



**Figure 1** Fundus fluorescein angiogram of the right eye demonstrating early venous filling 34.6 seconds after injection.

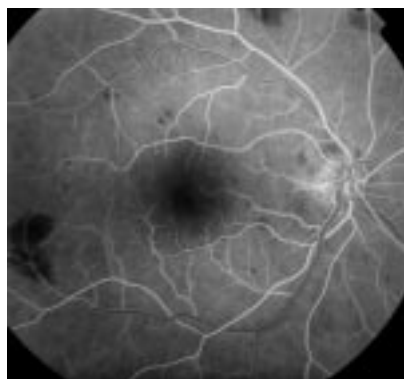


Figure 2 Within 24 hours after receiving intravenous streptokinase, venous filling was evident by 23.3 seconds (note preretinal haemorrhages post thrombolysis). Images digitally processed using IMAGEnet for Windows.

CRVO. Fibrinolytic given within 2 days of experimental vein occlusion in rabbits was shown to result in resolution of retinal haemorrhages and return of normal retinal circulation within 48 hours.<sup>2</sup> Similar animal studies using recombinant tissue plasminogen activator shortly after experimentally induced vein occlusion resulted in significant retinal vein patency in treated eyes.<sup>3</sup> In one randomised controlled clinical trial, patients with CRVO who received streptokinase followed by full anticoagulation within 7 days of onset of visual symptoms, showed a statistically significant improvement in visual acuity. Late presentation was identified as a possible cause of limited improvement in some cases.<sup>4</sup> Reports of vitreous haemorrhage occurring during treatment (3/20 cases<sup>5</sup>) together with the reported incidence of cerebral haemorrhage with streptokinase (57/13607 cases<sup>6</sup>) account for the absence of a defined role of this drug in the treatment of vein occlusions.

Selective cannulation of a branch retinal vein and infusion of tissue plasminogen activator in a patient with a non-acute CRVO in the second eye has been described. Several other treatment modalities had already been tried unsuccessfully. While avoiding systemic complications, the treatment failed to show any objective improvement in visual acuity and the patient subsequently went on to develop angle neovascularisation.<sup>6</sup>

Clearly many vein occlusions present late, where irreversible retinal damage has occurred. We propose that only in those circumstances where the presentation is acute should the use of intravenous thrombolysis be considered.

M T J COSTEN  
W B M DONALDSON  
J A OLSON

Department of Ophthalmology, University of Aberdeen,  
Foresterhill, Aberdeen AB25 2ZB

Correspondence to: Dr J Olson.

Accepted for publication 26 April 1999

- Green WR, Chan CC, Hutchins GM, *et al*. Central retinal vein occlusion: a prospective histopathological study of 29 eyes in 28 cases. *Trans Am Ophthalmol Soc* 1981;79:371-422.
- Mutlu F. Experimental retinal vein occlusion and treatment with fibrinolytic. *Am J Ophthalmol* 1966;62:282-6.
- Oncel M, Peyman GA, Khoobehi B. Tissue plasminogen activator in the treatment of experimental retinal vein occlusion. *Retina* 1989;9:1-7.
- Kohner EM, Pettit JE, Hamilton AM, *et al*. Streptokinase in central retinal vein occlusion: a controlled clinical trial. *BMJ* 1976;1:550-3.

- ISIS-3. A randomized comparison of streptokinase vs tissue plasminogen activator vs anistreplase and of aspirin plus heparin vs aspirin alone among 41,229 cases of suspected acute myocardial infarction. ISIS-3 (Third International Study of Infarct Survival) Collaborative Group. *Lancet* 1992;339:753-70.
- Weiss JN. Treatment of central retinal vein occlusion by injection of tissue plasminogen activator into a retinal vein. *Am J Ophthalmol* 1998;126:142-4.

### Retinitis pigmentosa with visual fluctuations and arrestin gene mutation

EDITOR,—We report a case of retinitis pigmentosa with day to day visual fluctuations and a mutation in the arrestin gene.

#### CASE REPORT

A 45 year old Japanese man first noticed night blindness at junior high school age, followed by a slowly progressive loss of visual acuities and fields. At presentation, the best visual acuity was 10/200 in each eye. Goldmann perimetries revealed generalised narrowing of the peripheral field and marked loss of central visual sensitivities. Bright flash electroretinogram (ERG) in a fully dark adapted state was not recordable in either eye. Ophthalmoscopies revealed advanced stage of retinitis pigmentosa (Fig 1). There was no Mizuo's phenomenon<sup>1</sup> in the fundus. This patient reported that he had felt relatively better vision ("good day") on every other day that alternated with worse vision ("bad day").

Furthermore, he claimed that bad day was repeated after physical stress or alcohol drinking, followed by a good day to return to the ordinary cycle. In our 10 years' observation, the profile of day to day variation was reproducible. To quantitatively assess the characteristic visual symptoms, perimetric tests were performed in both the centre and periphery using an automated perimeter on eight different days in a period of 2 months, half on a good day and the other half on a bad day; ERG examinations were also performed. Figures 2 and 3 illustrate the results, demonstrating that the visual sensitivity in the peripheral field varied in a manner consistent with the patient's reports, although not obvious in the central field. In contrast with

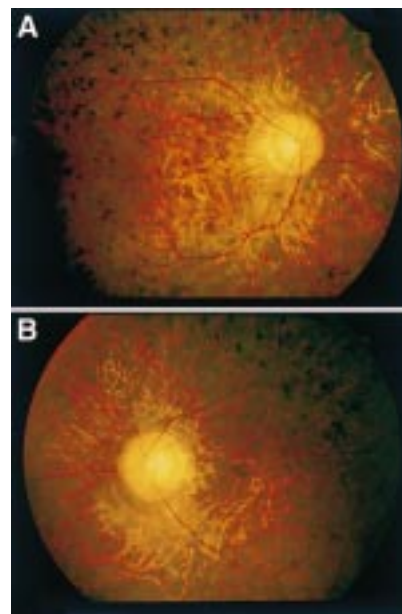


Figure 1 Fundus in the right (A) and left (B) eye of the patient. There are diffuse chorioretinal atrophies accompanied by numerous bone spicule pigments, attenuated retinal vessels, and pale optic discs.

perimetries, ERG responses remained undetectable irrespective of visual fluctuations. His healthy parents were first cousins, and his elder brother had night blindness due to classic retinitis pigmentosa. Because of the mild mental retardation, the day to day visual fluctuations or other symptomatic variations could not be confirmed in his brother.

DNA was extracted from the peripheral blood after obtaining informed consent. Exon 11 of the arrestin gene was amplified using polymerase chain reaction.<sup>2</sup> The amplified product was separated on polyacrylamide gel and revealed abnormally rapidly migrated signal suggesting a small deletion. Direct sequencing using an automated nucleotide sequencer (ALF Express, Pharmacia) disclosed a homozygous deletion of adenine at nucleotide 1147 (1147delA). This mutation

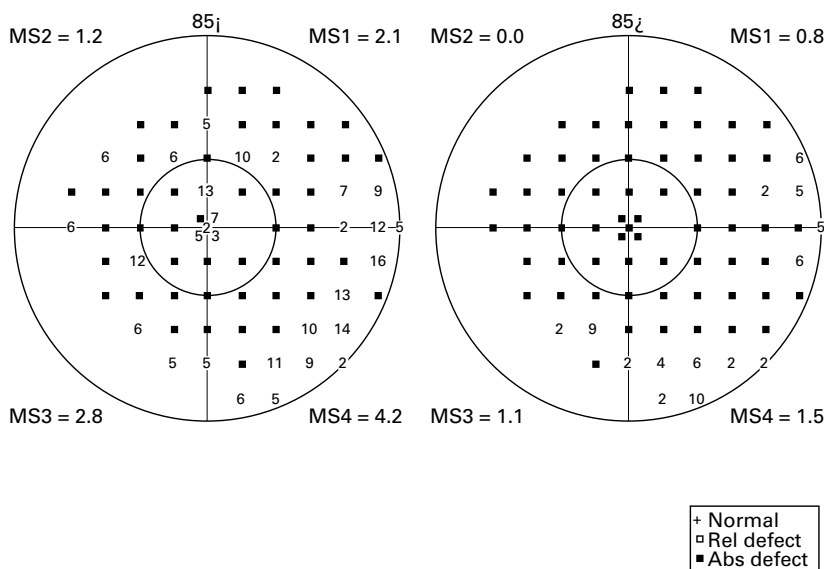


Figure 2 Visual field sensitivity, determined by an automated perimeter (Interzeag Octopus 101, low vision program) on different days. Representative visual field charts (right eye) obtained on a "good day" (left chart) and a "bad day" (right chart).

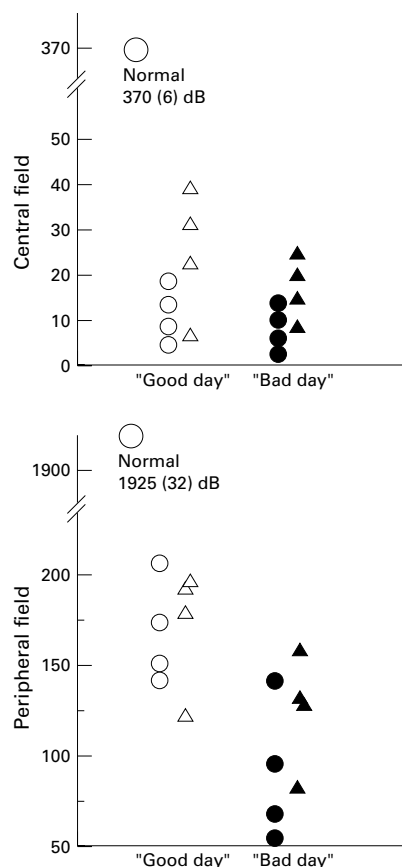


Figure 3 Mean sensitivity (dB) at 76 locations; the value in normal individuals of the same age as the case is around 30 dB. Open symbols (circles, right eye; triangles, left eye) illustrate measurements on four good days and closed symbols on four bad days. Visual sensitivity on good days is significantly better than that on bad days (paired *t* test,  $p < 0.002$ ).

was also found in our two independent patients with Oguchi's disease, but not in 25 unrelated cases of autosomal recessive retinitis pigmentosa or 70 healthy individuals (Fig 4).

#### COMMENT

Some patients with advanced retinitis pigmentosa report that their vision is "crystal clear" in the morning but soon becomes fuzzy, and some others announce on a particular visit that their visual field testing either went well or poorly depending on whether they are having a good or bad day.<sup>3,4</sup> The patient described

here had advanced retinitis pigmentosa and reported that he had experienced over the years alternating days of good and bad vision and that the day to day visual fluctuations had been modified by physical stress or alcohol drinking. Perimetric evaluations of this case demonstrated daily variability in visual sensitivities which corresponded to the subjective complaints. This form of visual fluctuation appears unusual, and it is remarkable that this patient had such a homozygous mutation in the arrestin gene that gives rise to a premature truncation of translation. The human arrestin, also known as S-antigen, has an inhibitory role in the activated phototransduction cascade. It should be mentioned that the arrestin gene is one of those expressed in the pineal gland that is considered to play a major role in the circadian rhythm.<sup>5</sup> Thus, it is tempting to speculate that the mutation in the arrestin gene could have modified rhythmic activities to induce daily alternating visual fluctuations in the present retinitis pigmentosa patient. The full coding sequences of the rhodopsin gene were normal in the relevant patient (data not shown). However, we could not deny the association of different polymorphisms in related gene products, or different environmental influences on the daily alternating visual fluctuations.

Recent molecular assessments revealed families with diffuse retinitis pigmentosa with or without features of Oguchi's disease harbouring 1147 delA in the arrestin gene.<sup>6-8</sup> The patient described here provides additional evidence that the same arrestin gene mutation is causally related not only to Oguchi's disease but also to autosomal recessive retinitis pigmentosa. It is emphasised that our patient had classic features of autosomal recessive retinitis pigmentosa with poor visual prognosis and showed unusual visual fluctuations. In view of a rare mutation of arrestin gene, the relevant retinitis pigmentosa might be extremely rare. In a large series of white patients with aetiology of undefined retinitis pigmentosa arrestin gene mutation was not detected.<sup>9</sup>

YASUSHI ISASHIKI

Center for Chronic Viral Diseases, Kagoshima University Faculty of Medicine, Kagoshima-shi, Japan

NORIO OHBA

KATSUAKI KIMURA

SHOZO SONODA

TOMOKO KAKIUCHI

Department of Ophthalmology, Kagoshima University Faculty of Medicine, Kagoshima-shi, Japan

TETSUMA OZAWA

Yokohama Teishin Hospital, Yokohama, Japan

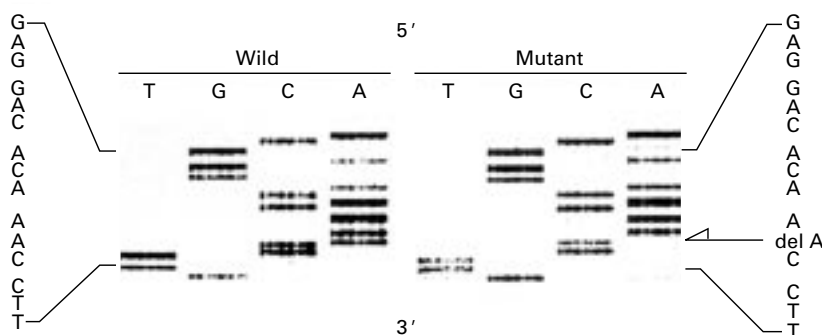


Figure 4 Direct sequencing results of exon 11 of the arrestin gene in the reported case, demonstrating a homozygous deletion of adenine at nucleotide 1147 (arrowhead).

Correspondence to: Norio Ohba, MD, Department of Ophthalmology, Kagoshima University Faculty of Medicine, Kagoshima-shi 890-8520, Japan.

Accepted for publication 18 May 1999

- Mizuo G. A new discovery in dark adaptation in Oguchi disease. *Acta Soc Ophthalmol Jpn* 1913;17:1148-50.
- Fuchs S, Nakazawa M, Maw M, *et al*. A homozygous 1-base deletion in the arrestin gene is a frequent cause of Oguchi disease in Japanese. *Nat Genet* 1995;10:360-2.
- Duke-Elder SS, Dobree JH. Diseases of the retina. In: Duke-Elder SS, ed. *System of ophthalmology*. Vol X. London: Henry Kimpton, 1967:589.
- Heckenlively JR, Krauss HR. Visual fields in retinitis pigmentosa. In: Heckenlively JR, ed. *Retinitis pigmentosa*. Philadelphia: JB Lippincott, 1988:25-36.
- Yamaki K, Tsuda M, Kikuchi T, *et al*. Structural organization of the human S-antigen gene: cDNA, amino acid, intron, exon, promoter, in vitro transcription, retina, and pineal gland. *J Biol Chem* 1990;265:20757-62.
- Nakazawa M, Wada Y, Fuchs S, *et al*. Oguchi disease: phenotypic characteristics of patients with the frequent 1147 delA mutation in the arrestin gene. *Retina* 1997;17:17-22.
- Nakazawa M, Wada Y, Tamai M. Arrestin gene mutations in autosomal recessive retinitis pigmentosa. *Arch Ophthalmol* 1998;116:498-501.
- Nakamachi Y, Nakamura M, Fujii S, *et al*. Oguchi disease with sectoral retinitis pigmentosa harboring adenine deletion at position 1147 in the arrestin gene. *Am J Ophthalmol* 1998;125:249-51.
- Sippel KC, DeStefano JD, Berson EL, *et al*. Evaluation of the human arrestin gene in patients with retinitis pigmentosa and stationary night blindness. *Invest Ophthalmol Vis Sci* 1998;39:665-70.

#### Orbital Kimura's disease in a white child

EDITOR.—Kimura's disease is an uncommon, chronic inflammatory disorder of unknown aetiology which occurs predominantly in orientals and presents with tumour-like swellings mainly in the head and neck region. The condition primarily involves the subcutaneous tissues, parotid glands, and/or lymph nodes. Orbital cases are infrequent and most reported cases are in adults, with only one case in a child of Afro-Caribbean descent.<sup>1</sup> Our case report presents orbital Kimura's disease in an 8 year old white child.

#### CASE REPORT

An 8 year old white girl presented to us with a 4 week history of a painless swelling of her right upper lid. She initially had an upper respiratory tract infection lasting a month which was treated by her general practitioner with Augmentin. She subsequently developed what appeared to be a right sided ptosis. Of note, she had a strong history of allergic eye disease with intermittent conjunctivitis, and also suffers from asthma for which she takes Pulmicort and Bricanyl inhaler regularly. Examination revealed a right partial ptosis, mild right proptosis, and a palpable, painless mass in the superior aspect of her right orbit. There were no pupillary abnormalities, her extraocular movements were full, and funduscopic examination was unremarkable. There was no associated regional lymphadenopathy and the rest of the ocular and general physical examination showed no other abnormalities.

Investigations done included a full blood count, which was within normal limits. WBC  $8.57 \times 10^9/l$  with a differential of neutrophils 62%, lymphocytes 26%, monocytes 6%, eosinophils 5%, and basophils 1%. A magnetic resonance imaging (MRI) scan with

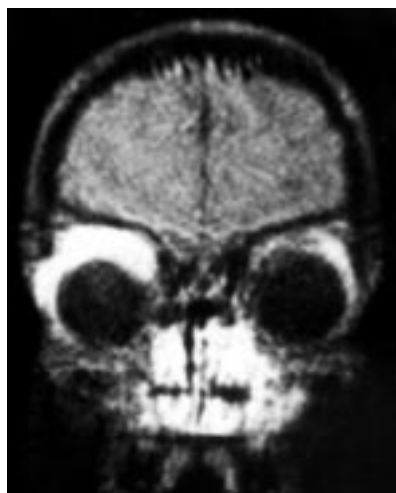


Figure 1 A magnetic resonance imaging (MRI) scan with contrast. There is an extensive superior orbital mass on the right side.

gadolinium contrast was done which showed an extensive superior orbital mass which was not clearly delineated, but involved the upper eyelid (see Fig 1). An orbital biopsy was subsequently performed. Histological sections revealed fibrosis with a marked vascular proliferation and a prominent perivascular inflammation consisting of eosinophils and lymphocytes (see Fig 2). There were also scattered lymphocytes and eosinophils throughout the fibrotic tissue with reactive lymphoid follicles. There was no evidence of necrosis, granulomas, or malignant cells. Immunohistochemical studies revealed no cells of myogenous origin present. Studies for desmin, myoglobin, and vimentin were negative. All of the cells considered lymphoid on the haematoxylin and eosin stain also stained for the leucocyte marker common leucocyte antigen (CLA). A diagnosis of Kimura's disease (angiolymploid hyperplasia with eosinophilia) was made.

At biopsy, the tumour was debulked and the patient was thereafter placed on a short 6 week course of oral steroids. The ptosis resolved and at 1 year follow up, there has been no clinical evidence of recurrence.

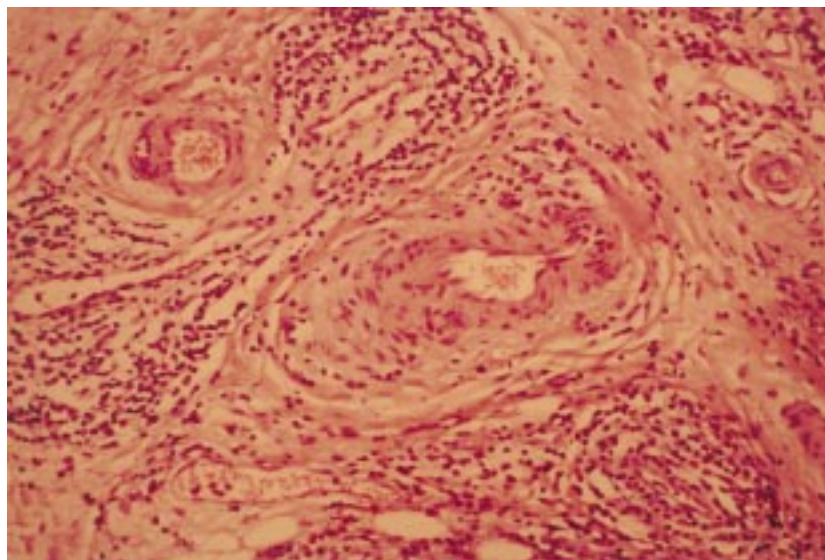


Figure 2 Section showing vascular proliferation with eosinophilic and lymphocytic perivascular inflammation and fibrosis. Haematoxylin and eosin stain. Original magnification  $\times 200$ .

#### COMMENT

Kimura's disease (or angiolymploid hyperplasia with eosinophilia) is a chronic inflammatory disorder of unknown aetiology which presents with tumour-like swellings mainly in the head and neck region. Most cases have been described in China and Japan, with relatively fewer cases reported in non-orientals.<sup>2</sup> The disease typically affects males in the 20–40 year age group, and presents as single or multiple smooth swellings in the subcutaneous tissues, major salivary gland and/or lymph nodes in the head and neck area.

Histopathologically, the features described in previous cases<sup>3,4</sup> corresponded with ours; there are eosinophilic infiltrates (mainly in a perivascular pattern), vascular proliferation, fibrosis, and formation of lymphoid follicles. It is still uncertain as to whether it represents a benign lymphoid neoplastic process, a variant of haemangioma or an allergic reaction. There have been no reported cases of malignant change or fatalities. There is usually an insidious onset with a long benign course, but recurrences are common after surgical excision. Systemic associations include asthma and nephrotic syndrome.<sup>3,5</sup> Regional lymphadenopathy ranges from 50–75% of cases and there is a high occurrence of peripheral blood eosinophilia.

Cases of Kimura's disease have been reported in the orbits<sup>6,7</sup>; however, there was only one previously reported orbital case in a child (of Afro-Caribbean descent).<sup>1</sup> To our knowledge, this is the first orbital case reported in a white child. Non-orbital cases of Kimura's disease have been treated with surgical excision, irradiation and steroid therapy. After active therapy, they tend to recur. Cases have been conservatively managed for up to 12 years successfully<sup>1</sup> although the cosmetic deformity can be quite a handicap. Periorbital cases have so far been treated successfully with surgical excision and biopsy with debulking.<sup>5,6</sup> Oral steroids or intralesional injection with steroids have not been as successful. There was only one reported case of severe haemorrhage on surgical resection.<sup>1</sup> Complete surgical excision appears to be the best treatment.

BENJAMIN CHANG

Department of Ophthalmology, Cork University Hospital, Cork, Ireland

DEIRDRE RYAN

Department of Histopathology, Cork University Hospital, Cork, Ireland

SUSAN KENNEDY

Department of Histopathology, Royal Victoria Eye and Ear Hospital, Dublin, Ireland

GERARD O'CONNOR

Department of Ophthalmology, Cork University Hospital, Cork, Ireland

Correspondence to: Dr Chang.

Accepted for publication 11 May 1999

- 1 Kennedy SM, Pitts FG, Lee WR, *et al*. Bilateral Kimura's disease of the eyelids. *Br J Ophthalmol* 1992;76:755–7.
- 2 Li TJ, Chen XM, Wang SZ, *et al*. Kimura's disease. *Oral Surg Oral Med Oral Pathol* 1996;82:549–55.
- 3 Kung M, Gibson J, Bannatyne M. Kimura's disease: a clinicopathologic case study of 21 cases and its distinction from angiolymploid hyperplasia with eosinophilia. *Pathology* 1984; 16:39–44.
- 4 Urabe A, Tsuneyoshi M, Enjoji M. Epitheloid hemangioma versus Kimura's disease. *Am J Surg Pathol* 1987;11:758–66.
- 5 Hidayat A, Cameron JD, Font RL, *et al*. Angiolymploid hyperplasia with eosinophilia (Kimura's disease) of the orbit and ocular adnexa. *Am J Ophthalmol* 1983;96:176–89.
- 6 Mulhern M, Power N, Kennedy S, *et al*. Bilateral Kimura's disease. *Orbit* 1996;15:91–6.

#### Amikacin retinal toxicity

EDITOR.—It is well established that early intravitreal antibiotics are the treatment of choice for bacterial endophthalmitis<sup>1</sup> but the choice of antibiotics remains controversial.<sup>2–5</sup> Most centres rely on combination therapy and aminoglycosides are often used to treat Gram negative organisms. Aminoglycosides have a narrow therapeutic index and therefore a relatively small increase in concentration can cause significant toxicity. Following concerns about the risks of retinal toxicity caused by intravitreal gentamicin many ophthalmologists now use 0.4 mg intravitreal amikacin even though its use has also been associated with retinal toxicity.<sup>2,3</sup> We report a case of retinal toxicity in a patient treated with intravitreal amikacin for postoperative bacterial endophthalmitis. This case serves to remind ophthalmologists of the risk of amikacin therapy and presents an argument for an alternative strategy in the treatment of bacterial endophthalmitis.

#### CASE REPORT

A 60 year old highly myopic woman presented with an acute history of increasing ocular pain and redness 5 days after routine phacoemulsification cataract extraction and intraocular lens implant. She had no other ocular or systemic history.

Initial examination revealed a visual acuity of 6/18, significant anterior chamber inflammation with a fibrin deposit over the pupil. A diagnosis of bacterial endophthalmitis was made and the patient was commenced on intravenous ciprofloxacin and hourly gentamicin, vancomycin, and dexamethasone eye drops. A vitreous biopsy was performed and 2 mg of intravitreal vancomycin (0.1 ml of 20 mg/ml) and 0.4 mg amikacin (0.1 ml of 4 mg/ml) were administered. The intravitreal antibiotics were prepared by a senior pharmacist using a typewritten protocol. The following day vision had deteriorated to no perception of light and the patient had developed a

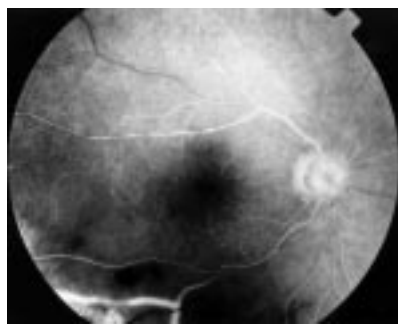


Figure 1 Fluorescein angiogram at 31 seconds showing delayed retinal perfusion with attenuated arterioles and incomplete venous filling.

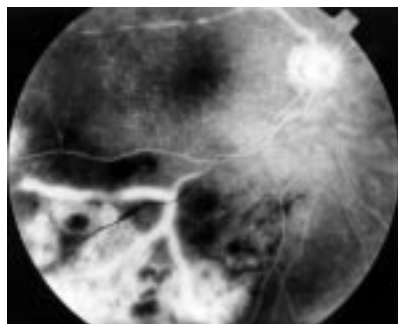


Figure 2 Fluorescein angiogram at 52 seconds showing an extensive area of capillary non-perfusion with marked staining of the arteriolar walls and persisting non-perfusion of adjacent retinal venules.

relative afferent pupillary defect. Microscopy and culture failed to demonstrate any causative organism. The patient was started on 40 mg oral prednisolone but failed to manifest any improvement in acuity. Subsequently she was transferred to a specialist vitreoretinal unit where a diagnosis of retinal amikacin toxicity was made. Fluorescein angiogram taken 16 days after initial presentation confirmed the presence of retinal haemorrhage and a discrete area of capillary non-perfusion with significant late fluorescein leakage (Figs 1 and 2).

#### COMMENT

Intravitreal aminoglycosides are still recommended for use in the treatment of bacterial endophthalmitis<sup>7</sup> despite the risk of retinal toxicity from intravitreal gentamicin and reports that amikacin in doses of 0.2–0.4 mg can also cause toxicity.<sup>2,3</sup> The low incidence of bacterial endophthalmitis means that physicians and pharmacists do not routinely prepare intravitreal antibiotics. Because of the low therapeutic index of aminoglycosides even relatively small dilution errors can cause retinal toxicity. For these reasons it is our practice to use a third generation cephalosporin (0.1 ml of ceftazidime 20 mg/ml) instead of an aminoglycoside. Primate studies have shown that intravitreal ceftazidime is non-toxic in doses of 2.25 mg<sup>8</sup> and ceftazidime has also been found to be effective against the Gram negative organisms responsible for postoperative endophthalmitis.<sup>9</sup> Over the past 18 months we have used intravitreal ceftazidime (2 mg) and vancomycin (2 mg) in 21 patients with good therapeutic effect and with no adverse reactions. Owing to the risk of severe retinal toxicity with intra-

vitreal aminoglycosides we recommend the use of ceftazidime instead of amikacin or gentamicin.

TIMOTHY L JACKSON  
TOM H WILLIAMSON  
St Thomas's Hospital, London

Correspondence to: Tim Jackson, Vitreoretinal Unit, Department of Ophthalmology, St Thomas's Hospital, Lambeth Palace Road, London SE1 7EH.

Accepted for publication 18 May 1999

- 1 Endophthalmitis Vitrectomy Study Group. Results of the Endophthalmitis Vitrectomy Study. A randomized trial of immediate vitrectomy and of intravenous antibiotics for the treatment of postoperative bacterial endophthalmitis. *Arch Ophthalmol* 1995;113:1479–96.
- 2 Campochiaro PA, Conway BP. Aminoglycoside toxicity; a survey of retinal specialists. Implications for ocular use. *Arch Ophthalmol* 1991;109:946–50.
- 3 Campochiaro PA, Lim JJ. Aminoglycoside toxicity in the treatment of endophthalmitis. The Aminoglycoside Toxicity Study Group. *Arch Ophthalmol* 1994;112:48–53.
- 4 Oum BS, D'Amico DJ, Wong KW. Intravitreal antibiotic therapy with vancomycin and aminoglycoside. An experimental study of combination and repetitive injections. *Arch Ophthalmol* 1989;107:1055–60.
- 5 Doft BH, Barza M. Ceftazidime or amikacin: choice of intravitreal antimicrobials in the treatment of postoperative endophthalmitis. *Arch Ophthalmol* 1994;112:17–18.
- 6 Kanski JJ. *Clinical ophthalmology*. 3rd ed. Oxford: Butterworth-Heinemann, 1994:301.
- 7 Cullom RD Jr, Chang BE, eds. *The Wills eye manual. Office and emergency room diagnosis and treatment of eye disease*. 2nd ed. Philadelphia: JB Lippincott, 1994:377–8.
- 8 Campochiaro PA, Green WR. Toxicity of intravitreal ceftazidime in primate retina. *Arch Ophthalmol* 1992;110:1625–9.
- 9 Irvine WD, Flynn HW Jr, Miller D, et al. Endophthalmitis caused by gram-negative organisms. *Arch Ophthalmol* 1992;110:1450–4.

#### Simultaneous administration of hepatitis B and polio vaccines associated with bilateral optic neuritis

EDITOR.—Immunisation against hepatitis B is recommended when there is an increased risk of contracting the virus because of lifestyle, occupation, or factors such as close contact with a case. Immunisation against poliomyelitis is routinely given to infants in the UK with reinforcement during childhood and then again in the teenage years. For those individuals at continued risk of infection, further reinforcing doses are given every 10 years.

Both are commonly used vaccines and serious adverse reactions are extremely rare. We describe a case of severe bilateral, progressive optic neuritis occurring 1 week after vaccination against hepatitis B and poliomyelitis.

#### CASE REPORT

A 44 year old female health worker presented with gradual reduction of vision in both eyes associated with retrobulbar discomfort exacerbated by ocular movement, 7 days after vaccination against hepatitis B and poliomyelitis. Ophthalmological findings revealed visual acuities of 6/18 right eye, 6/12 left eye associated with bilateral optic nerve swelling. Within the next 48 hours the visual acuities dropped to perception of light in both eyes with absent direct and indirect pupillary light responses. This was despite commencement of therapy with intravenous methylprednisolone. Systemic examination revealed no other abnormalities. All haematological and biochemical investigations were normal and no infective cause was isolated. Computed tomograph imaging was normal and there was no evidence of demyelination on magnetic resonance imaging. Cerebrospinal fluid (CSF)

examination revealed no abnormality either biochemically, after culture, or on electrophoresis. In addition, CSF pressure was within normal limits. Visually evoked potentials revealed absent responses. Despite 5 days of intravenous methylprednisolone (1 g per day) followed by a slow tapering of oral prednisolone (1 mg/kg/day) her vision remained poor (counting fingers at 1 metre in both eyes) after 3 months.

#### COMMENT

The recombinant hepatitis B vaccine has been associated with a diverse range of isolated adverse reactions but ocular complications are exceedingly rare. Granel *et al* attributed four cases of central retinal vein occlusion in patients under 50 years of age to the vaccine,<sup>1</sup> and associations with multiple evanescent white dot syndrome (MEWDS)<sup>2</sup> and acute posterior multifocal placoid pigment epitheliopathy (APMPPE)<sup>3</sup> have been described. Various related neurological and systemic features of an autoimmune nature have been reported including CNS demyelination.<sup>4</sup> Bilateral optic neuritis occurs occasionally in acute hepatitis B infection.<sup>5,6</sup>

Vaccines derived from live attenuated viruses such as the trivalent oral polio vaccine can cause direct viral infections of the central nervous system.<sup>7</sup> The incidence of vaccine derived paralytic poliomyelitis is reported as being one in three million in recipients of the vaccine or their close contacts.<sup>7</sup> The vaccine has also been linked to some cases of Guillain-Barré syndrome<sup>7</sup> but ocular complications have not been reported.

Others such as the trivalent measles, mumps, and rubella (MMR) vaccine<sup>8</sup> and the monovalent rubella vaccine,<sup>9</sup> have also been associated with bilateral optic neuritis.

The exact mechanisms behind neurological complications following vaccination are unknown but various hypotheses exist including immune complex mediated demyelination or neurotoxicity, antigenic mimicry between the stimulating vaccine derived antigen and normal or altered host tissue proteins, immediate hypersensitivity reactions, and stimulation of a pathogenic lymphocytic response.

Adverse neurological reactions generally occur 1–3 weeks following vaccination which supports the claim that vaccination was the aetiological factor in this case. To the best of our knowledge, this is the first report of this complication with either of the two individual vaccines. The fact that there are many case reports describing a diverse variety of systemic reactions of an autoimmune nature associated with both vaccines also adds to the claim. Those cases of optic neuritis attributed to other vaccines and to post infectious optic neuritis generally did better with corticosteroid therapy than in our case but high dose corticosteroids are generally considered to be the treatment of choice in these rare but potentially devastating complications.

OWEN STEWART  
BERNARD CHANG  
JOHN BRADBURY

Department of Ophthalmology, Bradford Royal Infirmary, Bradford, West Yorkshire

Correspondence to: Mr Owen Stewart, Department of Ophthalmology, St James's University Hospital, Leeds, West Yorkshire, LS9 7TF.

Accepted for publication 18 May 1999

1 Granel B, Disdier P, Devin F, et al. Occlusion of the central retinal vein after vaccination against viral hepatitis B with recombinant vaccines. 4 cases. *Press Med* 1997;26:62–5.

- 2 Baglivo E, Safran AB, Borruat FX. Multiple evanescent white dot syndrome after hepatitis B vaccine. *Am J Ophthalmol* 1996;122:431-2.
- 3 Brezin AP, Massin-Korobelnik P, Boudin M, et al. Acute posterior multifocal placoid pigment epitheliopathy after hepatitis B vaccine. *Arch Ophthalmol* 1995;113:297-300.
- 4 Kaplanski G, Retornaz F, Durand J, et al. Central nervous system demyelination after vaccination against hepatitis B and HLA haplotype. *J Neurol Neurosurg Psychiatry* 1995;58:758-9.
- 5 Galli M, Morelli R, Casellato A, et al. Retrobulbar optic neuritis in a patient with acute type B hepatitis. *J Neurol Sci* 1986;72:195-200.
- 6 Achiron LR. Postinfectious hepatitis B optic neuritis. *Optom Vis Sci* 1994;71:53-6.
- 7 Fenichel GM. Neurological complications of immunization. *Ann Neurol* 1982;12:119-27.
- 8 Stevenson VL, Acheson JF, Ball J, et al. Optic neuritis following measles/rubella vaccination in two 13-year-old children. *Br J Ophthalmol* 1996;80:1110-11.
- 9 Kline L, Margulies SL, Oh SJ. Optic neuritis and myelitis following rubella vaccination. *Arch Neurol* 1982;39:443-4.

### Retinopathy after long term, standard doses of hydroxychloroquine

EDITOR.—While the antimalarial drug chloroquine has frequently been reported to cause retinopathy, there have been very few documented cases occurring with hydroxychloroquine (Plaquenil, Winthrop Pharmaceuticals, New York, USA).<sup>1-5</sup> Patients may tolerate large cumulative doses (up to 3923 g) of hydroxychloroquine without developing retinopathy.<sup>1</sup> Doses of  $\leq 400$  mg/day and  $\leq 6.5$  mg/kg of body weight/day of hydroxychloroquine have been used safely and some authors have suggested that ophthalmic screening is not necessary for patients on these doses.<sup>3-5</sup> We present a case of hydroxychloroquine toxicity that developed in a patient after long term use of 400 mg (6.3 mg/kg) of hydroxychloroquine daily.

#### CASE REPORT

A 61 year old white woman presented with a 1 year history of increased glare in both eyes without change in visual acuity. She had a history of rheumatoid arthritis for which she took hydroxychloroquine 400 mg daily (6.3 mg/kg/day) for 10 years. Her total hydroxychloro-

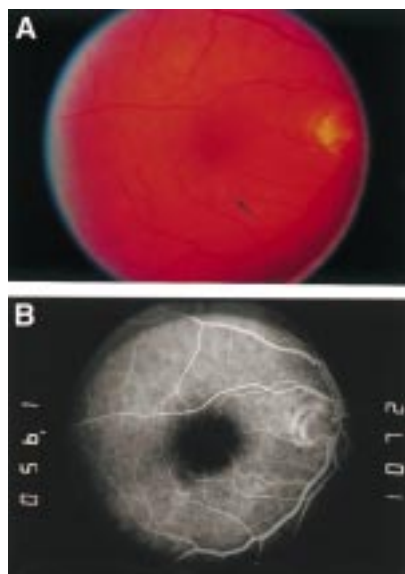


Figure 1 (A) Colour fundus photograph of the right eye at presentation showing subtle pigmentary changes (arrow) of the retinal pigment epithelium inferior to the fovea. (B) Fluorescein angiogram of the right eye demonstrating transmission defects inferior to the fovea consistent with toxicity.

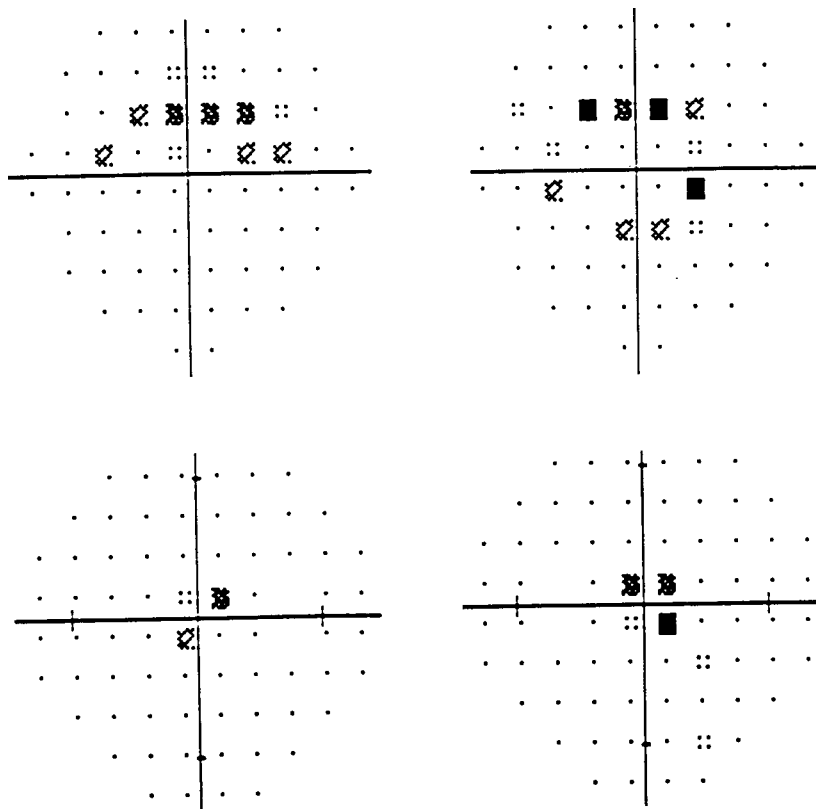


Figure 2 (Upper) Pattern standard deviation as calculated by Humphrey 10-2 automated static perimetry at presentation showing bilateral paracentral scotoma. (Lower) Follow up visual fields 10 months after cessation of hydroxychloroquine therapy showing partial resolution of the scotoma.

quine dose was 1460 g. The patient had never taken chloroquine and had no history of macular disease. Her weight had been stable over the 10 year period. Family history was negative for macular dystrophy or retinal degeneration. Visual acuity at presentation was 20/20 in both eyes. Colour vision testing with pseudoisochromatic plates was normal in both eyes. Fundus examination showed subtle retinal pigment epithelium (RPE) pigmentary changes in a crescent pattern around the inferior fovea of both eyes (Fig 1A). Fluorescein angiogram confirmed the fundus findings (Fig 1B) which were felt to be early bull's eye maculopathy. No drusen or signs of macular degeneration were appreciated in either eye. A central visual field performed with Humphrey automated static threshold perimetry using a white test object revealed bilateral paracentral ring scotoma corresponding to the macular pigmentary changes (Fig 2, upper). A diagnosis of hydroxychloroquine retinopathy was established and the drug was discontinued.

Ten months later the patient's vision remained 20/20 with normal colour vision in both eyes. Her symptom of glare in both eyes had resolved. The RPE changes in the retina were unchanged and visual field testing showed some improvement of the paracentral scotoma (Fig 2, lower).

#### COMMENT

Hydroxychloroquine retinopathy is a rare condition characterised by bull's eye maculopathy or pigmentary changes in the macula, corresponding scotomas on visual field testing, and irreversible signs and symptoms once hydroxychloroquine is stopped.<sup>2-5</sup> Cases of preretinopathy have been described in which visual field defects were elicited using a red test object but not a white test object on

Humphrey perimetry.<sup>2,3</sup> All cases of preretinopathy completely resolved after the discontinuation of hydroxychloroquine.<sup>2</sup> Five cases of true hydroxychloroquine retinopathy reported in the literature demonstrated that discontinuation of hydroxychloroquine resulted in stabilisation but not resolution of the retinopathy.<sup>2-4</sup> Unlike the other reported cases of true hydroxychloroquine retinopathy, our patient had some resolution of visual field loss.

Much controversy exists as to whether the daily or cumulative dose of hydroxychloroquine contributes the greater risk for retinopathy. While there have been reported cases of hydroxychloroquine toxicity at cumulative doses similar to our patient's (1460 g over a 10 year period), these patients had (1) received chloroquine therapy before hydroxychloroquine therapy, (2) were treated with daily doses  $>400$  mg/day, or (3) exceeded a daily dosage of 6.5 mg/kg of body weight/day.<sup>2</sup> Our patient's daily dose never exceeded 400 mg/day or 6.3 mg/kg of body weight/day. Her renal function was normal, thereby making the possibility of inadequate clearance of hydroxychloroquine unlikely.

Hydroxychloroquine may cause retinopathy when used in recommended doses over a long period of time. Since a threshold dose for retinal toxicity has not been established, careful screening examinations should be performed especially as the cumulative dose increases. Prompt cessation of hydroxychloroquine may result in stabilisation of maculopathy at a clinically benign stage.

JENNIFER E THORNE  
ALBERT M MAGUIRE

Department of Ophthalmology, Scheie Eye Institute,  
The Hospital of the University of Pennsylvania,  
University of Pennsylvania School of Medicine,  
Philadelphia, USA



Correspondence to: Jennifer E Thorne, MD, Scheie Eye Institute, 51 North 39th Street, Philadelphia, PA 19104, USA.

Accepted for publication 10 May 1999

- 1 Johnson MW, Vine AK. Hydroxychloroquine therapy in massive total doses without retinal toxicity. *Am J Ophthalmol* 1987;104:139-44.
- 2 Weiner A, Sandberg MA, Gaudio AR, et al. Hydroxychloroquine retinopathy. *Am J Ophthalmol* 1991;112:528-34.
- 3 Bernstein HN. Ophthalmic considerations and testing in patients receiving long-term antimalarial therapy. *Am J Med* 1983;75:25-33.
- 4 Levy GD, Munz SJ, Paschal J, et al. Incidence of hydroxychloroquine retinopathy in 1207 patients in a large multicenter outpatient practice. *Arthritis Rheum* 1997;40:1482-6.
- 5 Mackenzie AH. Dose refinements in long-term therapy of rheumatoid arthritis with antimalarials. *Am J Med* 1983;75:40-5.

### Visual loss after primary trabeculectomy with mitomycin C in Ehlers-Danlos syndrome

**EDITOR.**—Antiproliferatives such as mitomycin C are commonly used in glaucoma filtration surgery in patients at high risk of scarring postoperatively. Although ocular hypotony and maculopathy are known complications of such surgery, reversible and profound vision loss in association with hypotony induced optic disc swelling is rare. It has previously been suggested that hypotony related complications may be more common in myopes as they have reduced scleral rigidity. We present a case of ocular hypotony following mitomycin C assisted trabeculectomy with severe vision loss associated with disc swelling. We feel it highlights the dangers of antimetabolite use in patients with connective tissue disorders where there are inherent problems in wound healing and scleral rigidity. To our knowledge this is the first report of post filtration hypotony and reversible vision loss occurring as a complication of adjuvant therapy in a case of Ehlers-Danlos syndrome with reduced scleral rigidity.

### CASE REPORT

A 12 year old girl was referred to Moorfields Eye Hospital for a second opinion regarding her deteriorating vision following bilateral trabeculectomies with adjuvant mitomycin C for raised intraocular pressure.

At the age of 5 years, she was diagnosed as having megalocornea with ocular hypertension. Two years later, because of the persistent degree of IOP elevation (between 30–40 mm Hg), she was commenced on bilateral medical treatment. However, at the age of 11, she developed such severe problems with her topical treatment that surgery was considered necessary. In May 1996 right and subsequently left trabeculectomies were performed and during the procedures subconjunctival mitomycin C (0.3 mg/ml) was applied for 5 minutes. Her postoperative recovery was complicated by the development of ocular hypotony.

She was seen at Moorfields for the first time with progressive bilateral vision loss and recent onset of transient obscurations, 5 months after her filtration surgery and the onset of hypotony. Her visual acuities had fallen from right eye 20/20 ( $-0.5/-0.25 \times 180^\circ$ ) to hand movements (HM), and left eye 20/30 ( $-1.5$  DS) to counting fingers (CF). Her visual fields on confrontation with a red target showed an enlarged blind spot. Both eyes had large, draining, diffuse and avascular filtration blebs with signs of hypotony as evidenced by bilateral IOPs of 0 mm Hg, superficial corneal epithelial staining striae, and macular and choroidal folds. Both optic discs were swollen although no haemorrhages or cotton wool spots were observed. The patient was sensitive to light and good quality photographs could not be obtained. An ultrasound showed bilateral anterotemporal choroidal detachments involving the ciliary body (right larger than left) and axial lengths recorded as 23.0 mm in both eyes.

She underwent several surgical procedures. The day after she first presented, she underwent a right subconjunctival autologous blood

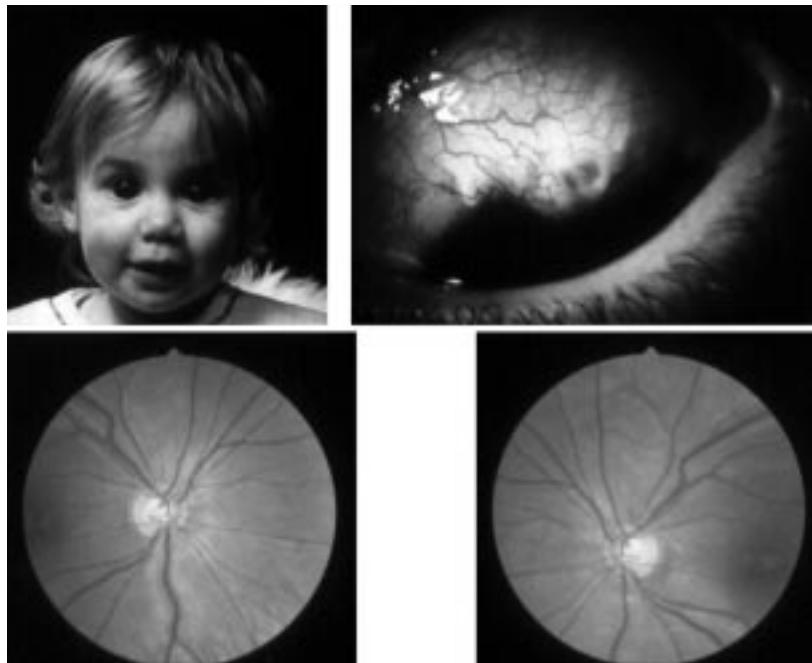
injection to the right bleb under general anaesthesia. The following day, however, her vision was worse with visual acuities being recorded as patchy areas of perception of light on the right and hand movements temporally on the left. Her IOPs were 4 and 0 mm Hg in the right and left respectively, and a greater degree of disc swelling (as judged by further elevation of the disc) was noted bilaterally. It was considered by a neurologist (GTP) that the disc swelling may itself be contributing to the visual loss, particularly in view of the transient visual obscurations which suggested critically impaired perfusion of the disc. To prevent even further vision loss, a lumbar puncture to reduce the CSF pressure was suggested, to provide short term improvement in disc perfusion, which it was hoped in the longer term would be helped by raising her intraocular pressure. She underwent further surgery to both her eyes for hypotony, later that evening, which comprised revision of both blebs with scleral patch grafts. This was preceded by a lumbar puncture under general anaesthesia at which there was an opening pressure of 22.5 cm H<sub>2</sub>O. A volume of 30 ml of CSF was removed and the closing pressure was recorded as 5.5 cm H<sub>2</sub>O with microbiological and biochemical analysis of CSF revealing no abnormality.

The day after surgery, the fourth day after initial presentation, examination revealed improved visual acuities of HM in both eyes with IOPs of 19 and 23 mm Hg in the right and left eye respectively. The disc swelling was felt to be reduced, and over the next few days improved gradually. Seven days after presentation, her IOPs had fallen to 0 and 8 mm Hg, right and left, respectively, and she was taken back to theatre for anterior chamber refilling with Healon-GV. Her IOPs normalised to around 20 mm Hg again 10 days later, with decreasing disc swelling, and a repeat ultrasound showed reduced choroidal detachments and axial lengths of 24.8 mm in the right and 24.6 mm in the left.

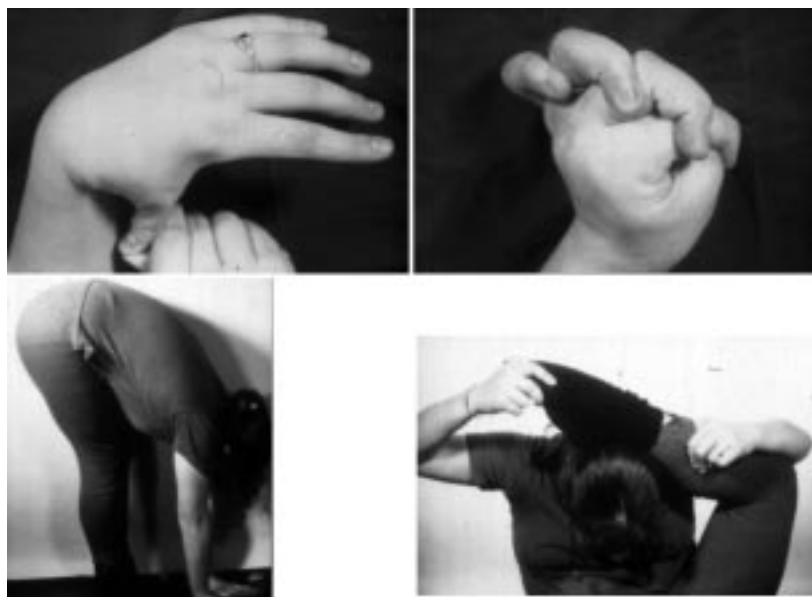She underwent one other further surgical procedure, 7 weeks after presentation, when her IOPs became elevated again at 35 and 28 mm Hg right and left respectively, to a degree where it was felt her optic discs would be compromised. Treatment consisted of needling procedures to both blebs with subconjunctival injections of 5-fluorouracil to reduce scar formation. Her IOPs responded very quickly to this final procedure and she remains on no antiglaucoma medication with normal intraocular pressures (less than 20 mm Hg) now 7 months after presentation. Both drainage blebs are Seidel negative with good evidence of aqueous drainage into the filtration blebs (Fig 1, top right). Her visual acuities and visual function have now recovered quite substantially. However she does have a relative afferent pupillary defect in the left eye, and her current refraction and visual acuities are right eye  $-1.0/-4.0 \times 05^\circ$  (RVA 20/30) and left eye  $-1.75/-6.5 \times 180^\circ$  (LVA 20/120). Her optic discs show no evidence of swelling, and she has neither choroidal detachments nor macular folds (Fig 1, bottom left and right) as confirmed on ultrasound.

### COMMENT

This young girl presented to us with severe ocular hypotony following bilateral primary glaucoma filtration surgery with mitomycin C. She developed vision loss, with episodes of transient obscurations attributable to hypotony and disc swelling. Her response to the initial surgery and subsequently to the corrective



**Figure 1** Although neonatal examination had been normal, our patient had been noted to have "large eyes" as a young child, as shown in this photograph taken at age 2 years (top left). Reversal of ocular hypotony occurred following filtration bleb revision with scleral patch grafts, with drainage into blebs apparent at 2 months (top right) postoperatively. Hypotony induced papilloedema resolved after surgery with no disc swelling apparent in right (bottom left) or left (bottom right) fundi, shown 7 months postoperatively.



**Figure 2** Our patient demonstrates joint hypermobility, a feature of Ehlers-Danlos syndrome. She can appose both thumbs to the flexor aspect of her wrist (top left), fold her fingers one over the other (top right), bend over to place her palms flat on the floor keeping her knees extended (bottom left), and put her ankles around her head (bottom right).

surgical procedures made us suspect that she had an inherent problem in wound healing and scleral rigidity, especially as she displayed such dramatic changes in axial lengths (1.6–1.8 mm difference in pre- and postoperative lengths). We therefore wondered if she had an underlying connective tissue disorder.

She was found to have Ehlers-Danlos syndrome type II (EDS II). Examination revealed her to have joint hypermobility (Fig 2), with a high joint hypermobility score (Table 1)<sup>1</sup> of 7/9. In addition, she showed evidence of skin striae in the lumbar region, thighs and breasts with a papyraceous scar on her right knee, and gave a history of bruising easily with prolonged bleeding when cut. Echocardiography however was normal, with a normal palate, no spinal defects, no arachnodactyly, and a normal arm span to height ratio. However, there was a strong family history of joint hypermobility.

EDS is a heterogeneous group of genetically determined disorders of connective tissue affecting skin, ligaments, joints, blood vessels, and internal organs, of which at least nine subtypes exist, with the following diagnostic triad: extensible skin (extreme examples being described in fairground artistes, such as the “elastic skin man” of the 19th century), connective tissue fragility, and hypermobile joints.<sup>2</sup> Although ocular complications in EDS are mostly associated with EDS type VI, a few ocular problems in EDS II have been documented such as prominent epicanthal folds, redundant skin on the upper eyelid, blue sclera, and the absence of periorbital fat.

The wound healing process in EDS II is known to be abnormal in the skin because of the anomalous development of scar formation due to aberrant collagen fibrils.<sup>3</sup> An abnormal healing response to the initial filtration surgery

in this young girl might have been exaggerated with the use of mitomycin C. Cutaneous wounds in EDS II initially appear with gaping edges—so called “fish mouths” and heal slowly, and when scar formation eventually occurs, are characteristically shiny and stretched—papyraceous. Our findings on initial exploration of the surgical site in the eye, in this case, revealed a friable, disintegrating scleral flap which would have permitted unguarded passage of aqueous into the subconjunctival space—hence the occurrence of hypotony when combined with a non-healing conjunctiva.

Ocular hypotony is associated with various complications<sup>4</sup> including hypotonous maculopathy, resulting in a permanent reduction in vision and acuity. This occurrence has previously been attributed to reduced scleral rigidity, as seen in young and myopic eyes<sup>5</sup> where a reduction in axial length has been documented following filtration surgery.<sup>6</sup> Another mechanism put forward for the vision loss in these eyes, has been compression of the submacular sclera due to the resting tone of the inferior oblique muscle and decreased scleral rigidity.<sup>7</sup>

The incidence of post filtration ocular hypotony following full thickness procedures is 17–41%.<sup>4</sup> This incidence was reduced significantly with the advent of guarded, partial thickness techniques, but the recent introduction of antiscarring agents such as mitomycin C and 5-fluorouracil<sup>8</sup> has led to its increase once again. We believe that our patient had a complex and extreme response to filtration surgery with adjuvant mitomycin C complicated by her reduced scleral rigidity secondary to EDS II, as evidenced by her large eyes and marked changes in axial length in association with reduction in intraocular pressure.

The development of severe vision loss in our patient was associated with the occurrence of transient obscurations and hypotonous disc swelling. Resolution of the disc swelling was 4–6 weeks after correction of the hypotony, and improvement in visual acuity was noted thereafter. Its natural history—that is, the pattern of resolution and visual recovery, is compatible with disc swelling. Visual loss associated with hypotonous maculopathy, however, may never recover despite reversal of hypotony.<sup>9</sup> Prolonged disc swelling in ocular hypotony is a recognised complication that is fortunately very rare. Experimental models have suggested that axoplasmic transport is delayed in cases of hypotony induced optic disc swelling giving rise to the same features histologically as seen with raised intracranial pressure papilloedema—for example, axonal swelling, accumulation of mitochondria, and cytoid body (cotton wool spots) formation.<sup>8</sup> The pathogenesis of disc swelling in ocular hypotony may be related to that occurring in raised intracranial pressure if it is postulated that in both situations the CSF pressure in the subarachnoid space around the optic nerve exceeds the perfusion pressure of the optic disc. Therefore in our patient, it was considered that lowering the CSF pressure to well below normal levels (<20 mm H<sub>2</sub>O) might provide temporary improvement in optic disc perfusion—hence our target for a very low closing pressure of 5.5 mm H<sub>2</sub>O in the lumbar puncture. Two previous reports of unilateral disc swelling following trabeculectomy also suggest that optic disc oedema could result from a disturbed equilibrium between ICP and IOP—though none of the patients described in these papers had hypotony or profound vision loss.<sup>9–10</sup>

The development of profound vision loss in association with hypotony induced optic disc swelling in our patient, was as a complication of mitomycin C assisted glaucoma filtration surgery. However, the degree of hypotony was most probably related to reduced scleral rigidity. We believe that her abnormal wound healing response and defective connective tissue contributed to the severity of the hypotony that followed initial surgery with mitomycin C. We suggest that antiproliferatives be used with extreme caution in patients who you suspect may have a connective tissue disorder. A quick screening procedure might include a joint hypermobility score as shown in Table 1. Patients with Ehlers-Danlos syndrome, such as our patient, may be at high risk of post filtration hypotony and developing “soft eyes” with sight threatening sequelae, as our case suggests that not only might they have elastic skin but also “elastic globes”.

Supported in part by the Wellcome Trust (grant no 048474) (to MFC), Guide Dogs for the Blind (MFC), and the Medical Research Council (to PTK).

M FRANCESCA CORDEIRO  
Wound Healing Research and Glaucoma Units,  
Institute of Ophthalmology and Moorfields Eye  
Hospital, London

GORDON T PLANT  
Moorfields Eye Hospital and National Hospital for  
Neurology and Neurosurgery, London

ANNE CHILD  
St George's Hospital Medical School, London

BARRY JONES  
Moorfields Eye Hospital, London

PENG T KHAW  
Wound Healing Research and Glaucoma Units,  
Institute of Ophthalmology and Moorfields Eye  
Hospital, London

**Table 1** Screen for joint hypermobility<sup>1</sup>

Action	Score (maximum = 9)
Passive hyperflexion of 5th metacarpophalangeal joint beyond 90°	1 point each hand (max = 2)
Passive hyperextension of thumb to flexor aspect of wrist	1 point each hand (max = 2)
Hyperextension of elbow beyond 10°	1 point each arm (max = 2)
Hyperextension of knee beyond 10°	1 point each leg (max = 2)
Forward flexion of trunk, palms flat on floor in front, knees in extension	1 point

Correspondence to: Peng T Khaw, Wound Healing Group and Glaucoma Unit, Pathology Department, Institute of Ophthalmology, Bath Street, London EC1V 9EL.

Accepted for publication 18 May 1999

- Child A. Joint hypermobility syndrome: inherited disorder of collagen synthesis. *J Rheumatol* 1986;13:239-43.
- Beighton P. *The Ehlers-Danlos syndrome*. London: William Heinemann Medical Books, 1970.
- Rizzo R, Bacarani Contri M, Micali G, et al. Familial Ehlers-Danlos syndrome type II: abnormal fibrillogenesis of dermal collagen. *Pediatr Dermatol* 1987;4:197-204.
- Schubert H. Postsurgical hypotony: relationship to fistulization, inflammation, chorioretinal lesions, and the vitreous. *Surv Ophthalmol* 1996;41:97-125.
- Stamper R, McMenemy M, Lieberman M. Hypotonous maculopathy after trabeculectomy with subconjunctival 5-fluorouracil. *Am J Ophthalmol* 1992;114:544-53.
- Jampel H, Pasquale L, Dibbernardo C. Hypotony maculopathy following trabeculectomy with mitomycin C. *Arch Ophthalmol* 1992;110:1049-50.
- American Association of Ophthalmologists. Decreased axial length in hypotonous eyes after filtration surgery. San Francisco: AAO Annual Meeting, November, 1993.
- Minckler D, Tso M, Zimmerman L. A light microscopic autoradiographic study of axoplasmic transport in the optic nerve head during ocular hypotony, increased intraocular pressure and papilledema. *Am J Ophthalmol* 1976;82:741-9.
- Greenfield DS, Wanichwecharungruang B, Liebmann JM, et al. Pseudotumour cerebri appearing with unilateral papilloedema after trabeculectomy. *Arch Ophthalmol* 1997;115:423-6.
- Kawasaki A, Purvin V. Unilateral optic disc edema following trabeculectomy. *J Neuro-Ophthalmol* 1998;18:121-3.

### Fluctuating oculomotor hyperfunction and hypofunction caused by aneurysmal compression of the third cranial nerve

EDITOR.—Aneurysms of the posterior communicating artery classically present with a painful progressive palsy of the third cranial nerve producing ptosis, ophthalmoparesis, and mydriasis. We present a case in which aneurysmal compression of the third nerve produced a variable ptosis and ophthalmoparesis without pupillary involvement in association with intermittent hyperfunction of the ipsilateral third nerve innervated muscles.

#### CASE REPORT

A 73 year old woman with a history of hypertension and ischaemic heart disease was referred to the eye department with a 3 week history of intermittent diplopia which she described as inconsistently horizontal, vertical, or oblique, and a 2 week history of right retro-orbital pain and difficulty in opening her right eye. The diplopia and ptosis were often worse in the mornings.

On examination the corrected visual acuities were right 6/6 and left 6/9. There was a very variable and apparently fatiguable right ptosis which was occasionally replaced by right upper lid retraction (Fig 1). The results of ocular motility testing were inconsistent, ranging from 4 prism dioptres of exotropia to 25 prism dioptres of esotropia in the primary position with between 3 and 7 prism dioptres of left hypertropia. There was variable limitation of elevation and depression of the right eye and occasional right upper lid retraction on downgaze. On upgaze, the deviation reversed to become a right hypertropia due to right superior rectus overaction (Fig 1).

Magnetic resonance imaging and angiography were performed showing a 6-7 mm diameter saccular aneurysm arising from the

intracranial internal carotid artery at the level of the posterior communicating artery. Attempted embolisation of the aneurysm failed owing to a focal stenosis at the origin of the right internal carotid artery and the patient underwent uneventful clipping of the aneurysm instead. There was a rapid improvement in the ophthalmoparesis following clipping and 6 weeks postoperatively all the neurological signs had resolved.

#### COMMENT

The early recognition of oculomotor nerve compression by a posterior communicating artery aneurysm is essential given that the mean interval between the onset of diplopia and bleeding is 4 weeks in patients who develop a subarachnoid haemorrhage.<sup>1</sup> Although the retro-orbital pain was typical, this case is unusual for two reasons. Firstly the ptosis and ophthalmoparesis were notably variable (Fig 1). Secondly, episodes of right upper lid retraction, esotropia, and hypertropia were observed (Fig 1). Although modest variability of symptoms (for example, intermittent diplopia<sup>2</sup>) has previously been described, we can find no reports in the literature of such marked fluctuations in ptosis due to third nerve compression. Furthermore, in this case upper lid retraction and, on eye movement testing, esotropia and hypertropia—that is, excessive activity in third nerve innervated muscles, was observed.

A similar phenomenon of co-existing inappropriate neural discharge and block is seen in hemifacial spasm<sup>3</sup> where compression of the seventh nerve by abnormal vessels produces hemifacial spasm and mild facial weakness. Although there is some controversy as to whether it is the mechanical irritation of the facial nerve or secondary hyperexcitability of

the facial nerve nucleus that is responsible for hemifacial spasm,<sup>4,5</sup> it is now accepted by most authors that compression of the facial nerve is the causative factor.<sup>4,6</sup> A precise intra-operative correlation between decompression of the facial nerve and electromyographic disappearance of abnormal facial muscle activity has been demonstrated<sup>7</sup> although the facial weakness has been reported to take longer to resolve.<sup>5</sup> An analogous situation of aneurysmal compression causing alternating ophthalmoparesis and third nerve hyperactivity in the case reported here is suggested by the similar course of resolution to that seen following decompression of the facial nerve for hemifacial spasm—the third nerve hyperactivity resolved immediately following clipping of the aneurysm while the ophthalmoparesis improved rapidly but took several weeks to resolve fully. The degree of third nerve hypofunction was, however, much greater than the mild facial weakness seen in hemifacial spasm and may have been due to the greater degree of compression of the third nerve in this case.

This case is important for two reasons. Firstly, this is the first report of compression of the third cranial nerve producing alternating oculomotor hypo- and hyperfunction as a result of a compressive lesion. Secondly, it emphasises the importance of excluding compression by intracranial aneurysm in a patient with variable signs which could be explained by a partial third nerve palsy.

MARGARET R DAYAN

JOHN S ELSTON

Oxford Eye Hospital, Radcliffe Infirmary, Woodstock Road, Oxford OX2 6HE

Correspondence to: Miss Dayan

Accepted for publication 31 May 1999

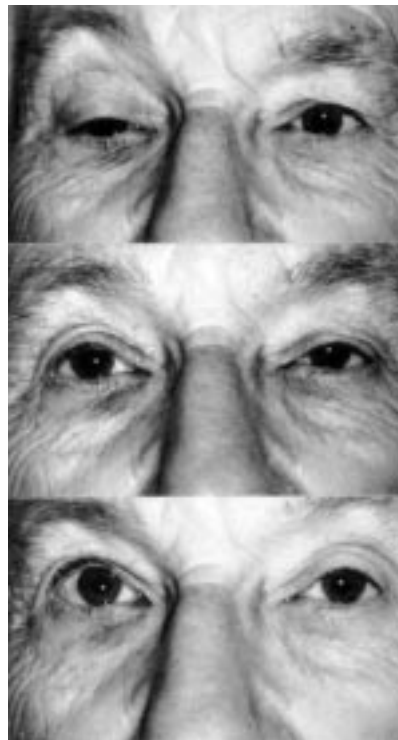

Figure 1 (Top) Right ptosis with frontalis overaction and right hypotropia. (Middle) Right ptosis has resolved. (Bottom) A few minutes later there is right upper lid retraction and right hypertropia indicating right third nerve hyperfunction.

- Okawara SH. Warning signs prior to rupture of an intracranial aneurysm. *J Neurosurg* 1973;38:575-80.
- Bartleson JD, Trautmann JC, Sundt TM. Minimal oculomotor nerve paresis secondary to unruptured intracranial aneurysm. *Arch Neurol* 1986;43:1015-24.
- Frohman EM, Zee DS. Ocular neuromyotonia: clinical features, physiological mechanisms and response to therapy. *Ann Neurol* 1995;37:620-6.
- Müller AR, Jannetta PJ. On the origin of synkinesis in hemifacial spasm: results of intracranial recordings. *J Neurosurg* 1984;61:569-76.
- Schulze-Bonhage A, Fenbert A. Electrophysiological recording in bilateral hemifacial spasm. *J Neurol Neurosurg Psychiatry* 1998;65:408-10.
- Ryu H, Yamamoto S, Sugiyama K, et al. Hemifacial spasm caused by vascular compression of the distal portion of the facial nerve. *J Neurosurg* 1998;88:605-9.
- Haines SJ, Torres F. Intraoperative monitoring of the facial nerve during decompressive surgery for hemifacial spasm. *J Neurosurg* 1991;74:254-7.

### Late onset of Leber's hereditary optic neuropathy in HIV infection

EDITOR.—We report a case of late onset of Leber's hereditary optic neuropathy (LHON) in a 59 year old patient with HIV infection being treated long term since 1991 with zidovudine. The onset and course of the patient's eye disease as well as the diagnostic process were analysed. Molecular genetic testing revealed the mitochondrial DNA (mtDNA) mutation in nucleotide position 11778 confirming the diagnosis of LHON. In our patient late disease expression may be interpreted as a result of the rare combination of the 11778 mutation with HIV infection and long term zidovudine treatment. This is the first report on a patient with LHON suffering from additional HIV infection.

## CASE REPORT

A 59 year old white man was admitted to our outpatient department in July 1997 with acute onset of vision loss in his left eye within the previous 2 weeks. The patient had been diagnosed with HIV infection in 1991. No opportunistic infections defining AIDS had been present so far. Antiretroviral therapy consisted of zidovudine since June 1991 as well as additional indinavir and nevirapine since January 1997. Best corrected visual acuity was right eye 20/20 and left eye 6/20. Further ophthalmic examination revealed a left afferent pupillary defect and an absolute central scotoma in the left eye. Indocyanine green angiography and fluorescein angiography disclosed a slight oedema of the optic disc without leakage. Visual evoked potentials (VEP) of the left eye showed reduced central amplitudes and prolonged latencies. Ophthalmic examination of the right eye at the time of presentation was normal.

The CD4+ T lymphocyte count was 360 cells  $\times 10^6/l$  and HIV RNA in plasma was 8500 copies/ml. Neurological examination, including analysis of cerebrospinal fluid, was normal. Subsequent magnetic resonance imaging revealed normal cavernous sinuses and unremarkable optic nerves. No masses were seen in the orbits.

High dose steroid treatment on the basis of a presumptive diagnosis of optic neuritis could not prevent further progression of vision loss to hand movements in the patient's left eye. In October 1997 the patient noticed similar symptoms in his right eye. Visual acuity was reduced to right eye 12/20.

On specific questioning the patient reported five male relatives—one of his brothers and four cousins—who had lost vision in early adulthood. Molecular genetic testing of a blood sample to investigate the presence of mitochondrial DNA (mtDNA) mutations yielded a mutation at position 11778, homoplasmic to the level of detection, confirming the diagnosis of Leber's hereditary optic neuropathy (LHON). Therefore the patient was specifically asked for past or present additional medical or environmental factors postulated to trigger LHON. The patient denied any alcohol or tobacco consumption. Exposure to chemicals, toxins, or dangerous factory processes was not reported. Significantly larger amounts of foods with high cyanide content were not described. Additional metabolic or neurological diseases were not present.

## COMMENT

LHON is a bilateral acute or subacute optic neuropathy caused by mutations in the mtDNA. Point mutations of the mtDNA at nucleotide position 11778, 3460, and 14484 involving NADH dehydrogenase (ND) subunits 1, 4, and 6, respectively, of respiratory chain complex I, are responsible for the majority of cases worldwide. These primary mitochondrial mutations are necessary but not sufficient for LHON disease expression. Only 30% of males and 10% of females carrying the 11778 mutation actually suffer visual loss.<sup>1</sup> Therefore other genetic or epigenetic factors must play a role in disease penetrance although they are poorly defined at the present time. Proposed determinants of disease penetrance include heteroplasmy, secondary mitochondrial mutations, nutritional factors, metabolic disease, and toxic exposure.

Apart from the primary mutation our patient was only exposed to two epigenetic factors known to interfere with mitochondrial function. In previous studies HIV<sup>2</sup> itself as well as zidovudine<sup>3-5</sup> were demonstrated to affect

mitochondrial integrity. Mitochondrial changes depend more on the duration of zidovudine application than on the applied dose.<sup>4</sup> The onset of visual loss in LHON typically occurs between the ages of 15 and 35 years in most pedigrees. We hypothesise that the exceptionally long period of zidovudine treatment since diagnosis of HIV infection in 1991 and/or the infection itself may account for the unusual late expression of LHON in our patient. This is the first report on a patient with LHON suffering from additional HIV infection.

CHRISTOPH LÜKE

Klinik und Poliklinik für Augenheilkunde

OLIVER A CORNELI

Klinik I für Innere Medizin,

Universität Köln,

Germany

JULIA FRICKE

ELFI LEHRER

KARL ULRICH BARTZ-SCHMIDT

Klinik und Poliklinik für Augenheilkunde,

Universität

Köln, Germany

BERND WISSINGER

Molekulargenetisches Labor, Universitätsaugenklinik

Tübingen, Germany

RICHARD BRUNNER

Klinik und Poliklinik für Augenheilkunde,

Universität

Köln, Germany

Correspondence to: Christoph Lüke, Klinik und Poliklinik für Augenheilkunde, Universität Köln, Joseph-Stelzmann Strasse 9, D-50924 Köln, Germany

Accepted for publication 17 June 1999

- Harding AE, Sweeney MG, Govan GG, et al. Pedigree analysis in Leber's hereditary optic neuropathy families with a pathologic mtDNA mutation. *Am J Hum Genet* 1995;57:77-86.
- Macreadie IG, Thorburn DR, Kirby DM, et al. HIV-1 protein Vpr causes gross mitochondrial dysfunction in the yeast *Saccharomyces cerevisiae*. *FEBS Lett* 1997;410:145-9.
- Lewis W, Dalakas MC. Mitochondrial toxicity of antiviral drugs. *Nat Med* 1995;1:417-22.
- Schröder JM, Kaldenbach T, Piroth W. Nuclear and mitochondrial changes of co-cultivated spinal cord, spinal ganglia and muscle fibers following treatment with various doses of zidovudine. *Acta Neuropathol* 1996;92:138-49.
- Peters BS, Winer J, Landon DN, et al. Mitochondrial myopathy associated with chronic zidovudine therapy in AIDS. *Q J Med* 1993;86:5-15.

### Acute onset comitant esotropia as presenting sign of demyelinating disease

EDITOR,—Comitant esotropia is most often acquired at an early age, and is generally benign. However, acute comitant esotropia has also been reported in patients with intracranial diseases including hydrocephalus, Arnold-Chiari malformations, and central nervous system tumours. I describe a case of acute onset comitant esotropia associated with acute demyelinating disease.

## CASE REPORT

An 11 year old boy was referred for evaluation of diplopia. The patient stated he woke up the previous day with double vision. He denied decreased visual acuity, photophobia, pain with eye movements, headache, or nausea and vomiting. One week before the onset of esotropia, he had an upper respiratory infection with a fever that resolved without antibiotics. His mother also noted that he had been very tired over the previous week with episodes of falling asleep during the day at home and school, and one episode of dizziness. He was an otherwise healthy child on no medications and with no allergies.

On examination, visual acuity without correction was 20/20 bilaterally. Pupils were equally reactive without an afferent pupillary defect. Extraocular motility was full, and saccades were grossly normal and symmetrical. Alternate cover testing revealed a comitant 16 prism dioptre esotropia for both near and distance fixation. He was able to fuse with the appropriate prism in place. Slit lamp examination was unremarkable. Dilated retinal examination revealed pink and sharp optic nerves with no papilloedema. Macula, vessels, and retinal periphery were all within normal limits.

The patient underwent magnetic resonance imaging (MRI) the next day (Fig 1). The study revealed a hyperintense signal on T-1 weighted imaging in the area of the periaqueductal grey mater in the midbrain. The lesion was consistent with a demyelinating disease including acute disseminating encephalomyelitis or multiple sclerosis. The patient was referred for neurological evaluation and lumbar puncture the next day. However, on presentation to the paediatric neurologist, the patient noted that his diplopia had gradually resolved. Lumbar puncture was not performed because neurological examination was entirely unremarkable. Follow up ocular examination revealed normal ocular alignment and motility.

## COMMENT

Acute onset comitant esotropia is most commonly benign when occurring in infancy or early childhood. Examination to rule out a paretic deviation is essential. However, acute onset of comitant esotropia has also been reported in association with serious neurological disease. It has been reported in association with hydrocephalus.<sup>1</sup> These patients generally have obvious neurological problems associated with hydrocephalus, and are not a diagnostic dilemma.<sup>2</sup> They may have a meningomyelocele or encephalocele, and an A-pattern esotropia.<sup>1,2</sup> In cases of comitant esotropia associated with shunt failure, all the esotropias resolve when the shunts are revised. These patients do not have A-pattern

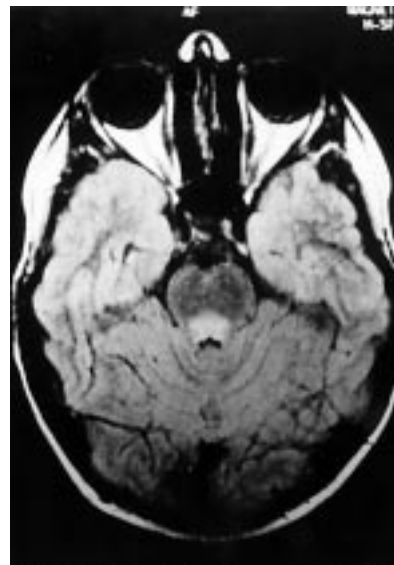


Figure 1 Magnetic resonance imaging (FLAIR inversion recovery sequence) of patient with acute onset of comitant esotropia. A hyperintense signal is apparent in the periaqueductal grey of the midbrain and pons consistent with a demyelinating lesion.

esotropias. Patients may not necessarily present with papilloedema even when hydrocephalus is present.<sup>1</sup> In the present case, no hydrocephalus was noted on neuroradiographic study.

Arnold-Chiari malformation has also been reported in association with acute comitant esotropia.<sup>2,3</sup> These cases may present with an A-pattern, co-existing nystagmus and hydrocephalus. Arnold-Chiari malformations sometimes do not manifest until late childhood or adulthood, and can be mild. Neuroradiographic study did not reveal Arnold-Chiari malformation in this patient.

Central nervous system tumours have also been reported in association with acute onset comitant esotropias.<sup>1,2,4</sup> Tumours in this group include cerebellar astrocytomas, and medulloblastomas, as well as pontine gliomas.<sup>1</sup> An A-pattern esotropia is unusual in these patients.<sup>2</sup> In a report by Williams and Hoyt, three of their six patients had some form of nystagmus associated with the comitant esotropia. They suggested neurological evaluation in any patient with both nystagmus and acute comitant esotropia. They further suggested evaluation for any patient with acute comitant esotropia if ocular motor fusion can not be established with prism or surgery.<sup>1</sup>

Acute comitant esotropia has been associated rarely with a hypertensive haemorrhage in the thalamus.<sup>5</sup> However, these patients also present with other neurological signs leading rapidly to the diagnosis. In addition, acute comitant esotropia has been reported rarely with myasthenia gravis and seizures.<sup>4,6,7</sup>

This patient had a brainstem lesion that was consistent with an acute central nervous system demyelination. Its location in the midbrain may have interfered with neurons associated with horizontal gaze centres or vergence mechanisms. This is the first reported case of acute demyelinating disease presenting with acute comitant esotropia. Acute disseminated encephalomyelitis is generally post viral and is characterised by abrupt headache fever, drowsiness, and focal neurological dysfunction. Cerebrospinal fluid analysis may exhibit pleocytosis. It may resolve completely or may result in permanent impairment and seizures.<sup>8</sup> Whether this lesion represents a localised variant of acute disseminated encephalomyelitis or multiple sclerosis is not clear. However, cases of acute onset comitant esotropia with suspicious presentations warrant neuroimaging to rule out intracranial

pathology including central nervous system demyelinating lesions.

BARRY N WASSERMAN

Chester County Eye Care Associates, 606 East Marshall Street, Suite 104, West Chester, PA 19380, USA

Accepted for publication 8 June 1999

- 1 Williams AS, Hoyt CS. Acute comitant esotropia in children with brain tumors. *Arch Ophthalmol* 1989;107:376-8.
- 2 Hoyt CS, Fredrick DR. Serious neurologic disease presenting as comitant esotropia. In: Rosenbaum AL, Santiago PA, eds. *Clinical strabismus management*. Philadelphia: Saunders, 1999:152-8.
- 3 Lewis AR, Kline LB, Sharpe JA. Acquired esotropia due to Arnold-Chiari I malformation. *J Neuro-ophthalmol* 1996;16:49-54.
- 4 Astle WF, Miller SJ. Acute comitant esotropia: a sign of intracranial disease. *Can J Ophthalmol* 1994;29:151-4.
- 5 Gomez CR, Gomez SM, Selhorst JB. Acute thalamic esotropia. *Neurology* 1988;38:1759-62.
- 6 Davidson JL, Rosenbaum AL, McCall LC. Strabismus surgery in patients with myasthenia. *J Pediatr Ophthalmol Strabismus* 1993;30:292-5.
- 7 Tischler AM, Rees MC, Dunn HG, et al. Esotropia and epileptic eye deviation. *Can J Ophthalmol* 1996;31:369-72.
- 8 Brodsky MC, Baker RS, Hamed LM. Acute disseminated encephalomyelitis. In: *Pediatric neuro-ophthalmology*. New York: Springer, 1996:99-100.