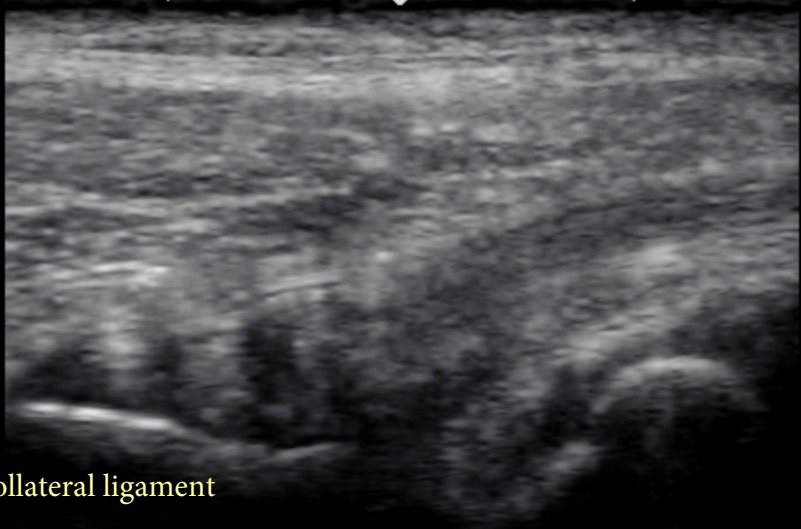


T Pure

P100%



11LW4

T7.6

21fps

Qscan

G86

DR80

Origin of the medial collateral ligament

(Inflammation appears as dark areas)

LEFT STIFLE

ORIGIN OF MED CL

4

#2