

Mouse Anti-Podoplanin [D2-40]: MC0329, MC0329RTU7

Intended Use: For Research Use Only

Description: D2-40 (Podoplanin and Lymphatic Endothelial Cell Marker) is expressed in lymphatic endothelium, and was found in lymphangiomas, Kaposi sarcomas, a subset of angiosarcomas with lymphatic differentiation, epithelioid mesotheliomas, hemangioblastomas, seminomas. D2-40 is a useful marker in identification of lymphatic invasion of primary tumors. D2-40 has also known to be a specific marker for cells of mesothelial origin e.g. mesothelioma.

Specifications

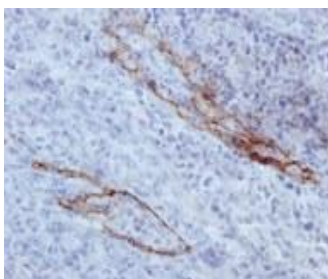
Clone: D2-40
Source: Mouse
Isotype: IgG1
Reactivity: Human
Localization: Cytoplasm and some membrane
Formulation: Antibody in PBS pH 7.4, containing BSA and $\leq 0.09\%$ sodium azide (NaN₃)
Storage: Store at 2°- 8°C
Applications: IHC
Package:

Description	Catalog No.	Size
Podoplanin [D2-40] Concentrated	MC0329	1 ml
Podoplanin [D2-40] Prediluted	MC0329RTU7	7 ml

IHC Procedure*

Positive Control Tissue: Lymph node
Concentrated Dilution: 50-200
Pretreatment: Citrate pH6.0 or EDTA pH8.0, 15 minutes using Pressure Cooker, or 30-60 minutes using water bath at 95°-99°C
Incubation Time and Temp: 30-60 minutes @ RT
Detection: Refer to the detection system manual

* Result should be confirmed by an established diagnostic procedure.



FFPE Human lymphoid node tissue stained with anti-D2-40 using DAB

References:

1. Lymphatic Vessel Density and Vascular Endothelial Growth Factor Expression in Squamous Cell Carcinomas of Lip and Oral Cavity: A Clinicopathological Analysis with Immunohistochemistry Using Antibodies to D2-40, VEGF-C and VEGF-D. Watanabe S, et al. Yonago Acta Med. 2013 Mar;56(1):29-37.
2. Intranodal hemorrhagic spindle cell tumor with amianthoid fibers - report of a case with emphasis to mast cell reaction and d2-40 expression. Cimpean AM, et al. In Vivo. 2013 May-Jun;27(3):395-9.
3. Diagnostic utility of Fli-1 and D2-40 in distinguishing atypical fibroxanthoma from angiosarcoma. Cuda J, et al. Am J Dermatopathol. 2013 May;35(3):316-8
4. Expression of podoplanin/D2-40 in pericryptal stromal cells in superficial colorectal epithelial neoplasia. Nakayama H, et al. Med Mol Morphol. 2013 Mar;46(1):20-3
5. Clinicopathological significance of lymphatic vessel density marked by D2-40 and E-cadherin expression in non-small-cell lung cancer. Jin S, Zhu W, et al. Med Oncol. 2012 Dec;29(5):3157-61.