

Ehlers–Danlos syndrome: case report and an electron microscopy study

M. Carlesimo · G. Cortesi · A. Gamba ·
A. Narcisi · F. Turturro · S. Raffa ·
M. R. Torrisi · G. Camplone

Received: 14 September 2010 / Accepted: 30 December 2010 / Published online: 9 February 2011
© Springer-Verlag 2011

Abstract Ehlers–Danlos syndrome (EDS) type III is a inherited connective tissue disorders characterized by extensibility of the skin, hypermobility of the joints, chronic pain, tissue fragility, easy bruising, and delayed wound healing with result of atrophic scars. The patients report commonly a history of recurrent dislocations of the shoulders and knees after low-impact trauma, chronic joint pain, and early osteoarthritis, which lead to diagnosis. The pathogenesis of this condition is unknown, and the diagnosis is generally made in adult age, based only on clinical criteria. In this report, we describe a case of a 50-year-old woman with a 30-year history of recurrent dislocations and atrophic scars. We performed diagnosis of EDS type III after a complete clinical and instrumental evaluation, comprising of histological and electron microscopic studies, that highlighted collagen abnormalities.

Keywords Ehlers–Danlos syndrome · Collagen · Joints hypermobility · Chronic pain · Electron microscopy

Introduction

Ehlers–Danlos (EDS) is a heterogeneous group of inherited disorders of connective tissue. Its prevalence is comprised between 1:560.000 and 1:5.000, [1] but this is underestimated because the symptoms are so minimal in some patients that the diagnosis is not done in your life. The EDS type III, or hypermobility type, is one of the six subtypes of the Villefranche classification proposed in 1997.

The etiopathogenesis is still unclear, and the diagnosis is based on clinical features because in this type there are no pathognomonic genetic or laboratory tests. The major criteria of diagnosis are the skin laxity, velvet skin, and the joint hypermobility; the minor ones are recurrent joint dislocations and chronic limb or joint pain.[2, 3] It has been considered for long time a mild form of EDS, but this conception is not correct because it is the more invalid one for the muscular impairment, and in some patients, it has been described vascular and cardiac disfunction, including mitral valve prolapse, aortic dilatation, and aortic dissection/rupture [4].

This article describes a case of a patient affected by EDS syndrome type III diagnosed with clinical features. We performed also a histological biopsy and an electron microscopy that highlighted collagen abnormalities.

Case report

In January 2009, a 56-year-old female patient was referred to our department for a diagnosis about her clinical

M. Carlesimo · G. Cortesi · A. Gamba · A. Narcisi ·
G. Camplone
Dermatology Unit, S. Andrea Hospital, II School of Medicine,
University of Rome ‘Sapienza’, Rome, Italy

S. Raffa · M. R. Torrisi
Department of Experimental Medicine, S. Andrea Hospital,
II School of Medicine, University of Rome ‘Sapienza’,
Rome, Italy

F. Turturro
Department of Orthopaedic, S. Andrea Hospital,
II School of Medicine, University of Rome ‘Sapienza’,
Rome, Italy

G. Cortesi (✉)
U.O.C. Dermatology, II School of Medicine, University of Rome
‘Sapienza’, Via Di Grottarossa, 1035, 00189 Rome, Italy
e-mail: giorgia.cortesi@libero.it

situation. The patient reported a 30-year history of chronic pain affecting her back, wrists, shoulders, knees and hips, associated with multiple dislocations of the temporomandibular joints, the small hand joints, and interphalangeal joints of the toes. Between 1987 and 1999, she underwent operations about ligament rebuilding. The past medical history revealed also tiredness, asthenia, insomnia, episodic dyspnoea, dyspareunia, frank prolapse (probably arose from collapse of fibro-elastic tissues of pelvis), rachis arthrosis, and spread tenosynovitis.

The clinical examination confirmed dislocations of the joint mentioned, ability to hyperextend and hyperabduct the fingers, as well as pronounced hypermobility of elbows, feet, and toes. It could be noted also the presence of breast and abdominal skin striae, a mild degree of skin extensibility, and the presence of various atrophic scarring located mainly on her trunk and inferior legs (Fig. 1).

All routine laboratory tests were in the normal range. A skin biopsy was performed on right that demonstrated abnormal variability in the diameter of collagen fibers. This finding is confirmed by ultrastructural examination of the dermis at higher magnification that showed collagen fibrils characterized by great variability of diameters (ranging from 35 to 99 nm) and isolated composite fibrils with “flower-like” cross sections (Fig. 2).

In the hypothesis of an Ehlers–Danlos syndrome, the patient was evaluated by numerous physicians. Cardiological evaluation confirmed the hypertension syndrome and the presence of small signs of heart failure by an eco-color-doppler examination; a pneumological evaluation with the plethysmography showed a small restrictive syndrome; an urologic evaluation with a urodynamic test that revealed an urinary incontinence; a neurological evaluation with an angio RM intracranic that showed signs of ischemia in under-cortex area and signs of occlusion in carotid artery and basilar artery. Optician consultation revealed the diagnosis of iridocyclitis right eye, in a patient with a history of conjunctivitis and episodic ocular hypertension. Orthopaedic consultation confirmed the dislocation of both the temporomandibular joints, the small hand joints, and

interphalangeal joints of the toes, and the presence of a joint hypermobility assessed using the Beighton score system that showed a score between 4 and 5. Physiatric consultation suggested continuing the use of plantars, and, when is present pain, the use of Canadian staff.

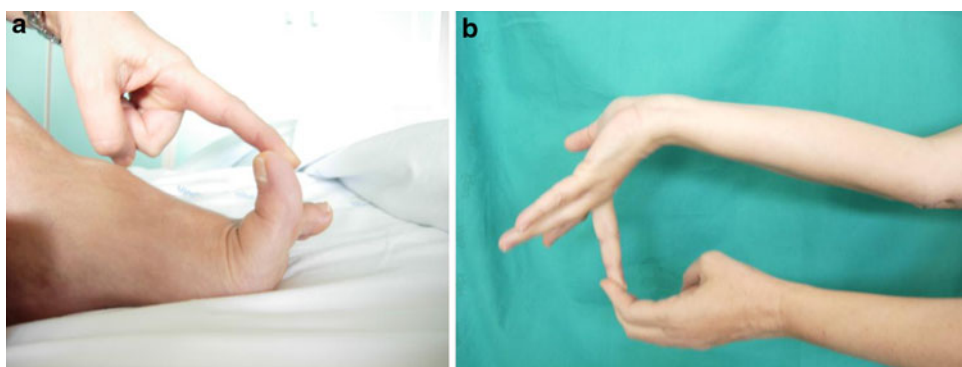
Therefore, the diagnosis of Ehlers–Danlos syndrome type III was finally made on clinical grounds, supported also by geneticist consultation. Also, genetic analysis was negative for the detection of molecular defect noted in the other type of ED syndrome.

Discussion

Ehlers–Danlos syndrome is a heritable group of connective tissue disorders characterized by abnormal collagen synthesis and cross-linking. Among all connective tissue disorders, this is thought to be the most prevalent.

Edvard Ehlers (1863–1937), a Danish dermatologist, and Henri-Alexandre Danlos (1844–1912), a French dermatologist, first described patients with hyperextensibility of the skin and hypermobility of joints, associated with tissue fragility and recurrent scarring. So in 1936, an English physician, Frederick Parkes-Weber, suggested to name this syndrome, Ehlers–Danlos syndrome. Classification of EDS began in the late 1960s, and in 1988, an international nosology of connective tissue defined nine subcategories of EDS [1]. Recent knowledge and increased medical expertise consented a simplification of EDS classification. It has been revised into six major types according to the Villefranche nosology: more frequent are EDS types I and II (AD) that show the cardinal manifestations to a severe and moderate degree, respectively; EDS type III, hypermobility type (AD) characterized by marked articular hypermobility, moderate dermal hyperextensibility, and minimal scarring. The poorer prognosis is for the EDS type IV (vascular type) that is characterized by a heterogeneous inheritance pattern with variable manifestations, and a predisposition toward severe bruising and vascular and colonic ruptures. EDS type V (X-linked type),

Fig. 1 **a** Finger's hyperextension; **b** finger's hyperabduction



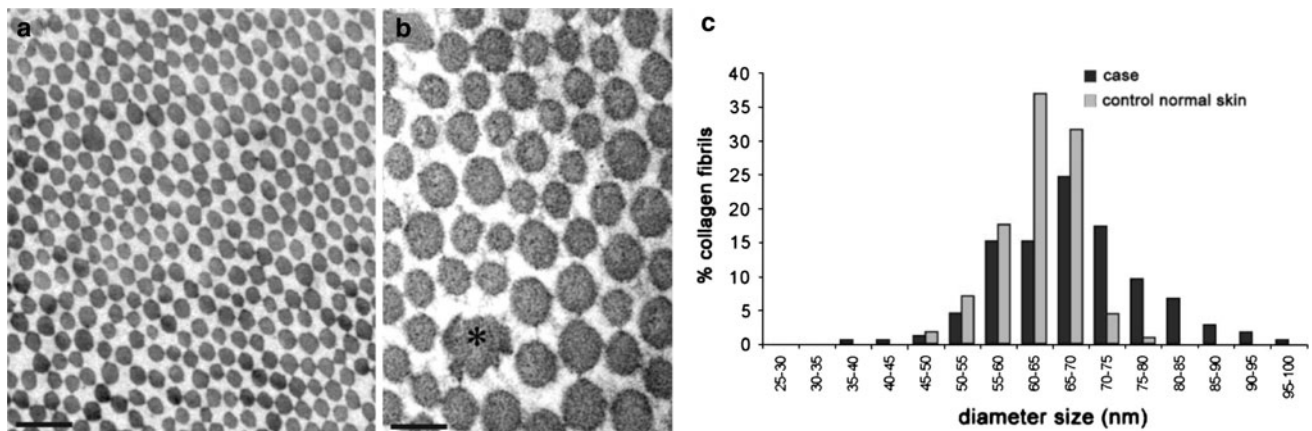


Fig. 2 Electronic microscopy **a, b** heterogeneity in the size of the collagen fibrils and composite fibrils with “flower-like” cross sections (*asterisk*). [TEM, uranyl acetate/lead citrate; *bars* 200 nm (**a**), 100 nm (**b**)]; **c** quantitation of diameter distribution of collagen fibrils in Ehlers–Danlos case compared to dermal sample from skin of healthy subject. At least 250 fibrils, randomly taken for each sample,

an X-linked inheritance pattern, with moderate manifestations, and EDS type VI (arthrocalasia multiplex congenita) characterized by a heterogeneous inheritance pattern and marked joint laxity associated with multiple dislocations, short stature and mandibular micrognathia [5].

Etiopathogenesis is still unclear; molecular defects affecting the synthesis, structure or function of the fibrillar collagens types I, III, and V have been described in EDS [1]. The diagnosis is based on clinical features; in fact, there are no pathognomonic laboratory tests and no specific pathologic features in most types. The diagnosis is full fit by the presence of one of three major criteria (skin hyperextensibility, tissue fragility, and joint hypermobility), while the presence of one or more minor criteria (recurrent joint dislocations, chronic limb or joint pain, positive family history of EDS, hypermobility type, easy bruising, functional bowel disorders as functional gastritis, irritable bowel syndrome, neurally mediated hypotension or postural orthostatic tachycardia) [4] is necessary to distinguish a specific type of EDS [2].

Hypermobility type (previously type III) is dominated by joint hypermobility, with resulting recurrent subluxations (mainly shoulder, patella, and temporomandibular joint), chronic joint pain, early arthrosis and minimal cutaneous involvement. In 5–10% of individuals with this disorder, there is a mutation in one copy of the TNXB gene, which encodes for the tenascin-X protein in collagen; tenascin-X provides structure, strength, and flexibility to connective tissue [3].

Narcisi et al. [7] characterized a glycine substitution in the type III collagen molecule in a family with typical features of hypermobile EDS. This type of mutation is normally associated with the vascular, but not with the

were measured. The digital images of ultrathin sections were recorded with a Morgagni 268D Electron Microscopy (FEI Company, Hillsboro, OR), equipped with a Mega View II charge-coupled device camera (SIS, Soft Imaging System GmbH, Munster, Germany) and analyzed with AnalySIS software (SIS)

hypermobility EDS phenotype. Further studies are required to determine whether other such families are also caused by COL3A1 mutation [6, 7].

The joint hypermobility can be assessed using the Beighton scale that tests five performances of joint mobility and has a maximum score of nine points. A score of at least five out of nine determines joint hypermobility [3, 8]. The skin is normal or only slightly increased extensibility. Soft skin is subjectively assessed, preferably in an area in which moisturizer has not been applied. Skin hyperextensibility is assessed at a site lacking excess or loose skin and without evidence of prior trauma by gently pulling until resistance is met. An ideal location is the volar surface of the forearm, where the upper limit of normal extensibility is 1–1.5 cm. Extensor surfaces of joints have excess skin and should not be used [4].

Orthopaedic complications such joint pain, joint swelling, joint dislocation, osteoporosis, back pain, with walking, and hand function disability are the main problems [5], but other organ systems (especially gastrointestinal and cardiovascular) are frequently involved. Functional bowel disorders are common and underrecognized, affecting up to 50% of patients. Approximately one-third to one-half of individuals report atypical chest pain, palpitations at rest or on exertion, and/or orthostatic intolerance. Holter monitoring usually shows normal sinus rhythm, but sometimes reveals premature atrial complexes or paroxysmal supraventricular tachycardia. Tilt table testing may reveal neurally mediated hypotension (NMH) and/or postural orthostatic tachycardia syndrome (POTS) [4]. Aortic root dilatation, usually of a mild degree, occurs in one-quarter to one-third of patients. The long-term stability or progression and ultimate prognosis are not yet known [4].

In a comparison with other forms of EDS, hypermobility type seems to be the most commonly association with mobility impairment and the most debilitating when compared to musculoskeletal function [9].

Management is largely supportive (physiotherapy, rehabilitation) and preventative (avoiding certain sports). It is less commonly surgical, although historically arthrodesis was common [9]. Surgery may be necessary to correct dislocated joints but it often does not completely resolve the handicap and physical therapy has an important place in management [10].

Thus, we want to present this case because physicians must be aware of this syndrome to offer the best management, with the appropriate use of Orthopaedic devices, specific strengthening routines, education in proper body mechanics, and assistive devices, to prevent joint dislocation and subluxations responsible for pain and handicap [10]. We want also to describe the electronic study, which is not routinely made in this pathology but, as in our case, can demonstrate collagen abnormalities and can be a comfort in the diagnosis.

References

1. Parapia LA, Jackson C (2008) Ehlers-Danlos syndrome: a historical review. *Br J Haematol* 141:32–35
2. Eisenbeiss C, Martinez A, Hagerdon M (2008) Reduced skin thickness: a new minor diagnostic criterion for the classical and hypermobility types of Ehlers-Danlos syndrome. *Br J Dermatol* 149:850–852
3. Sood V, Robinson DA, Suri I (2009) Difficult intubation during rapid sequence induction in a parturient with Ehlers-Danlos syndrome, hypermobility type. *Int J Obstet Anesth* 18(4):408–412
4. Levy HP (2010) Ehlers-Danlos syndrome, hypermobility type. In: Pagon RA, Bird TC, Dolan CR, Stephens K (eds) *GeneReviews* [Internet]. Seattle (WA): University of Washington, Seattle, 1993–2004 Oct 22 [updated 2010 Apr 27]
5. Stanitski D, Nadjarian R, Stanitski C (2000) Orthopaedic manifestations of Ehlers-Danlos syndrome. *Clin Orthop Relat Res* 376:213–221
6. Burrows NP (1999) The molecular genetics of the Ehlers-Danlos syndrome. *Clin Exp Dermatol* 24:99–106
7. Narcisi P, Richards AJ, Ferguson SD, Pope FM (1994) A family with Ehlers-Danlos syndrome type III/articular hypermobility syndrome has a glycine 637 to serine substitution in type III collagen. *Hum Mol Genet* 3(9):1617–1620
8. Yen JL, Lin SP, Chen MR (2006) Clinical features of Ehlers-Danlos syndrome. *J Formos Med Assoc* 105(6):475–480
9. Dabbas N, Saker R, Blakeley C (2008) Multiple spontaneous dislocation in a patient with Ehlers-Danlos syndrome. *Emerg Med J* 25(3):175–176
10. Le Tallec H, Lassalle A, Khenioui H (2006) Two cases of rehabilitation in Ehlers-Danlos syndrome. *Annales de redaptation et de medicine physique* 49:81–84