

# Cranio-facial changes and mouth breathing

Patrick McKeown and John Mew consider the effect that a habit of mouth breathing can have on dental health

A good-looking face is determined by a strong, sturdy chin, developed jaws, high cheekbones, good lips, correct nose size and straight teeth. When a face develops correctly, it follows that the teeth will be straight. Straight teeth do not create a good-looking face, but a good-looking face will create straight teeth.

Each year, parents spend thousands of euros in an effort to straighten their children's teeth, unaware of other contributing factors. Approaching this issue with an open mind, we believe it is possible to ensure the normal development of a child's face and teeth by correcting habits and by applying non-invasive techniques, specifically the Buteyko method.

## Treating patients

Over the past few decades, an assistant has taken a photograph of the face of every child that Dr Mew has treated.

Figure 1 shows a 10-year-old boy who was a nose breather and who had a good-looking, broad face with everything in proportion. On the boy's 14th birthday, he was given a gerbil as a present. Soon after, his nose began to block, causing him to breathe through his mouth. Within three years, his face had changed its shape considerably (Figures 2a and 2b).

Because he breathed through his mouth between the ages of 14 and 17, his face grew downwards instead of in width. His face became narrow and long. His jaws are set back from their natural position. He now has a double chin and his jaws come back on his airways, resulting in smaller airways. This creates health problems such as sleep apnoea. His nose looks far bigger because his jaws do not come forward enough, and his cheeks are sunken as his face drags everything downwards. This face is typical of the thousands of children who breathe through their mouths.

Kelly (Figure 3) was seven years old and Samantha (Figure 4) was eight-and-a-half years old. Both sisters displayed habitual mouth breathing and were developing associated facial growth patterns. They attended Dr Mew, who taught them to breathe through their noses and to swallow correctly.

Kelly took on all that Dr Mew told her, but her older sister Samantha was more complacent. She did not keep her mouth closed while breathing.

Both girls returned a few years later. Again, Dr Mew's assistant took follow-up photographs. Kelly is shown in Figure 5 and Samantha in Figure 6. Observe the development of their faces. In your view, who has the more attractively defined face? Look at the tension on Samantha's mouth as she closes it to pose for the photograph.

## What is the Dr Buteyko method?

The Buteyko method was developed in the 1950s by Russian doctor Konstantin Buteyko. His method has been practised by hundreds of thousands of children and adults for a variety of conditions including mouth breathing, hay fever, blocked nose, snoring, sleep apnoea, asthma, blood pressure, anxiety, stress, panic attacks and depression.

As a young doctor, Buteyko spent many months sitting at sick patients' bedsides observing their states of health. He noticed that each person's breathing got heavier as his or her health deteriorated. As their illnesses advanced, he saw that his patients' breathing movements from their chests and tummies increased, that their breathing became more audible, that their breaths became faster, and that they sighed more and breathed through their mouths. In time, he was able to predict the onset of death just by observing their breathing.

This raised a fundamental question for Buteyko: was it his patients' sickness that contributed to their heavy breathing or was it their heavy breathing that contributed to their sickness?

At the time, Buteyko suffered from severe hypertension that was going from bad to worse. He began experimenting by breathing less and quietening his breathing. Within a short while, the pains that he had experienced for months went away.

Over the following decades, Buteyko extensively researched this subject and had a dedicated laboratory to further his findings. His method was brought to the West in 1990 and is now taught in many countries.

Breathing, such a vital factor for life, must meet certain conditions. Therefore, it is plausible to accept that teaching children to breathe through the nose and swallow correctly will significantly improve their dental development and overall health.

## Mouth breathing causes crooked teeth

During the 1960s, dentist Egil P Harvold recognised that 'oral respiration associated with obstruction of the nasal airway is a common finding among patients seeking orthodontic treatment' (Harvold PG, 1981). To determine the relationship between mouth breathing and crooked teeth, he conducted a number of experiments by blocking the noses of young monkeys with silicone nose plugs. In 1981, in the *American Journal of Orthodontics*, he wrote: 'The experiments showed that the monkeys adapted to nasal obstruction in different ways. In general, the experimental animals maintained an open mouth. All experimental animals gradually acquired a facial appearance and



Figure 1: The patient aged 10

Figures 2a and 2b: The patient aged 17

dental occlusion different from those of the control animals.'

The mouth-breathing monkeys developed crooked teeth and other facial deformities, including 'a lowering of the chin, a steeper mandibular plane angle, and an increase in the gonial angle as compared with the eight control animals' (Harvold EP, 1982).

Harvold claimed to be able to reproduce the equivalent of most human dental irregularities: 'Any common type of dental irregularity can be produced experimentally in monkeys with normal dentition' (Mew JRC, 1986).

In support of Harvold's findings, Dr Mew states that 'it is hard to escape the conclusion that in monkeys, a change in the action and posture of the tongue can produce severe malocclusions' (Mew JRC, 1986).

## Every child has the potential to grow an attractive face

Toddlers and young children generally have well-defined, broad and good-looking faces. However, a different story emerges with many teenagers. A visit to a secondary school will uncover many long, narrow and flat faces with sunken cheek bones, receded chins, narrow jaws and prominent noses. So what happens in the interim? Why do children develop crooked teeth and narrow faces?

Many young children have beautifully straight teeth at the age of five or six, but the teeth and face can quickly change if they leave their mouth open (see Figure 7).

Consensus from thousands of oral facial myologists, hygienists, dentists, orthodontists and published papers worldwide is that for the face and, consequently, teeth to develop correctly, a number of factors must be employed by the growing child. Such factors include:

1. Mouth closed with lips gently together
2. Three-quarters of the tongue resting in the roof of the mouth, with the tip of the tongue placed before the front teeth
3. Breathing through the nose
4. Correct swallowing.

According to Meredith (1953), 60% of the growth of the face takes place during the first four years of life and 90% takes place by the age of 12. Development of the lower jaw continues until around age 18. Based on these observations, for correct craniofacial growth to take place, early intervention with nasal breathing and tongue posture is essential.

## How children develop crooked teeth

The normal growth direction of the jaws is forward. This occurs as a result of the forces exerted by the lips and tongue. It works on the same principle used in orthodontics – light forces move teeth.

The lips exert an estimated pressure against the teeth of between 100g and 300g (Sakuda M, Ishizua M, 1970). When swallowing, the pressure exerted against the anterior teeth by the tongue is estimated to be 500g (Profit WR, 1972).

We swallow an estimated 2,000 times per day and, each time we swallow, the tongue pushes upwards and flattens in the roof of the mouth, exerting a considerable force that shapes the jaws (Flutter J, 2007). The correct position of the tongue is resting in the roof of the mouth. As the child grows, the top jaw forms around the tongue. In other words, the shape of the top jaw is the shape of the tongue. As the tongue is U-shaped, it results in a broad facial structure with sufficient room to house all teeth. Nature dictates that the shape of the lower jaw will follow that of the top jaw (Flutter J, 2007).

When the mouth is open, the tongue cannot rest in the roof of the mouth, resulting in a poorer developed, narrow, V-shaped top jaw. A smaller top jaw leads to a narrow facial structure and overcrowding of the teeth.

According to Principato (1991), low tongue posture seen with mouth breathing impedes the lateral expansion and anterior development of the maxilla.

In the words of dentist Raymond Silkman: 'The most important orthodontic appliance that you all have and carry with you 24 hours a day is your tongue.'

'People who breathe through their nose normally have a >>>





Figure 3: Kelly at seven years old



Figure 4: Samantha at eight-and-a-half years old



Figure 5: Kelly several years later



Figure 6: Samantha several years later

tongue that postures up into the maxilla. When the tongue sits right up behind the front teeth, it is maintaining the shape of the maxilla every time you swallow. Every time the proper tongue swallow motion takes place, it spreads up against maxilla, activating it and contributing to that little cranial motion.

'Individuals who breathe through their mouths have a lower tongue posture and the maxilla does not receive the stimulation from the tongue that it should' (Silkman R, 2005).

### Craniofacial abnormalities

It is well documented that mouth-breathing children grow longer faces. A paper by Tourne (1990) recognised that 'the switch from a nasal to an oronasal (mouth and nose combined) breathing pattern induces functional adaptations that include an increase in total anterior face height and vertical development of the lower anterior face.'

In another paper, Schreiner (1996) comments that: 'Long-standing nasal obstruction appears to affect craniofacial morphology during periods of rapid facial growth in genetically susceptible children with narrow facial pattern.'

Deb and Bandyopadhyay (2007) wrote: 'A mouth breather lowers the tongue position to facilitate the flow of air in to the expanding lungs. The resultant effect is maldevelopment of the jaw in particular and deformity of the face in general. Setting of the teeth on the jaw is also affected. All these make the face look negative. So, to prevent orthodontic problems in children, it is necessary to detect the nasopharyngeal obstruction and treat the same accordingly.'

In a study of 47 children between the ages of six to 15 years to determine the correlation between breathing mode and craniofacial morphology, 'findings demonstrated a significant predominance of mouth breathing compared to nasal breathing in the vertical growth patterns studied' (Baumam I, Plindert PK, 1996). The paper concluded that 'results show a correlation between obstructed nasal breathing, large adenoids and vertical growth pattern.'

Another study involving 73 children between the ages of three and six years concluded that 'mouth breathing can influence craniofacial and occlusal development early in childhood' (Mattar SE et al, 2004).

Lopatiene and Babarskas (2002) studied 49 children with confirmed nasal obstruction. The researchers noted that 'the main characteristics of the respiratory obstruction syndrome (blocked nose) are presence of hypertrophied tonsils or adenoids, mouth breathing, open bite, cross bite, excessive anterior face height,

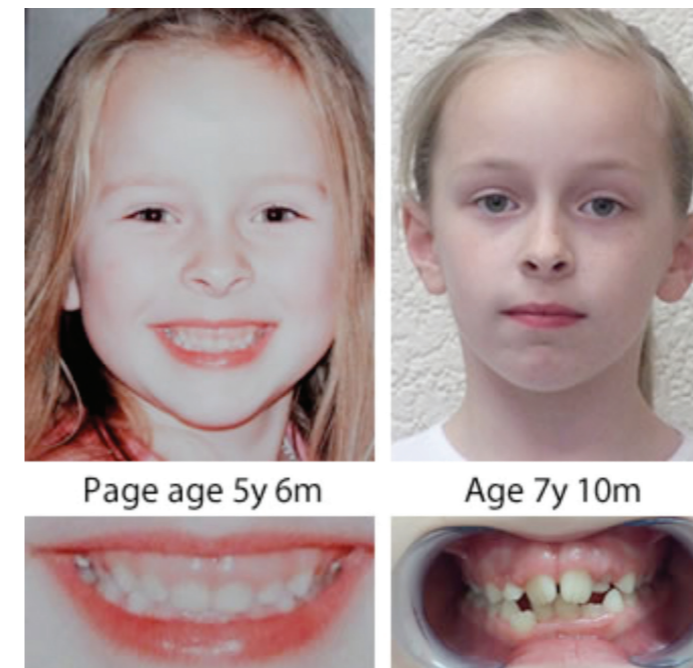


Figure 7: Many young children have beautifully straight teeth at the age of five or six but the teeth and face can quickly change if they leave their mouth open

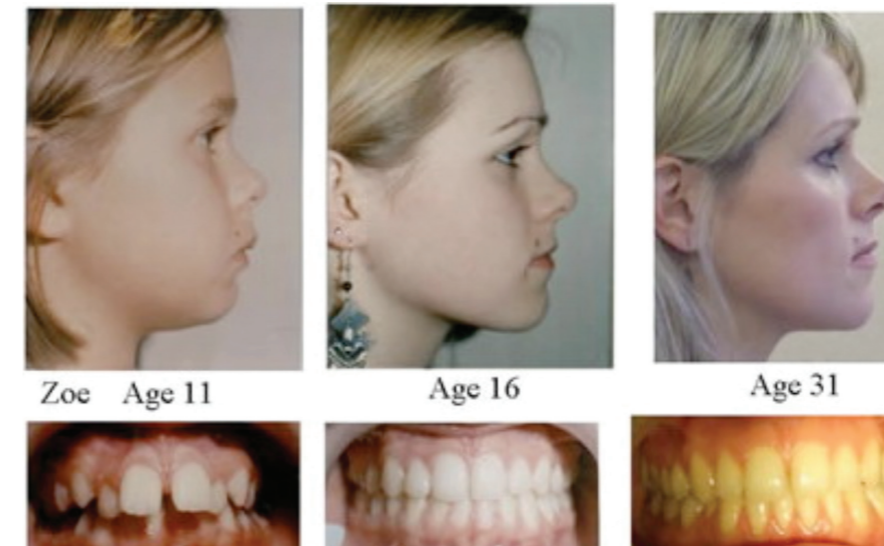


Figure 8: This patient illustrates forward growth of the face when nasal breathing, tongue posture and correct swallowing is habitual

incompetent lip posture, excessive appearance of maxillary anterior teeth, narrow external nares and V-shaped maxillary arch.'

When the tongue is not resting in the roof of the mouth, the jaws are impeded from growing forward and are instead set back from their ideal position. This contracts the airways, contributing to breathing difficulties and sleep apnoea.

In addition, the nose will seem larger, similar to that of a roman nose. The 'nose is more pronounced in an ideal occlusion but in the various malocclusions where the maxilla is underdeveloped it appears larger, although in fact it is smaller' (Mew JRC, 1986).

Given the extent of information available, it is surprising that few dentists seem to be aware of the craniofacial effects of mouth breathing. In the journal *General Dentist*, Jefferson (2010) noted that 'the vast majority of healthcare professionals >>

are unaware of the negative impact of upper airway obstruction (mouth breathing) on normal facial growth and physiologic health.

'Children whose mouth breathing is untreated may develop long, narrow faces, narrow mouths, high palatal vaults, dental malocclusion (crooked teeth), gummy smiles and many other unattractive facial features.

'These children do not sleep well at night due to obstructed airways; this lack of sleep can adversely affect their growth and academic performance. Many of these children are misdiagnosed with attention deficit disorder (ADD) and hyperactivity.'

The paper further states that 'if mouth breathing is treated early, its negative effect on facial and dental development and the medical and social problems associated with it can be reduced or averted.'

## Reversible at an early age

Learning correct breathing and swallowing before the age of eight often corrects facial development without the need for any orthodontic treatment. As the lower jaws are still developing until the age of 18, teenagers can also derive considerable benefit.

Furthermore, the success of any orthodontic treatment depends on the application of correct breathing and swallowing. Estimates in the field are that up to 90% of orthodontic work relapses unless poor oral habits such as mouth breathing are addressed (Flutter J, 2007).

During the 1970s and 1980s, Linder-Aronsen consistently noted the relationship between nasal obstruction and craniofacial changes, including longer faces, open bite and cross bite. More importantly, significant craniofacial changes toward normal were observed to take place after patients returned to nasal breathing.

In another study of 26 children, Kerr et al (1989) showed how development of the lower jaws began to normalise after they switched from mouth to nasal breathing.

## Conclusion

We believe every child has the ability to develop an attractive face and reduce, if not eliminate, associated dental health problems by being taught to breathe in the right way.

Encouraging children to breathe through the nose, thus allowing the tongue to rest in the ideal position, will do away with the negative impact of upper airway obstruction on normal facial growth and physiologic health. ■

## References

Baumam I, Plindert PK (1996) Effect of breathing mode and nose ventilation on growth of the facial bones. *HNO* **44(5)**: 229-34

Deb U, Bandyopadhyay SN (2007) Care of nasal airway to prevent orthodontic problems in children. *J Indian Med Assoc* **105(11)**: 640, 642

Flutter J (2007) *Proceedings of the Buteyko Institute of Breathing and Health conference*. Melbourne, Australia

Harvold EP, Tomer BS, Vargervik K, Chierici G (1981) Primate experiments on oral respiration. *Am J Orthod* **79(4)**: 359-372

Harvold EP, Tomer BS, Vargervik K, Chierici G (1982) Primate experiments on mandibular growth direction. *Am J Orthod* **82(2)**: 114-9

Jefferson Y (2010) Mouth breathing: adverse effects on facial growth, health, academics and behaviour. *General Dentist* **58(1)**: 18-25

Kerr WJ et al (1989) Mandibular form and position related to changed mode of breathing – a five-year longitudinal study. *Angle Orthod* **59(2)**: 91-96

Linder-Aronson S (1970) Adenoids: their effect of the mode of breathing and nasal airflow, and their relationship to characteristics of the facial skeleton and the dentition. *Acta Otolaryngology Suppl* **265**: 1

Linder-Aronson S (1979) Adenoid obstruction of the nasopharynx. In: *Nasorespiratory function and craniofacial growth. Monograph 9. Craniofacial growth series*. Ann Arbor: University of Michigan: 121-47

Linder-Aronson S (1979) Cephalometric radiographs as a means of evaluating the capacity of the nasal and nasopharyngeal airway. *Am J Orthod Dentofacial Orthop* **76**: 479-90

Linder-Aronson S (1986) Mandibular growth following adenoidectomy. *Am J Orthod* **89**: 273-84

Lopatiene K, Babarskas A (2002) Malocclusion and upper airway obstruction. *Medicina* **38(3)**: 277-283

Mattar SE et al (2004) Skeletal and occlusal characteristics in mouth-breathing pre-school children. *J Clin Pediatr Dent* **28(4)**: 315-318

Meredith HV (1953) Growth in head width during the first twelve years of life. *Pediatrics* **12**: 411-429

Mew JRC (1986) *Biobloc therapy*. Flo-Print, Tunbridge Wells

Principato JJ (1991) Upper airway obstruction and craniofacial morphology. *Otolaryngol Head Neck Surg* **104(6)**: 881-90

Profit WR (1972) Lingual pressure pattern in the transition from tongue thrust to adult swallowing. *Arch Oral Biol* **17**: 555-63

Sakuda M, Ishizua M (1970) Study of the lip bumper. *J Dent Res* **49**: 667

Schreiner C (1996) *Nasal airway obstruction in children and secondary dental deformities*. UTMB, Dept. of Otolaryngology, Grand Rounds Presentation

Silkman R (2005) Is it mental or is it dental? Cranial and dental impacts on total health. *Wise Traditions*. Winter 2005/Spring 2006: 15-24

Tourne LP (1990) The long face syndrome and impairment of the nasopharyngeal airway. *Angle Orthod* **60(3)**: 167-76

**Patrick McKeown is a graduate of Trinity College Dublin and the Buteyko Breathing Clinic of Moscow. He is one of a few Western experts who are directly authorised and accredited by the late Professor Buteyko to teach this method.**

**Dr John Mew is an orthodontist living and working in London. He graduated in dentistry from University College London, and then trained in orthognathic surgery at the Royal Victoria Hospital, where he developed an interest in the science of facial growth. In 1965, he returned to University College to specialise in orthodontics. Since then, he has been developing non-surgical methods of correcting unattractive vertical growth in children's faces.**

**Reproduced with permission from the book *Buteyko meets Dr Mew* by Patrick McKeown**