

# An evaluation of dehydrated human amniotic membrane allografts in patients with DFUs

- **Objective:** To evaluate healing of chronic diabetic foot ulcers (DFUs) with use of dehydrated human amniotic membrane (dHAM) in patients failing under standard of care treatment.
- **Method:** The study population was identified from patients with chronic DFUs enrolled in a randomised trial comparing standard care with standard care with the addition of dHAM. The present study included patients that failed to heal (defined as <50% decrease in wound size after 6 weeks, or not completely healed by 12 weeks of treatment) with standard care. One week after withdrawal from the randomised trial, these patients were offered treatment with standard care and bi-weekly application of dHAM. Subsequent evaluation of clinical records was made with IRB approval and patient consent. Each patient was used as their own control to compare wound size reduction between treatment periods, and healing rates within the 12-week dHAM treatment period.
- **Results:** Eleven patients were included in the study. Mean wound chronicity was  $21.1 \pm 12.4$  weeks (range 11–54 weeks) and mean wound size was  $4.7 \pm 5.0\text{cm}^2$ , at baseline. Complete healing was achieved in 55% by 4 weeks, 64% by 6 weeks and 91% by 12 weeks with bi-weekly dHAM application. Mean weeks to complete healing was  $4.2 \pm 3.1$  weeks for the 10 patients healed. After 4 weeks of standard care, wounds had decreased in size an average of  $26.8 \pm 45.3\%$  versus  $87.6 \pm 16.0\%$  after 4 weeks of dHAM treatment (two applications;  $p < 0.001$ ).
- **Conclusion:** This study provides evidence that the incorporation of dHAM into standard of care for patients with chronic DFUs can be beneficial. The results suggest that dHAM is a viable option for the treatment of recalcitrant DFUs
- **Declaration of interest:** This study was sponsored and funded by MiMedx. The Professional Education and Research Institute received research funds to conduct the trial. The author has no conflicts of interest to declare.

amniotic membrane allograft; diabetic ulcer; wound care

In patients with diabetes, peripheral vascular disease and neuropathy often lead to development of foot ulcers, which are notoriously difficult to treat and slow to heal. Up to one-quarter of diabetic patients will develop a foot ulcer in their lifetime.<sup>1</sup> Diabetic foot ulcers (DFUs) often lead to severe morbidity, impaired quality of life, high treatment costs, and are the most frequent cause for lower-extremity amputation.<sup>2</sup> It is well established that unhealed DFUs are at increased risk of infection and other, more serious complications. Indeed, Lavery et al. reported that DFU duration of >30 days was independently associated with a 4.7-fold increase in incidence of infection, and that an infected DFU increased risk of hospitalisation by nearly 56 times and risk for amputation by nearly 155 times.<sup>3</sup>

As rates of diabetes escalate worldwide, DFUs are an increasingly significant public-health problem. The goal of wound management is to promote rapid and complete healing to reduce the risk of infection, which can be limb- or even life-threatening. Therapies that promote rapid and complete healing,

thereby reducing the risk for infection and amputation, can substantially improve quality of life, while decreasing financial burdens to the individual and society overall.<sup>4</sup>

While there are reports of natural human amniotic membrane being used as a wound covering,<sup>5–8</sup> historically, issues with obtaining, preparing and storing the material, and concerns regarding the potential for infectious-disease transmission, has impacted its widespread use.<sup>5</sup> With recent development of a system for stabilisation and preservation of amniotic membrane, a human dehydrated amniotic membrane (dHAM) allograft is now available in the United States (EpiFix; MiMedx Group, Inc.).

The purpose of the present study was to evaluate healing rates of DFUs when dHAM was used in addition to standard of care received in a structured wound-care protocol.

## Method

A retrospective, crossover study was conducted on patients with type I/II diabetes and a DFU of at least

**C.M. Zelen, DPM,**  
Medical Director,  
Professional Education  
and Research Institute,  
Inc., Roanoke, Virginia,  
USA.  
Email: cmzelen@  
periedu.com

The author would like to thank Dr Donald Fetterolf, Guilhem Denoziere and Niki Istwan from MiMedx for their technical help and administrative assistance, and Dr Thomas Serena who reviewed the manuscript and provided valuable insight.

## References

- 1 Cavanagh, P.R., Lipsky, B.A., Bradbury, A.W., Botek, G. Treatment of diabetic foot ulcers. *Lancet*. 2005; 366: 1725–1735.
- 2 Ramsey, S.D., Newton, K., Blough, D. et al. Incidence, outcomes and cost of foot ulcers in patients with diabetes. *Diabetes Care*. 1999; 22: 382–387.
- 3 Lavery, L.A., Armstrong, D.G., Wunderlich, R.P. et al. Risk factors for foot infections in individuals with diabetes. *Diabetes Care*. 2006; 29: 1288–1293.
- 4 Albert, S. Cost-effective management of recalcitrant diabetic foot ulcers. *Clin Podiatr Med Surg*. 2002; 19: 483–491.
- 5 John, T. Human amniotic membrane transplantation: past, present, and future. *Ophthalmol Clin North Am*. 2003; 16: 43–65.
- 6 Gruss, J.S., Jirsch, D.W. Human amniotic membrane: a versatile wound dressing. *Can Med Assoc J*. 1978; 118: 1237–1246.
- 7 Sawhney, C.P. Amniotic membrane as a biological dressing in the management of burns. *Burns*. 1989; 15: 339–342.
- 8 Mermet, I., Pottier, N., Saintthillier, J.M. et al. Use of amniotic membrane transplantation in the treatment of venous leg ulcers. *Wound Repair Regen*. 2007; 15: 459–464.
- 9 Zelen, C.M., Serena, T.E., Denoziere, G., Fetterolf, D.E. A prospective randomized comparative parallel study of amniotic membrane wound graft in the management of diabetic foot ulcers. *Int Wound J*. 2013; doi: 10.1111/iwj.12097. [Epub ahead of print].
- 10 Warriner, R.A., Snyder, R.J., Cardinal, M.H. Differentiating diabetic foot ulcers that are unlikely to heal by 12 weeks following achieving 50% percent area reduction at 4 weeks. *Int Wound J*. 2011; 8: 632–637.

6 weeks' duration that failed to heal with standard care. The study was conducted in a single centre in Southwest Virginia, under the direction of a senior clinician with expertise in DFU (CMZ).

## Study population

All patients had prior enrolment in a prospective, randomised trial comparing healing characteristics with standard treatment alone versus standard of care with the addition of dHAM, and had completed that study without healing of their DFU.<sup>9</sup> Failure to heal was defined as less than 50% decrease in wound size after 6 weeks of study participation, or not having completely healed by 12 weeks of standard treatment within the study setting, where full healing was defined as complete epithelialisation of the open area of the wound.

Standard of care included debridement, moist therapy, standardised use of topical antimicrobials (SilvaSorb gel; Medline, or Aquacel AG; ConvaTec), compression dressings and offloading of the effected extremity. Patients who failed to heal with standard of care alone, and who subsequently received dHAM in addition to continuation of standard care, were included in the study. Patients read and signed an international review board (IRB)-approved informed consent form prior to enrolment in the initial study and provided additional IRB-approved consent for the current retrospective review of subsequent data and outcomes.

## Study protocol

Following surgical debridement of all necrotic tissue, dHAM was applied to the wound. A non-adherent dressing (Adaptic; Systagenix) was used to cover the dHAM, followed by a moisture-retentive dressing (hydrogel) and a compression dressing. All wounds were offloaded using a removable cast walker (Active Offloading Walker; Darco of Huntington). Dressing changes took place weekly, during the office visit. If the ulcer had not completely epithelialised, an additional piece of dHAM was applied at weeks 2, 4, 6, 8, and 10.

All patients were seen by the investigator weekly for up to 12 weeks, or until complete healing, whichever occurred first. During each weekly visit, ulcer cleansing with a sterile normal saline solution (rinsing, swabbing or irrigating), ulcer measurement with a graded centimetre ruler (length, width and depth) and a dressing change were conducted. When applicable, measurements were done after debridement. The wound area was calculated by multiplying the width and length measurements.

Study outcomes included reduction in wound size and the proportion of ulcers completely healed during the study period. Each patient was used as their own control, to compare wound size reduction between treatment periods (standard care vs dHAM).

**Table 1. Patient characteristics**

No. of patients	11
Sex (male/female)	7/4 (64%/36%)
Age (years)	61.5 ± 10.5
• Median	59 (46–82)
Body mass index (kg/m <sup>2</sup> )	35.6 ± 6.9
• Median	34.7 (27.0, 51.6)
• Obese (≥ 30kg/m <sup>2</sup> )	8 (73%)
• Smoker (n)	2 (18%)
Ethnicity (n)	
• Caucasian	10 (91%)
• African-American	1 (9.1%)
Wound size (cm <sup>2</sup> )	4.7 ± 5.0
• Median	2.5 (0.7–13.5)
Wound duration (weeks)	21.1 ± 12.4
• Median	19 (11–54)

Results presented as mean ± standard deviation and median (range);

## Statistical analysis

Descriptive statistics were calculated for all variables. Paired t-test or Mann Whitney rank sum test were used to compare continuous variables between study intervals. The level of statistical significance was set at  $p < 0.05$ . All statistical analyses were conducted using Minitab (v16; Minitab, Inc.).

## Results

Eleven patients received standard of care and biweekly application of dHAM, starting 1 week after exiting the initial randomised trial due to failure to heal (Table 1). Overall, at time of first dHAM allograft placement, the DFUs had been present for a mean of  $21.1 \pm 12.4$  weeks (median 19 weeks, range 11–54 weeks). At time of initiation of dHAM treatment 10 patients had undergone 7 weeks and one patient 13 weeks of standard care in the prior randomised trial.<sup>9</sup> Mean wound size at enrolment in the initial randomised trial compared with at initiation of dHAM were  $3.6 \pm 3.0 \text{ cm}^2$  and  $4.7 \pm 5.0 \text{ cm}^2$ , respectively ( $p = 0.242$ ).

Wound size was measured at each weekly visit. Table 2 presents the percentage change in wound size over time from the baseline wound size at the initiation of the respective treatment (standard care then dHAM). During the initial study period, while patients were receiving standard care only, measurements of wound size did not show a consistent decrease week by week and, by week 6, the overall mean wound size had increased from baseline. During the dHAM treatment period, consistent reduction in wound size was noted week on week. By week 2 (one dHAM application), 82% of patients ( $n = 9$ ), and by week 4 (two dHAM applications), 100% of patients ( $n = 11$ ), had achieved >50% reduction in wound size.

Ten of the 11 patients (91%) receiving bi-weekly dHAM healed completely within the 12 week study period (Fig 1). Five patients (45%) healed with one dHAM application, one (9.1%) healed with two applications, one (9.1%) healed with three applications, two (18%) healed with four applications, and one (9.1%) healed after five applications. For the 10 patients (91%) who healed within the 12-week period, the average healing time was  $4.2349 \pm 3.1$  weeks (median 2.5 weeks, range 1–9 weeks). The one patient that did not heal with dHAM subsequently received a split thickness skin graft and healed without complication.

## Discussion

In the present study of 11 patients with chronic DFUs that failed to heal with standard care, 11 (100%) showed >50% reduction in wound size within 4 weeks of starting treatment with dHAM and 10 patients (91%) had complete healing of their wound within 9 weeks of dHAM initiation. These results suggest that the addition of dHAM to routine wound management can enhance wound healing in patients with DFUs.

It is important that clinicians remain knowledgeable of new techniques, technology and products that can assist in their efforts to provide optimal care and promote positive outcomes for these difficult wounds. A 50% reduction in wound size at 4 weeks is a critical cutoff point for evaluating DFU treatment success.<sup>10</sup> Use of advanced therapies should be considered if wound size has not reduced by 50% after 4 weeks of standard wound care. Bioengineered skin substitutes and wound-care technologies, such as the topical gel becaplermin (Regranex; Systagenix), and living skin equivalents Apligraf (Organogenesis) and Dermagraft (Advanced BioHealing), have been shown to accelerate the healing process, but are not a universal remedy; no perfect skin substitute exists for all patients in all situations.<sup>11</sup>

Human amniotic membrane has been used clinically in a variety of applications for over 100 years.<sup>5</sup> Amniotic membrane is the innermost layer of placenta and consists of a thin epithelial layer, a thick basement membrane and an avascular stroma.<sup>12</sup> These materials provide structural collagen and extracellular matrix, biologically active cells and a large number of important regenerative molecules.<sup>13,14</sup> Collagens type IV, V and VII provide an important substrate, which is not only important for the structural integrity of the membrane, but facilitates wound healing and cellular ingrowth. Amniotic membrane has been shown to be antimicrobial, can reduce pain, inflammation and scar tissue formation at the site of application, and contains essential growth factors and cytokines that may enhance the healing process.<sup>8,14–17</sup>

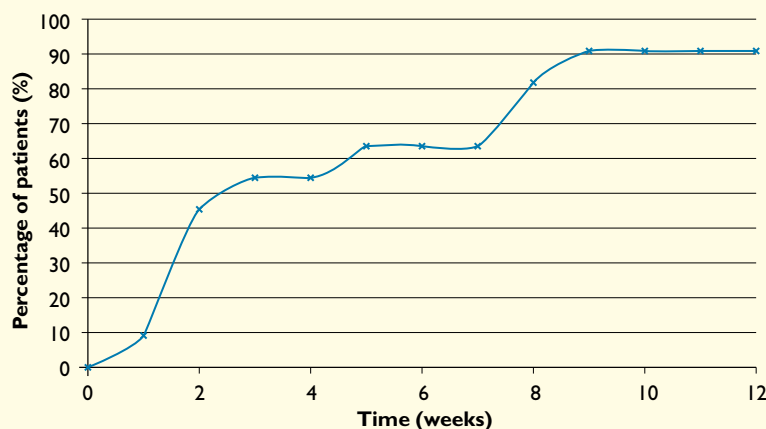
Amniotic membrane has been identified as a potent facilitator of wound healing in a variety of

**Table 2. Mean percentage reduction in wound size versus baseline during each treatment period**

Treatment week	Standard of care (n=11)	dHAM (n=11)	p-value
Week 1 (%)	21.4 ± 36.8	62.5 ± 29.9	0.013
Week 2 (%)	15.5 ± 52.3	76.2 ± 25.3	0.003
Week 3 (%)	13.3 ± 45.3	87.0 ± 15.9	<0.001
Week 4 (%)	26.8 ± 45.3	87.6 ± 16.0	<0.001
Week 5 (%)	6.7 ± 63.8	92.6 ± 12.6	<0.001
Week 6 (%)	–10.6 ± 65.8	93.9 ± 11.1	<0.001

Results presented as mean ± standard deviation

**Fig 1. Percentage of patients healed during the study period**



situations, including lower extremity vascular ulcers, conjunctival reconstruction, burns, gynaecologic surgery, orthopaedics, and a variety of other applications.<sup>5–8,18,19</sup> Recently, advanced tissue stabilisation and preservation processes have allowed for widespread use of human amniotic membrane in the form of dHAM products;<sup>20</sup> dHAM is minimally processed human amniotic membrane received from screened and tested donors to ensure safety. It is an operationally-efficient material, in that it can be transported and stored at room temperature for up to 5 years. This minimises the need for complex policies for receiving and storing certain graft materials that may require subzero refrigeration, or may have a short storage life that often leads to wasted product.

Handling characteristics of the dHAM material minimise application time and are clinically efficient. The material is provided in a number of different sizes, minimising waste when used on ulcers of various sizes and at various stages in the healing process.

11 Shores, J.T., Gabriel, A., Gupta, S. Skin substitutes and alternatives: a review. *Adv Skin Wound Care*. 2007; 20: 493–508.

12 Schmidt, W. *The Amniotic Fluid Compartment: The Fetal Habitat*. Springer, 1992.

13 Schultz, G.S., Davidson, J.M., Kirsner, R.S. et al. Dynamic reciprocity in the wound microenvironment. *Wound Repair Regen*. 2011; 19: 134–148.

14 Parolini, O., Solomon, A., Evangelista, M. et al. Human term placenta as a therapeutic agent: from the first clinical applications to future perspectives. In: Berven, E. (ed). *Human Placenta: Structure and Development*. Nova Science Publishers, 2010.

The results of the current study are similar to those presented in the group treated with dHAM in the previous randomised trial.<sup>9</sup> In the current study, 91% of patients (n=10) healed within the 12-week study period, while in the previous randomised trial 92% of patients (n=12) treated with dHAM healed in the 12-week study period.<sup>9</sup> Other investigators have also reported positive results with using the dHAM product in patients with lower extremity wounds.<sup>21,22</sup>

### Limitations

The current study has a number of limitations inherent to those of a retrospective study design and small sample size. Larger studies are needed to confirm our findings. In the current study dHAM was applied

every 2 weeks, so we do not know if weekly application would further enhance the healing process. Studies are currently underway to address this question. As the comparative group was standard of care, we cannot comment on the effectiveness of the dHAM product versus, or as an addition to, other advanced therapies. Additional comparative effectiveness studies are required to address those questions.

### Conclusion

The present study provides additional evidence that the incorporation of dHAM into standard of care for patients with chronic DFUs can be beneficial. The results suggest that dHAM is a viable option for the treatment of recalcitrant DFUs. ■

**15** Hao, Y., Ma, D.H., Hwang, D.G. et al. Identification of antiangiogenic and antiinflammatory proteins in human amniotic membrane. *Cornea*. 2000; 19: 348–352.

**16** King, A.E., Paltoo, A., Kelly, R.V. et al. Expression of natural antimicrobials by human placenta and fetal membranes. *Placenta*. 2007; 28: 161–169.

**17** Tseng, S.C., Li, D.Q., Ma, X. Suppression of transforming growth factor-beta isoforms, TGF-beta receptor type II, and myofibroblast differentiation in cultured human corneal and limbal fibroblasts by amniotic membrane matrix. *J Cell Physiol*. 1999; 179: 325–335.

**18** Bennett, J.P., Matthews, R., Faulk, W.P. Treatment of chronic ulceration of the legs with human amnion. *Lancet*. 1980; 1: 1153–1156.

**19** Adly, O.A., Moghazy, A.M., Abbas, A.H. et al. Assessment of amniotic and polyurethane membrane dressings in the treatment of burns. *Burns*. 2010; 36: 703–710.

**20** Fetterolf, D.E., Snyder, R.J. Scientific and clinical support for the use of dehydrated amniotic membrane in wound management. *Wounds*. 2012; 24: 10, 299–307.

**21** Forbes, J., Fetterolf, D. Dehydrated amniotic membrane allografts for the treatment of chronic wounds: a case series. *J Wound Care*. 2012; 21: 290–296.

**22** Sheikh, E., Fetterolf, D.E. Use of dehydrated human amniotic membrane (dHAM) allografts to promote healing in patients with refractory non-healing wounds. *Int Wound J*. 2013; doi: 10.1111/iwj.12035.