

# Multiple Aneurysms in a Patient with Ehlers-Danlos Syndrome: Angiography Without Sequelae

FAYYAZ H. MIRZA,<sup>1</sup> PHILLIP L. SMITH, AND WILLIAM N. LIM

The Ehlers-Danlos syndrome is an uncommon hereditary disorder of connective tissue. The main characteristics are joint hypermobility and skin hyperextensibility. Easy bruising, poor healing with wide gaping scars, and cardiovascular, gastrointestinal, orthopedic, and ocular manifestations may also occur. The syndrome is considered heterogeneous [1] and different variants of the syndrome have been described [1, 2].

Multiple arterial aneurysms have been noted in patients with Ehlers-Danlos syndrome [3-7], but due to increased vessel friability and vascular complications secondary to angiography, invasive radiographic studies have generally been discouraged [2, 7-10]. There are several reports of serious complications and even death after attempted arteriography [8, 10, 11]. We describe a patient who was felt to represent the "mitis" variety of Ehlers-Danlos syndrome with multiple arterial aneurysms and emphasize that multiple arteriographic procedures can be safely performed.

## Case Report

B. T. (#37-83-28), a 17-year-old white woman, was admitted for evaluation of a pulsatile abdominal mass. At age 8 she had undergone resection of a left brachial artery aneurysm and was also found to have another smaller aneurysm in the right antecubital fossa. This diagnosis was made clinically and no arteriography was done. She was referred to the University Medical Center at age 17 because of an enlarging pulsatile abdominal mass for 1 year. She had a history of easy bruising but no other stigmata of the Ehlers-Danlos syndrome. Her paternal grandmother was known to have a tendency to bruise easily.

On physical examination, the patient's skin was somewhat thin with moderate gaping of her previous surgical scar. Moderate hypermobility of the hand and wrist joints was present. A 2 × 2.5 cm pulsatile mass was present on the medial aspect of the right antecubital fossa.

Retrograde percutaneous aortography using a 7.2 French straight catheter (Cook, Inc.) with side holes revealed two saccular aneurysms 7 and 3 cm in diameter just above the abdominal aortic bifurcation (fig. 1A). No complications were encountered. The abdominal aortic aneurysms were resected and a Dacron bifurcation graft was placed without any complications. The wound healed with slight widening of the scar.

The histology of the aortic wall revealed a decrease in number of elastic fibers and a moderate degree of disarray in the alignment of elastic fibers when compared with a normal aorta. This part of history and clinical presentation has been previously published [12].

The patient was admitted to this hospital 3 years later when she developed numbness, pain, and "heaviness" of the left leg.

On physical examination, the left femoral and popliteal artery had 1+ pulses and no palpable distal pulses. Aortofemoral arteriography was performed via a left axillary approach with a 4.1 French Smith Hooktail catheter (Cook, Inc.) without any complications. It disclosed complete occlusion of the left aortoiliac bifurcation graft. Exploration of the aortoiliac bifurcation graft with resection and reextension of the left limb of the graft was performed without complications.

The patient's third admission was for throbbing bitemporal headaches over 9 months. Bilateral carotid, left vertebral, and left subclavian arteriography was performed via a right axillary approach, using a 6 French Simmons 2 catheter (Cook, Inc.) with heparinization. This revealed an aneurysm of the right internal carotid artery at the level of the siphon (fig. 1B). Two aneurysms of the left brachial artery were also seen (fig. 1C).

A large hematoma that developed in the right axilla later resolved without complications. The patient also had spontaneous recovery from blurring and loss of vision.

The fourth admission was for evaluation of hypertensive blood pressure of recent onset. Excretory urography suggested the possibility of a right renal artery aneurysm as evidenced by annular calcification. Bolus aortography and right renal arteriography were done carefully, using 5 French Shephards Crook B and Hawkins Hooktail catheters. A right renal artery aneurysm was revealed (fig. 1D). No corrective surgery was performed and the patient was released on antihypertensive therapy.

## Discussion

Barabas [1] and Beighton et al. [2] have classified Ehlers-Danlos syndrome into five identifiable clinical groups. These have been called gravis, mitis, benign hypermobile, ecchymotic, and X-linked type.

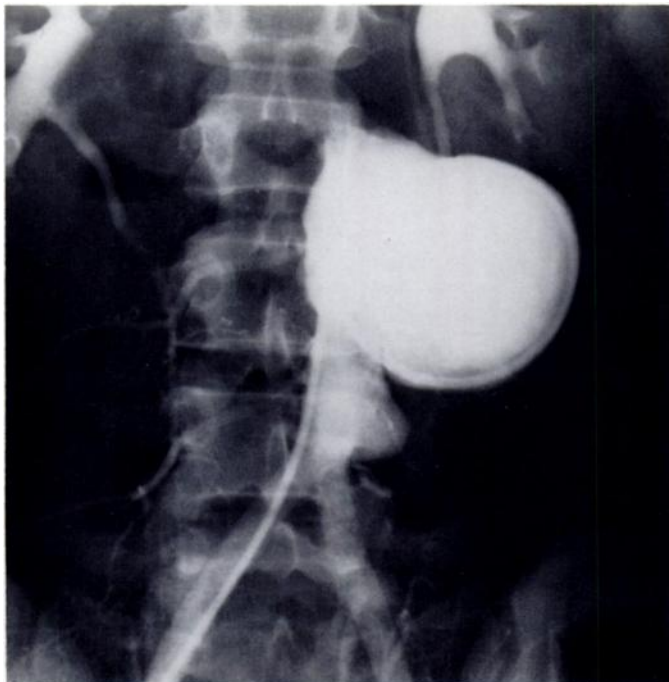The gravis type is easily recognized. Marked skin hyperextensibility and generalized joint hypermobility is present. Wide gaping scars are frequent. Bruising tendency is of moderate degree. Varicose veins are very common and subcutaneous spheroids occur in the majority of these patients.

In the mitis variety of Ehlers-Danlos syndrome, the findings are all of minor degree and patients may remain undiagnosed. Joint hypermobility is limited in degree and may be confined to the hands and feet. The skin is less hyperextensible and does not split as readily as in the former variety, so that the resultant scarring is less marked. Bruising tendency is of mild degree. Musculo-skeletal deformity if present is usually slight. Tissue friability is not a problem.

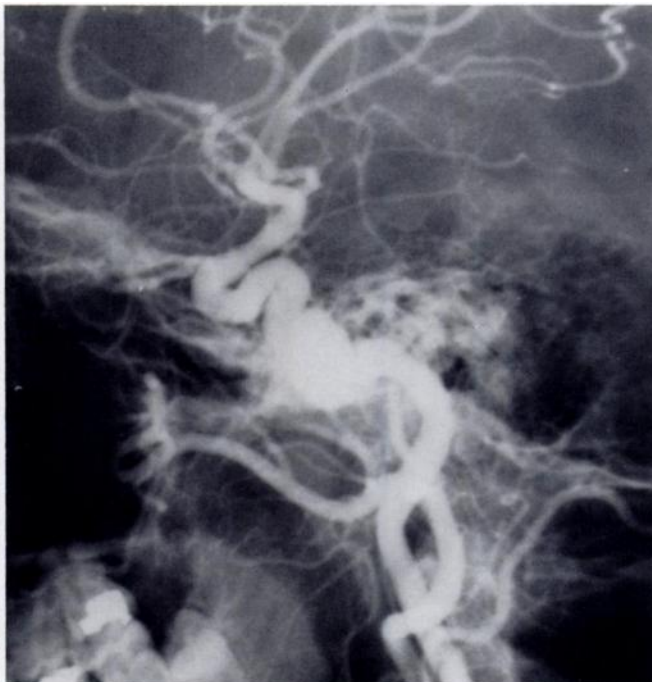In the benign hypermobile type, there is severe joint hypermobility, while skin hyperextensibility may be marked or minimal. Bruising tendency is mild. Skin splitting is limited and there is minimal scarring.

Received September 22, 1978; accepted after revision January 30, 1979

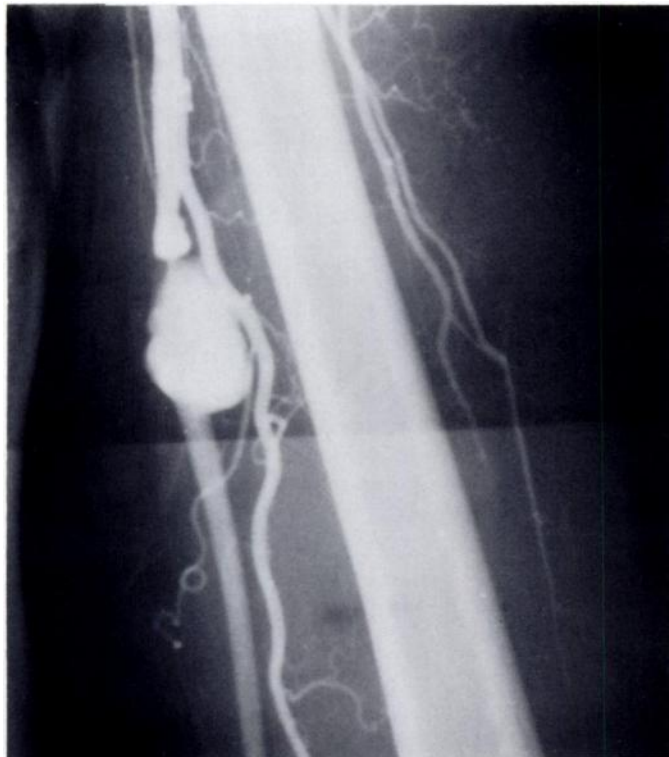<sup>1</sup> All authors: Department of Radiology, University of Arkansas for Medical Sciences, 4301 West Markham Street, Little Rock, Arkansas 72201. Address reprint requests to F. H. Mirza.



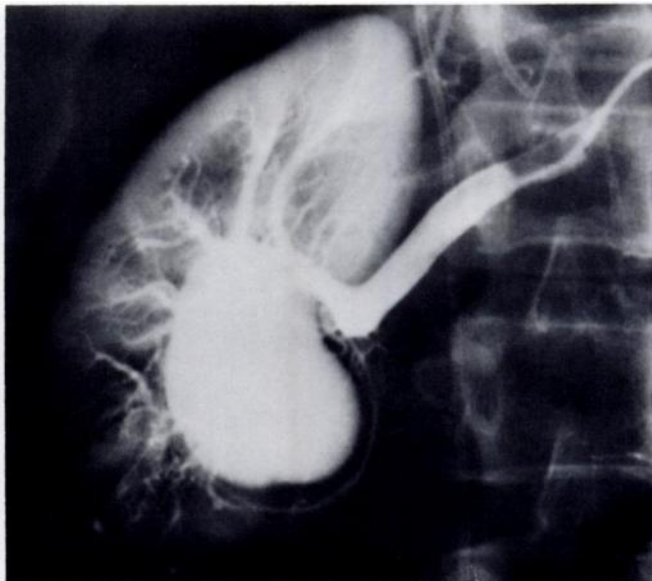
A



B



C



D

Fig. 1.—A, Abdominal aortogram. Two separate saccular aneurysms. B, Right carotid arteriogram, lateral view. Fusiform aneurysm of right internal carotid artery. C, Left subclavian arteriogram. Two saccular aneurysms of left brachial artery. D, Right renal arteriogram, arterial phase. Very large saccular aneurysm.

Spheroids and pseudotumors are uncommon and varicose veins are not present.

The ecchymotic type of Ehlers-Danlos syndrome is uncommon but is readily recognized and is of great clinical importance. The skin is thin and pale with prominent venous network. Bruising tendency is gross. Minor trauma leads to extensive ecchymosis and the bony

prominences become covered with thin, darkly pigmented scars which are unlike those in other types of Ehlers-Danlos syndrome. Many reports describing death in Ehlers-Danlos syndrome from arterial rupture, aortic dissection, or intestinal perforation probably pertain to patients with this variety of the syndrome.

Inheritance in the Ehlers-Danlos syndromes is usually

mediated by an autosomal dominant gene; however, a new entity in which transmission is X-linked has been described [2]. In this variety the skin hyperextensibility is very prominent while joint hypermobility is of limited degree. Skin splitting, scarring, and bruising are of moderate degree. Tissue friability may be noted at operation.

The point to which we particularly wish to direct attention in this paper is the presence of multiple arterial aneurysms and performance of multiple arterial catheterizations without any major complications in a patient with the mitis variety of Ehlers-Danlos syndrome. Fatal vascular complications in patients with documented Ehlers-Danlos syndrome have been reported. Beighton and Thomas [7] drew attention to the dangers of angiography in the Ehlers-Danlos syndrome. Schoolman and Kepes [8] described a patient who died after a tear in the ascending aorta which occurred during catheterization. The technical details of the angiographic procedure are not mentioned. Other complications have also been described. Rybka and O'Hara [10] described attempted retrograde arteriography in a patient with Ehler-Danlos syndrome, where a no. 15 needle was placed in the right femoral artery. A huge hematoma developed rapidly and the skin of the groin split into a 6-cm-wide wound. Although angiography has been successfully carried out [3], generally it is considered hazardous.

Our patient had four arteriographic studies without any major complications. A hematoma that developed during her third arterial study did not require any surgical intervention. The type of Ehlers-Danlos syndrome, use of

small catheters, careful manipulation, and heparinization definitely play a role in successful arterial catheterization.

#### REFERENCES

1. Barabas AP: Heterogeneity of the Ehlers-Danlos syndrome: description of three clinical types and a hypothesis as to explain the basic defect(s). *Br Med J* 2:612-613, 1967
2. Beighton P, Price A, Lord J, Dickson E: Variants of the Ehlers-Danlos syndrome. *Ann Rheum Dis* 28:228-242, 1969
3. Rubenstein MD, Cohen NH: Ehlers-Danlos syndrome associated with multiple intracranial aneurysms. *Neurology* 14:125-132, 1964
4. Imahorie S, Bannerman RM, Graf LJ, Brennan JC: E.D.S. with multiple arterial lesions. *Am J Med* 47:967-977, 1969
5. Edwards A, Taylor GW: E.D.S. with vertebral artery aneurysm. *Proc R Soc Med* 62:734-735, 1969
6. Huntington RW, Hirst AE: Dissecting aneurysm of the aorta in a 16 year old girl. *Am J Clin Pathol* 48:44-48, 1967
7. Beighton P, Thomas ML: The radiology of the Ehlers-Danlos syndrome. *Clin Radiol* 20:354-361, 1969
8. Schoolman A, Kepes JJ: Carotid cavernous fistula in E.D.S. *J Neurosurg* 26:82-86, 1967
9. Dales HC, O'Neile JJ: Management of arterial complications in a case of the arterial type of Ehlers-Danlos syndrome. *Br J Surg* 57:476-477, 1970
10. Rybka FJ, O'Hara ET: Surgical significance of E.D.S. *Am J Surg* 113:431-434, 1967
11. Mories A: Ehlers-Danlos syndrome with a report of a fatal case. *Scott Med J* 5:269-272, 1960
12. Burnett HF, Bledsoe JH, Char F, Williams GD: Abdominal aortic aneurysmectomy in a 17-year-old patient with Ehlers-Danlos syndrome: case report and review of literature. *Surgery* 74:617-620, 1973