

Multiple Aortocaval Fistulas Associated With a Ruptured Abdominal Aneurysm in a Patient With Ehlers-Danlos Syndrome

Naohito Taniyasu, MD; Hiroyuki Tokunaga, MD*

Aortocaval fistula (ACF) is a rare complication of spontaneous abdominal aortic aneurysm (AAA) rupture, with an incidence of 2–4%. A unique case of ruptured AAA complicated by multiple aortovenous fistulas involving the inferior vena cava and left internal iliac vein is presented, and is the first published report of a patient with Ehlers-Danlos syndrome undergoing surgical treatment for an ACF. (*Jpn Circ J* 1999; 63: 564–566)

Key Words: Abdominal aortic aneurysm; Aortocaval fistula; Ehlers-Danlos syndrome

Spontaneous aortocaval fistula (ACF) is a rare and dangerous complication of abdominal aortic aneurysm (AAA). Although the incidence of venous fistula formation following AAA rupture is between 2 and 4%, the mortality rate of this condition is approximately 30%¹.

The first reported case with a ruptured aortic aneurysm that produced an aortocaval fistula was that by James Syme in 1831². Although surgical repair of a spontaneous ACF was first reported by Lehman in 1935³, this attempt was unsuccessful and the patient died after 15 h. Cooley reported the first successful repair in 1955⁴. We describe a patient with Ehlers-Danlos syndrome who was surgically treated for an AAA complicated by multiple ACF involving the inferior vena cava (IVC) and the left internal iliac vein.

Case Report

The patient, a 47-year-old man with no significant medical history, was admitted to hospital after being transferred from another institution under a diagnosis of AAA. The patient was admitted with complaints of abdominal swelling and lower extremity edema of 2 months duration and sudden lower abdominal pain with exertional dyspnea.

Blood pressure was 120/70 mmHg, heart rate 104 beats/min. There was a grade III/VI systolic murmur along the left sternal border. Abdominal examination revealed a pulsating mass and continuous bruit on the right side of the umbilicus, and severe bilateral leg edema was present. Hemoglobin was 13.8 mg/dl and the hematocrit was 41.4%. Chest radiographs (Fig 1) showed cardiomegaly (cardiothoracic ratio 60%) and increased pulmonary vascular markings. Abdominal echography revealed an infrarenal type AAA, 7 cm at the largest diameter, without a mural thrombus, and dilatation of hepatic veins. Echocardiography

showed hyperdynamic motion of the left ventricular wall, severe mitral and tricuspid regurgitation, aortic insufficiency and pericardial effusion. Three-dimensional computed tomography (Fig 2) confirmed an AAA without mural thrombus, a partially dissected aortic wall and a dilated IVC 7 cm in diameter. Pulmonary artery flow-directed catheter studies demonstrated a cardiac output of 18.0 L/min and a cardiac index of 11.0 L min⁻¹ m⁻². The patient's pulmonary capillary wedge pressure was 39 mmHg, and central venous pressure was 14 mmHg.

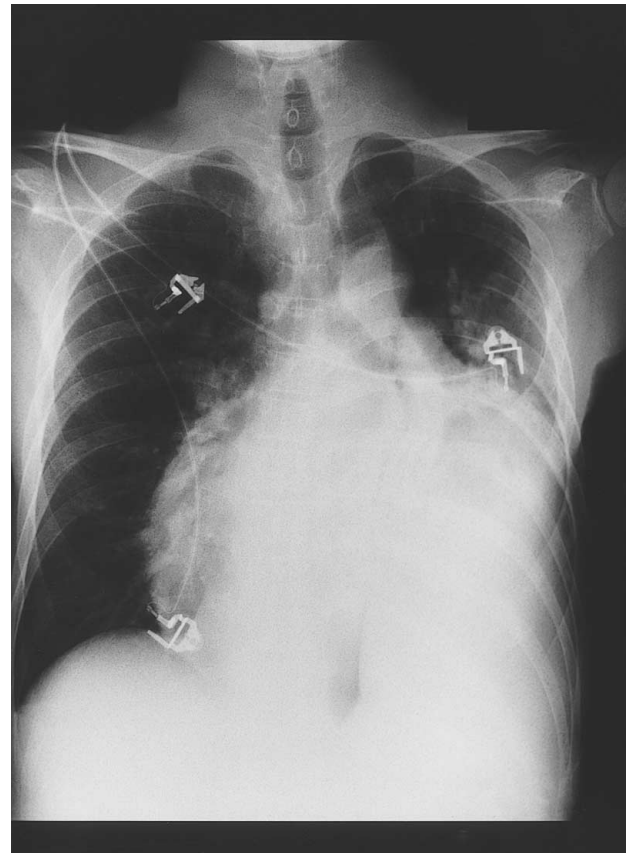


Fig 1. Anteroposterior chest radiograph, taken on admission, shows cardiomegaly.

(Received February 4, 1999; revised manuscript received March 18, 1999; accepted March 25, 1999)

Department of Cardiovascular Surgery, Iwaki Kyoritsu General Hospital and *Department of Cardiovascular Surgery, Kosei General Hospital, Tokyo, Japan

Mailing address: Naohito Taniyasu, MD, Department of Cardiovascular Surgery, Iwaki Kyoritsu General Hospital, 16 Kusehara, Uchigo-Mimaya-cho, Iwaki-city, Fukushima 973-8555, Japan

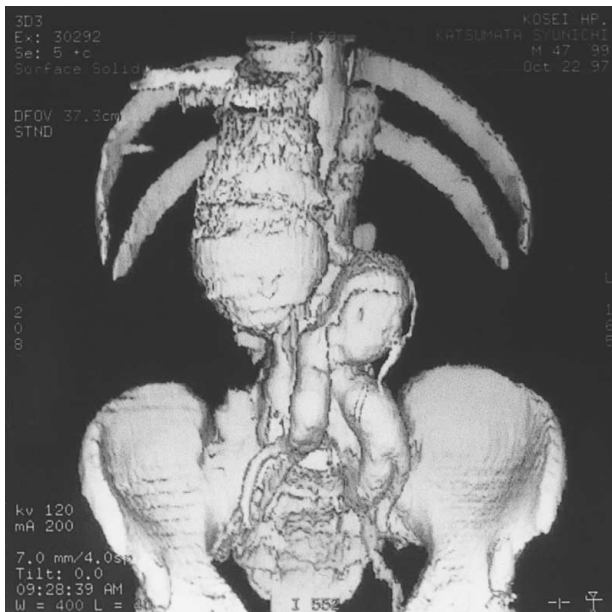


Fig 2. Preoperative helical three-dimensional computed tomography shows an infrarenal-type abdominal aortic aneurysm and a dilated inferior vena cava.

Aortography demonstrated contrast passage from the infrarenal abdominal aorta into the IVC.

The final diagnosis was ACF due to a ruptured dissecting AAA and an emergency operation was performed. A standard midline operative approach was made and a 7-cm infrarenal AAA was identified. After heparinization, the proximal and distal aorta were cross-clamped. The aneurysm was opened, followed by a rush of venous blood, which was aspirated for later washing and reinfusion. Three ACFs, 1 in the right posterolateral wall of the aneurysm and 2 in the left common iliac artery, were closed with 4-0 polypropylene interrupted mattress sutures. The aneurysm was closed primarily, and the aorta was excluded by ligation and stapling proximally and distally. Lumbar arteries were oversewn before the aneurysm was closed. A 16×8 mm woven Dacron bifurcated graft was sewn end-to-end to the proximal aorta and end-to-end to the common femoral arteries.

Enlargement of the intimal elastic fibers was not revealed by intraoperative biopsy of the aortic wall. Based on the clinical features of abnormal, velvety, poorly healing skin and the hyperextensibility of the joints, however, Ehlers-Danlos syndrome was diagnosed.

On the 7th postoperative day, echocardiography revealed that the severe valvular insufficiencies had nearly resolved, but mild pericardial effusion persisted. Therefore, pericardial drainage was performed, removing 800 ml of effusion.

Postoperative hemodynamic parameters were stable and the subsequent clinical course was uneventful with prompt reduction of cardiomegaly. At discharge on postoperative day 30, the patient had normal cardiac and renal function. He has remained well for 1 month, to date, since the operation.

Discussion

Aortocaval fistula is an uncommon, but well recognized, complication of an AAA. Approximately 1–2% of all AAA patients undergoing surgery are found to have an ACF, but

the incidence increases to 2–4% in the presence of rupture! Since 1991, several cases of ACF have been reported, most resulting from spontaneous rupture of an atherosclerotic aneurysm directly into the adjacent IVC^{5–20} ACF may also occur from penetrating abdominal trauma and as a result of iatrogenic trauma sustained at the time of lumbar disc surgery.²⁰ Infrequent causes include mycotic aneurysm, syphilis, and connective tissue disorders such as Ehlers-Danlos syndrome and Marfan's syndrome.⁷ ACF in association with connective tissue disorders such as Ehlers-Danlos syndrome is even more rare. It is amenable to surgical correction using a standard technique of fistula repair from within the aneurysm and prosthetic aortic graft replacement. Operative morbidity and mortality relate primarily to the degree of acute blood loss, myocardial infarction, renal failure and coagulopathy. Use of the autotransfusion device is essential for the maintenance of intravascular volume during the operative procedure. Following closure of the fistula, persistent excess circulating volume can lead to fluid imbalance and acute pulmonary edema, so careful postoperative monitoring is mandatory. Deep vein thrombosis secondary to surgical trauma to the IVC during repair is reported to be as high as 20% after ACF repair.¹² An extracaval clip has been suggested to reduce the likelihood of pulmonary embolism, and anticoagulation may be useful in the early postoperative period.

ACF can occur as a complication of AAA. The triad of low back pain, a palpable AAA, and a machinery murmur is diagnostic! The present case was admitted with abdominal swelling, lower abdominal pain, lower extremity edema, and dyspnea. He had a palpable abdominal mass with a loud machinery murmur. High-output heart failure with elevated central venous pressure and pulmonary edema or lower limb edema.

ACF is the result of adhesion of the IVC wall and that of the aneurysm, due to a periaortic adventitial inflammatory reaction, which can lead to adherence to the adjacent posterior veins. Aneurysmal wall shearing subsequently leads to an arteriovenous fistula. In the present case, post-peritoneal hematoma was found, which suggested that the ACF occurred as a result of the ruptured AAA and secondary inflammation.

To our knowledge, this is the first report of an AAA with an ACF in an Ehlers-Danlos syndrome patient.

Conclusions

ACF is a rare occurrence in the natural history of AAA. Although the clinical features are elusive, early diagnosis with appropriate investigations and treatment are essential. The surgical treatment is now standardized and consists of repair of the fistula from within the aneurysm with minimal dissection of surrounding structures. We successfully operated on a patient with AAA and multiple ACFs, using standard repair techniques, who was later diagnosed as having Ehlers-Danlos syndrome.

References

- Alexander JJ, Imbembo AL: Aorta-vena cava fistula. *Surgery* 1989; **105**: 1–12
- Syme J: Case of spontaneous varicose aneurysm. *Edinb Med J* 1831; **36**: 104–105
- Lehman E: Spontaneous arteriovenous fistula between the abdominal aorta and the inferior vena cava: Case report. *Ann Surg* 1938; **108**: 697–700
- Cooley D: Discussion of Javid H, Dye WS, Grove JW, Julian OC:

- Resection of ruptured aneurysms of the abdominal aorta. *Ann Surg* 1955; **142**: 623
5. Potyk DK, Guthrie CR: Spontaneous aortocaval fistula. *Ann Emerg Med* 1995; **25**: 424–427
 6. Fenster MS, Dent JM, Tribble C, Angle JF, Sarembock IJ, Komada M, et al: Aortocaval fistula complicating abdominal aortic aneurysm: Case report and literature review. *Cathet Cardiovasc Diagn* 1996; **38**: 75–79
 7. Farid A, Sullivan TM: Aortocaval fistula in ruptured inflammatory abdominal aortic aneurysm: A report of two cases and literature review. *J Cardiovasc Surg* 1996; **37**: 561–565
 8. Ghilardi G, Scorza R, Bortolani E, de Monti M, Longhi F, Ruberti U: Primary aortocaval fistula. *Cardiovasc Surg* 1994; **2**: 495–497
 9. Kiskinis DA, Saratzis N, Megalopoulos A, Hatzibaloglou A, Gitas C, Dalainas V: Primary aortocaval fistula in association with ruptured aneurysms. *Ann Vasc Surg* 1994; **8**: 496–499
 10. Parodi JC: Endovascular repair of abdominal aortic aneurysms and other arterial lesions. *J Vasc Surg* 1995; **21**: 549–557
 11. Woolley DS, Spence RK: Aortocaval fistula treated by aortic exclusion. *J Vasc Surg* 1995; **22**: 639–642
 12. Keulen CJV, Teijink JAW, Rauwerda JA: Inferior vena cava thrombosis, aortocaval fistula and aortic aneurysm: A unique combination. *Eur J Vasc Endovasc Surg* 1996; **12**: 501–502
 13. Ghilardi G, Scora R, Bortolani E, de Monti M, Longhi F, Ruberti U: Rupture of abdominal aortic aneurysms into the major abdominal veins. *J Cardiovasc Surg* 1993; **34**: 39–47
 14. Yamashita C, Kozawa S, Kujime K, Okada M: Successful surgical treatment of aortocaval fistula using cardiopulmonary bypass. *Cardiovasc Surg* 1995; **3**: 187–189
 15. Masood T, Naylor AR, Edge JMH, Stein AG, Barrie WW: Double aortovenous fistula: A unique presentation of a ruptured abdominal aortic aneurysm. *Eur J Vasc Surg* 1994; **8**: 107–109
 16. Miani S, Giorgetti PL, Arpesani A, Giuffrida GF, Biasi GM, Ruberti U: Spontaneous aorto-caval fistulas from ruptured abdominal aortic aneurysms. *Eur J Vasc Surg* 1994; **8**: 36–40
 17. Schmidt R, Bruns C, Walter M, Erasmi H: Aorto-caval fistula: an uncommon complication of infrarenal aortic aneurysms. *Thorac Cardiovasc Surg* 1994; **42**: 208–211
 18. Naito K, Sakai M, Itoh T: A new approach for aortocaval fistula from ruptured abdominal aortic aneurysm. *Thorac Cardiovasc Surg* 1994; **42**: 55–57
 19. Thompson RW, Yee LF, Natuzzi ES, Stoney RJ: Aorto-left renal vein fistula syndrome caused by rupture of a juxtarenal abdominal aortic aneurysm: Novel pathologic mechanism for a unique clinical entity. *J Vasc Surg* 1993; **18**: 310–315
 20. Länne T, Bergqvist D: Aortocaval fistulas associated with ruptured abdominal aortic aneurysms. *Eur J Surg* 1992; **158**: 457–465