

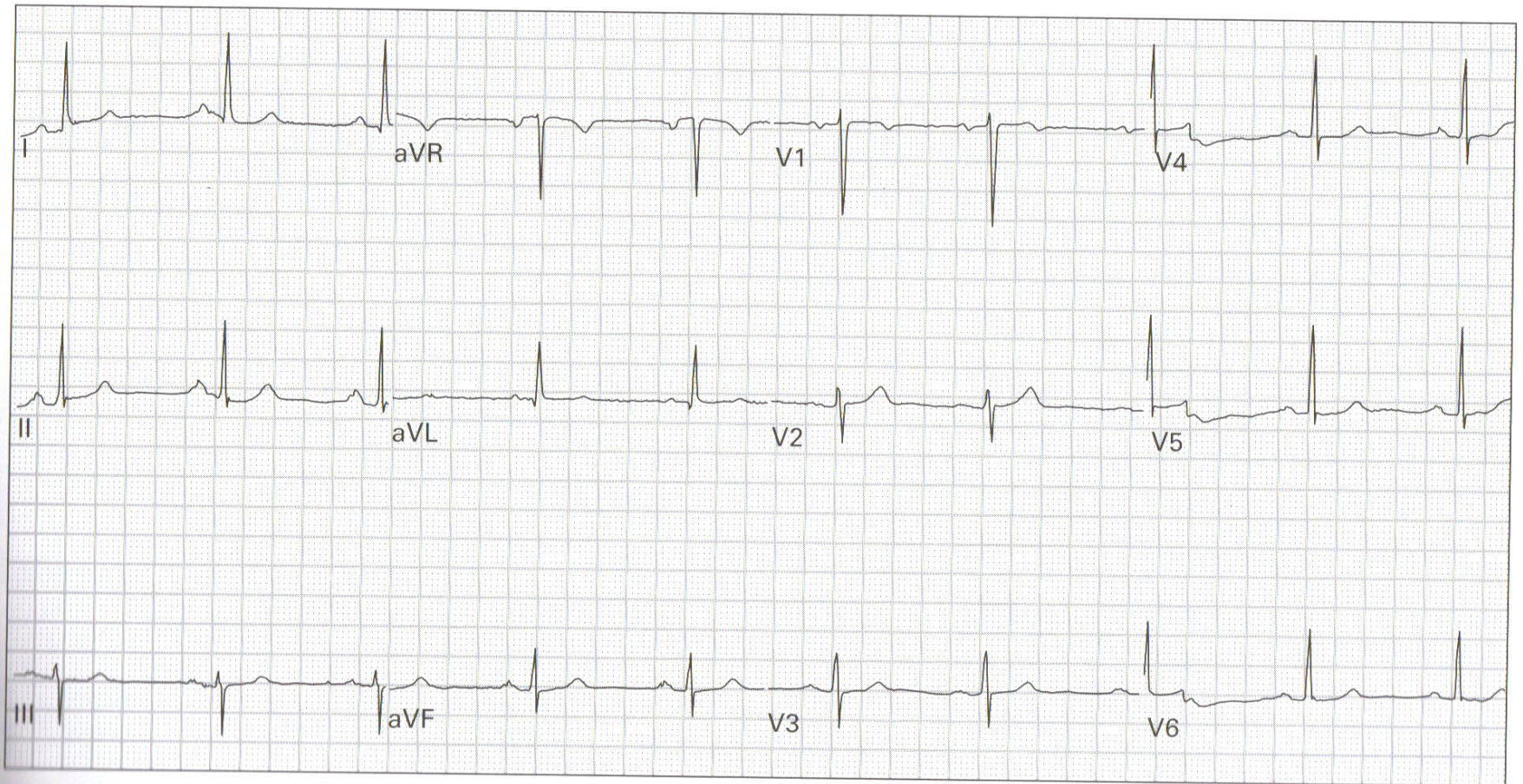
EKG Diagnosis Workshop

Jason Mansour, MD, FACEP
Broward General Medical Center
Department of Emergency Medicine

Be systematic !

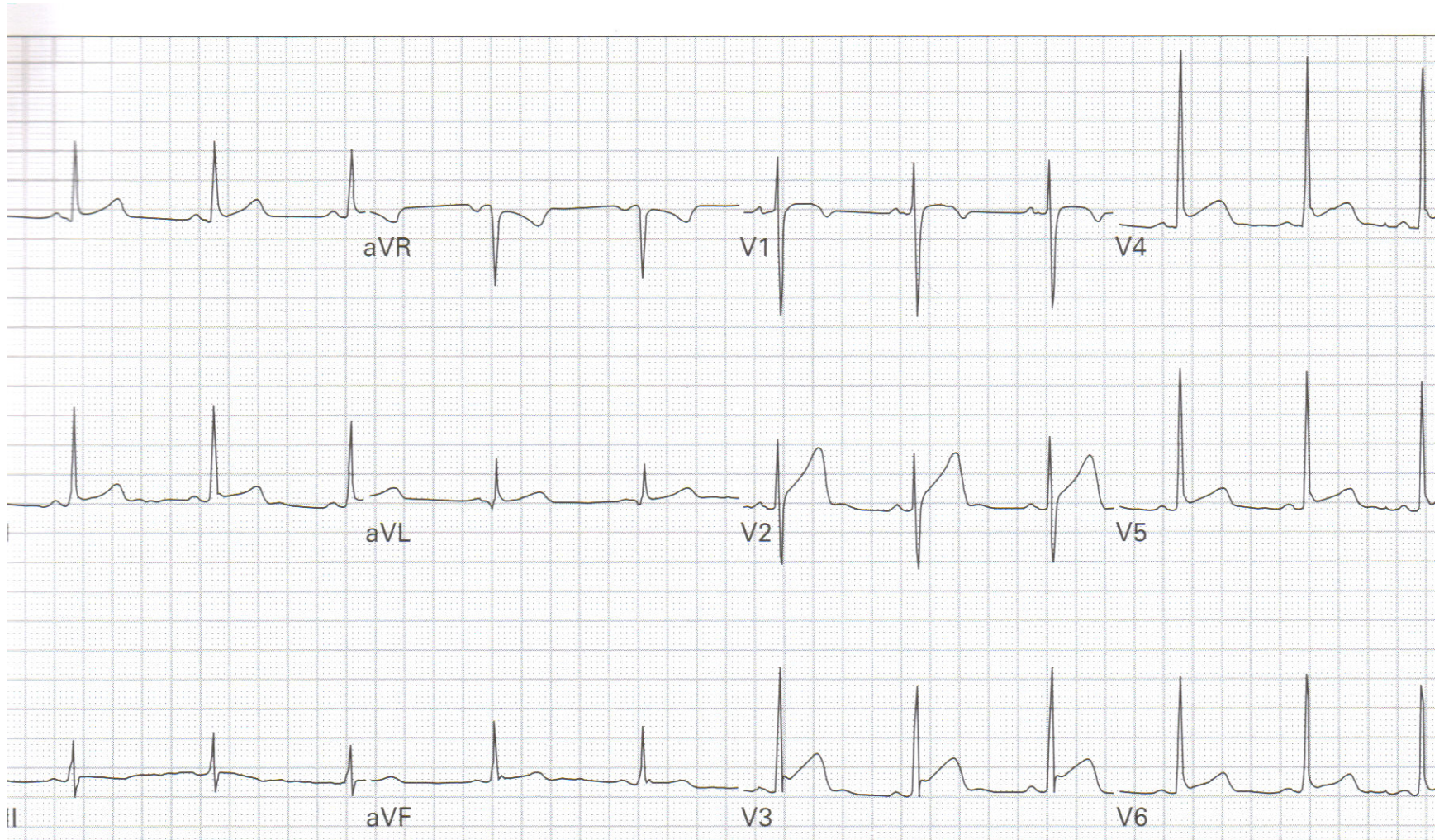
- Rhythm
- Rate
- Axis
- Intervals
- Hypertrophy
- Previous MI
- ST-T wave

EKG 1



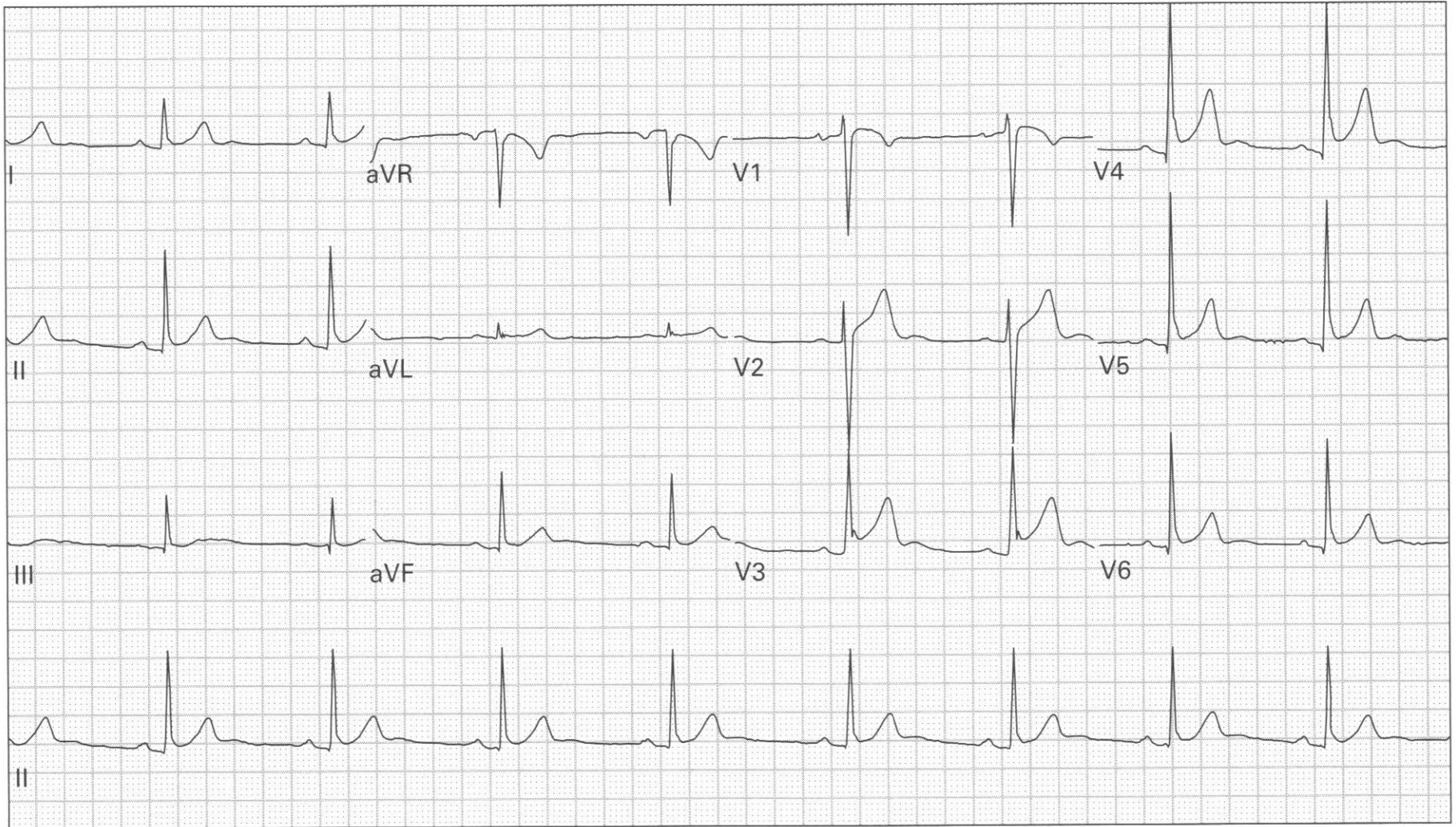
1. 45 year old woman, asymptomatic

EKG 2

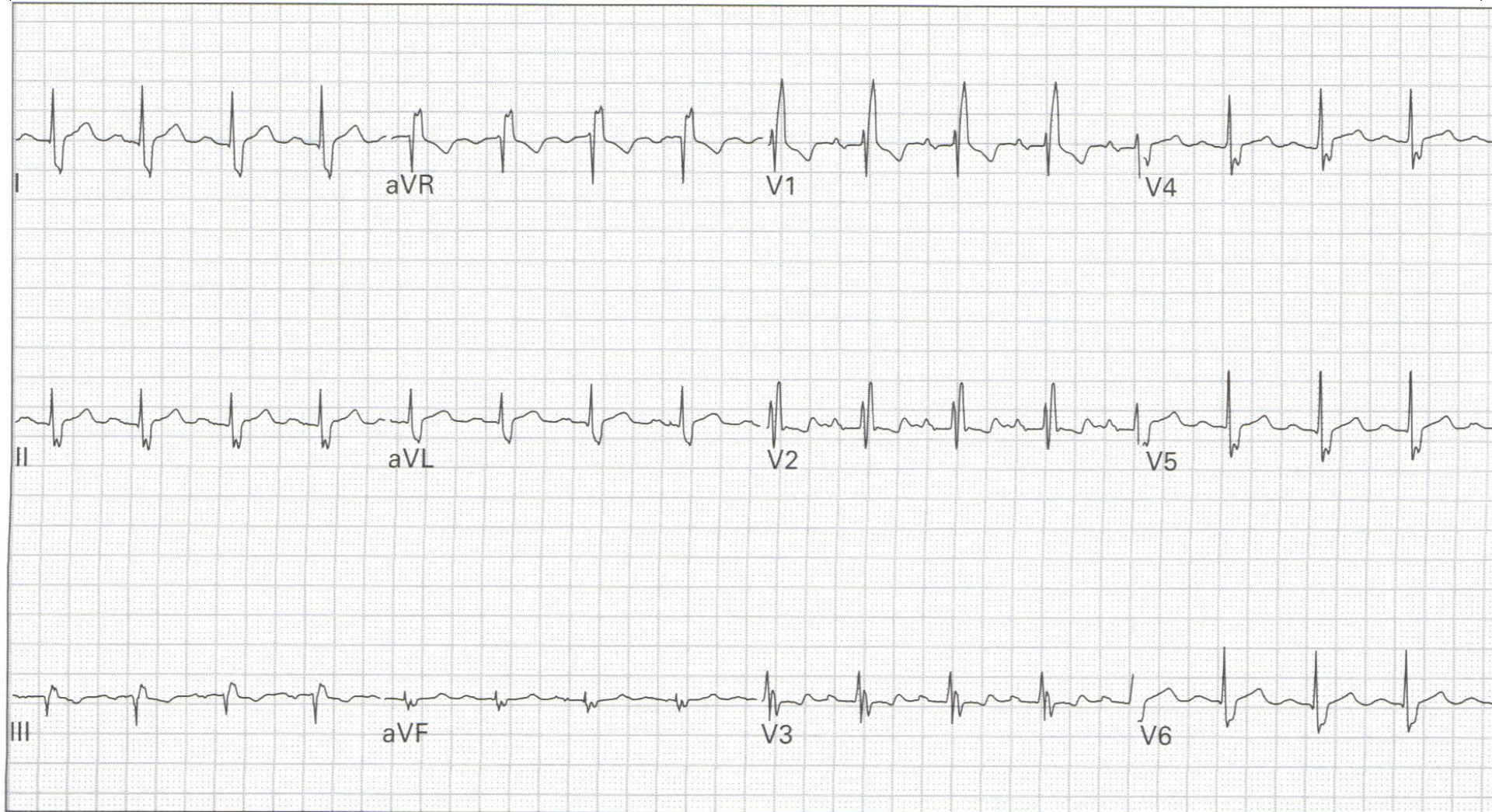


∴ 24 year old man with chest ache after lifting weights

EKG 3

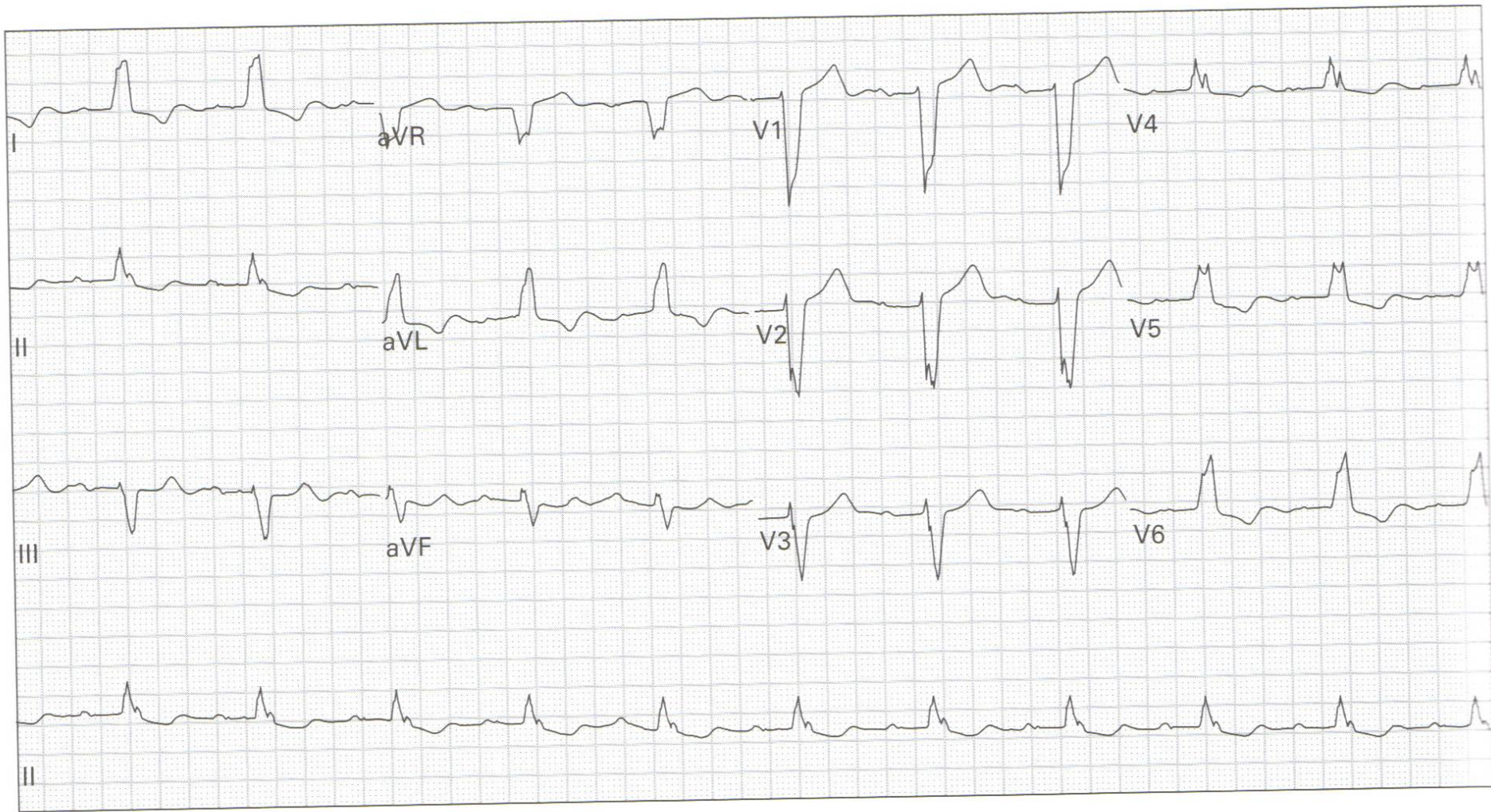


EKG 4



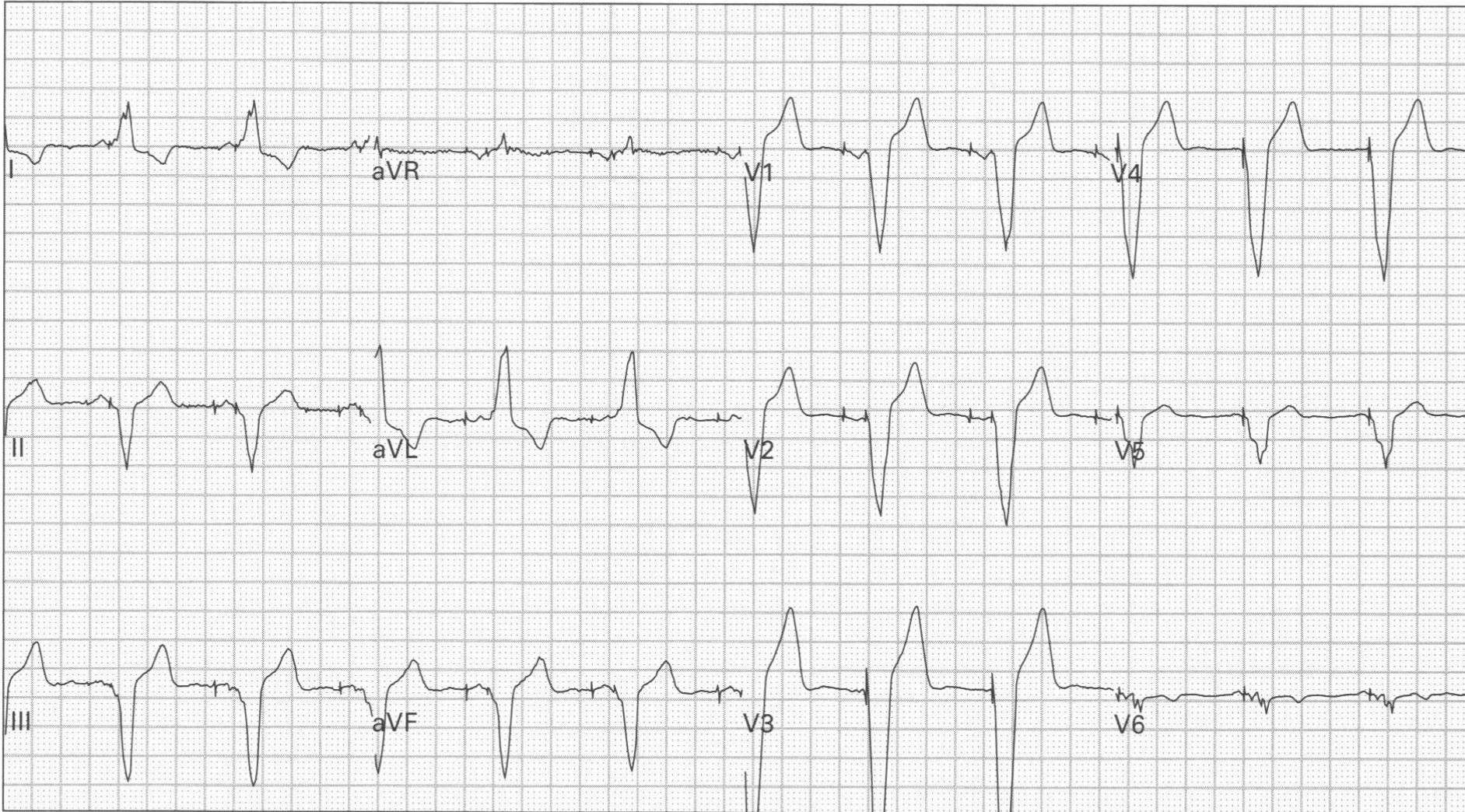
7. 43 year old man, asymptomatic

EKG 5



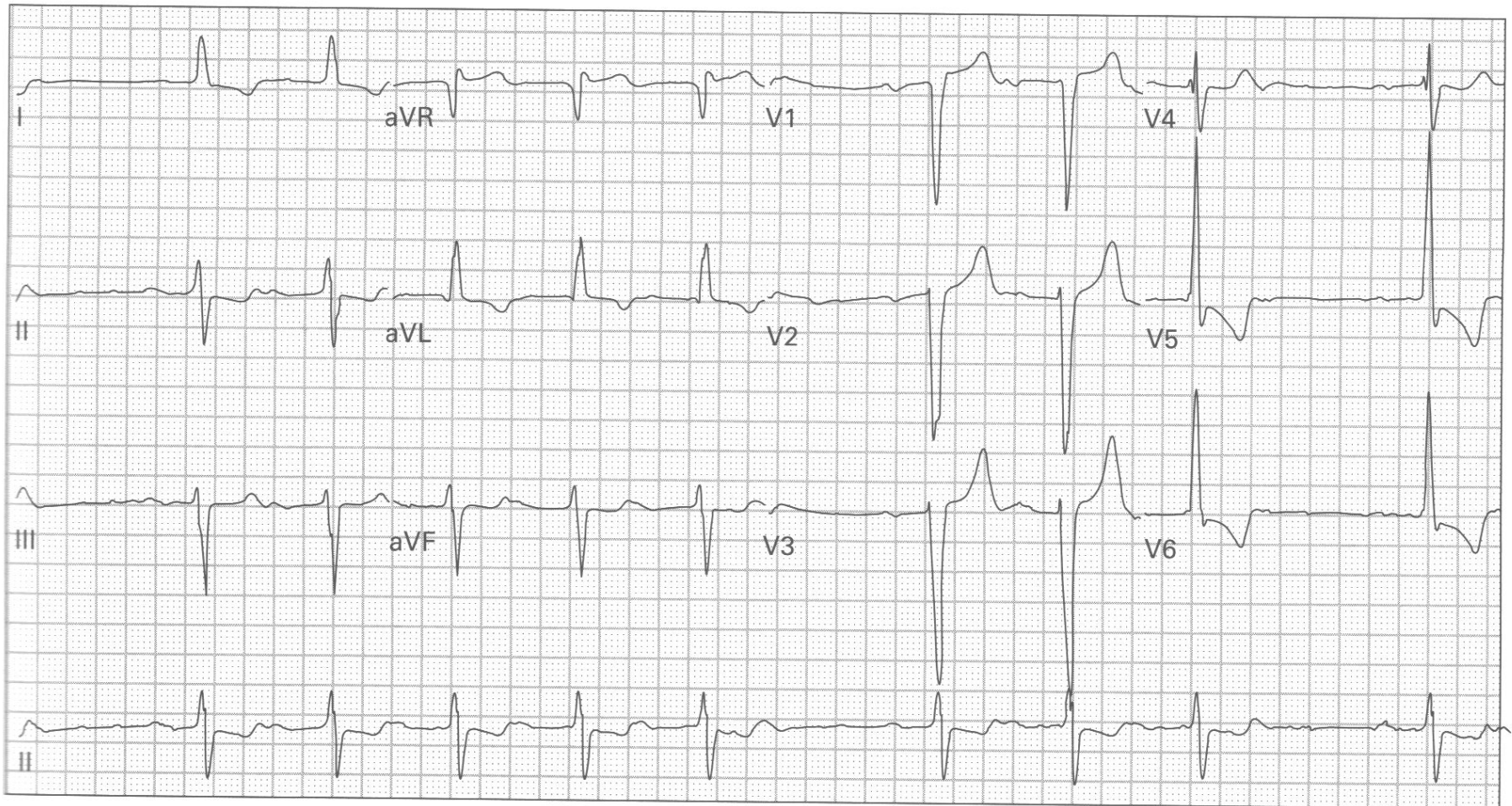
95. 84 year old woman with nausea and vomiting

EKG 6



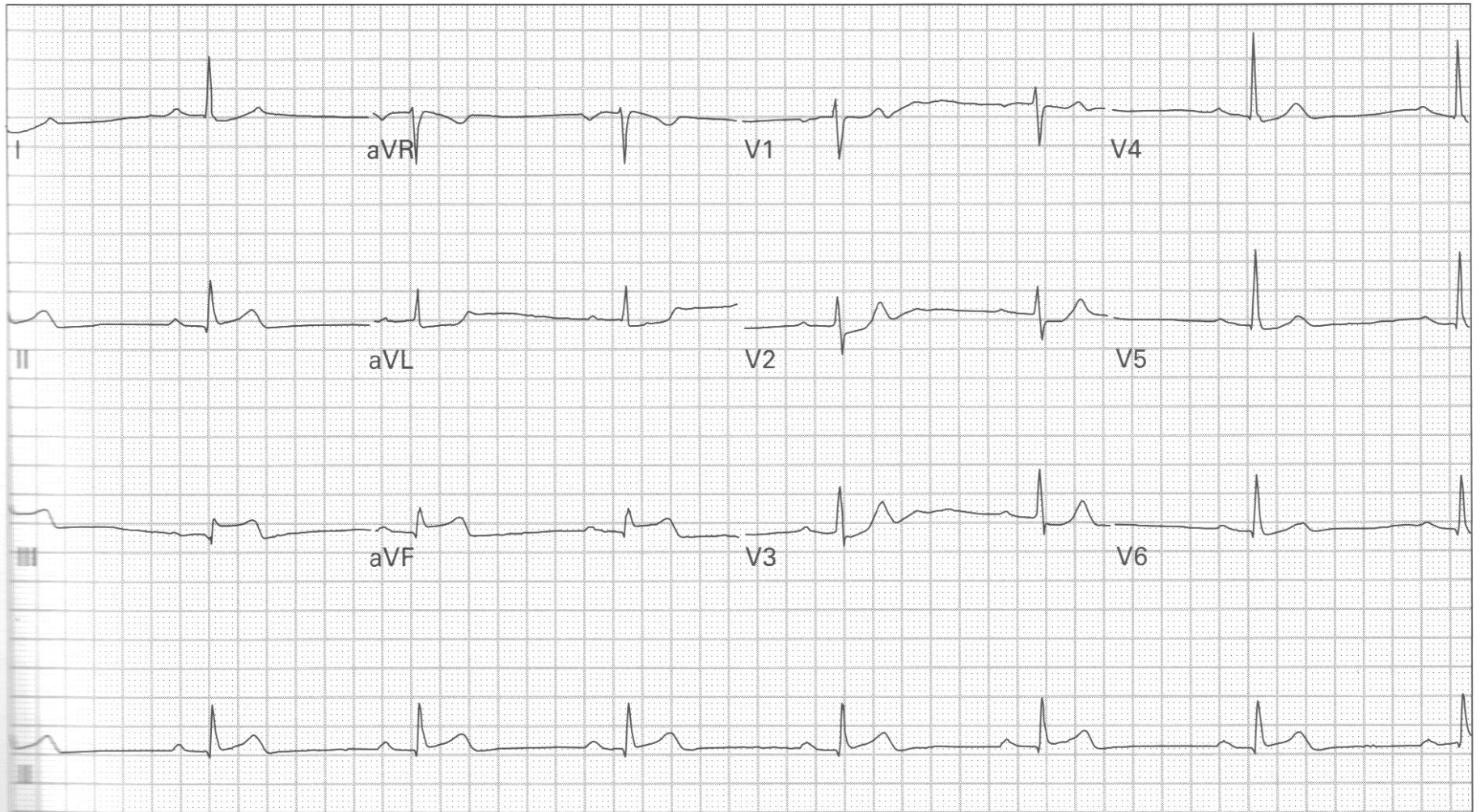
20. 61 year old man, asymptomatic

EKG 7



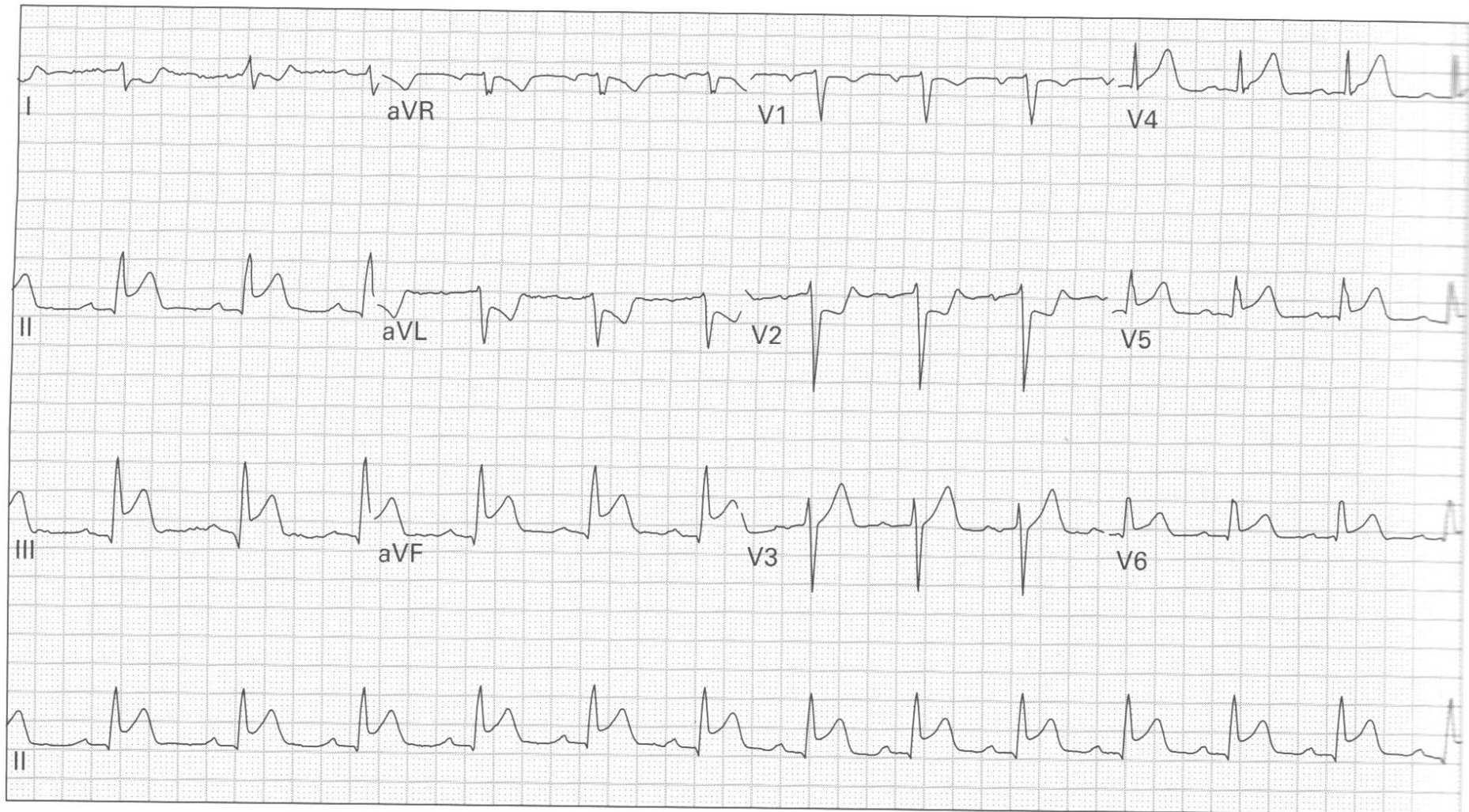121. 71 year old man with weakness and nausea

EKG 8



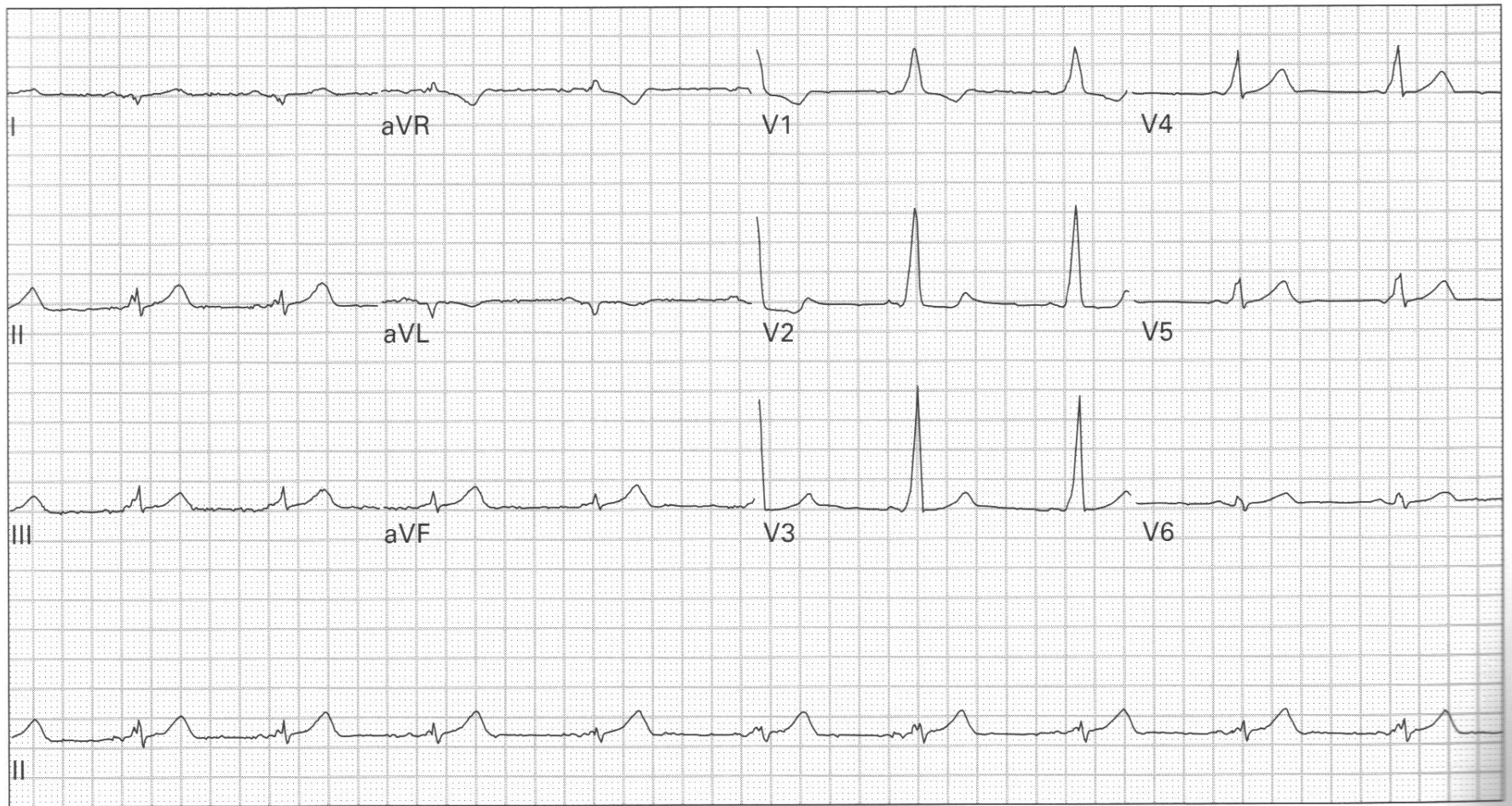
85. 63 year old man with epigastric burning, belching, diaphoresis, and lightheadedness

EKG 9



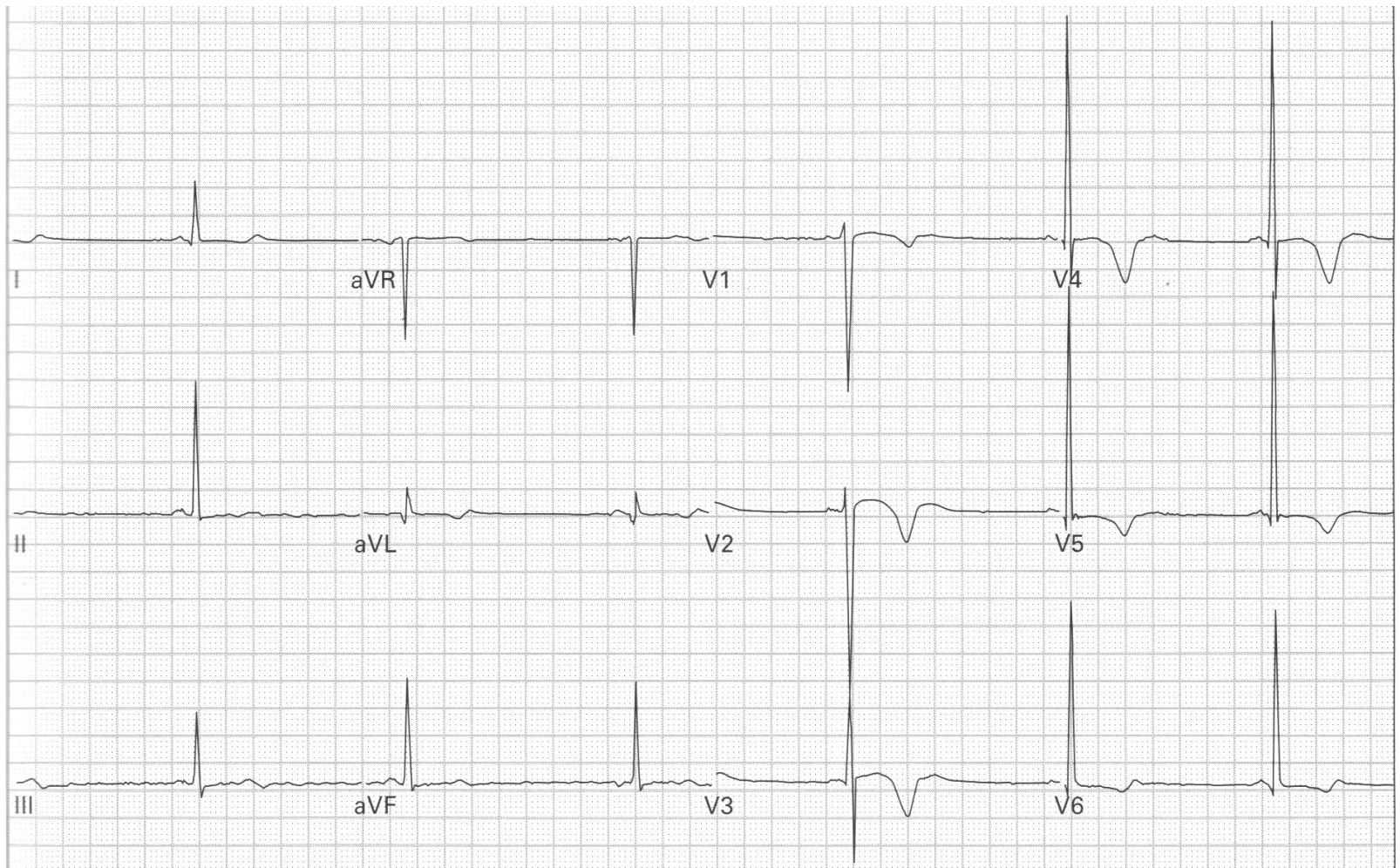
96. 57 year old man with chest pressure, dyspnea, and nausea

EKG 10



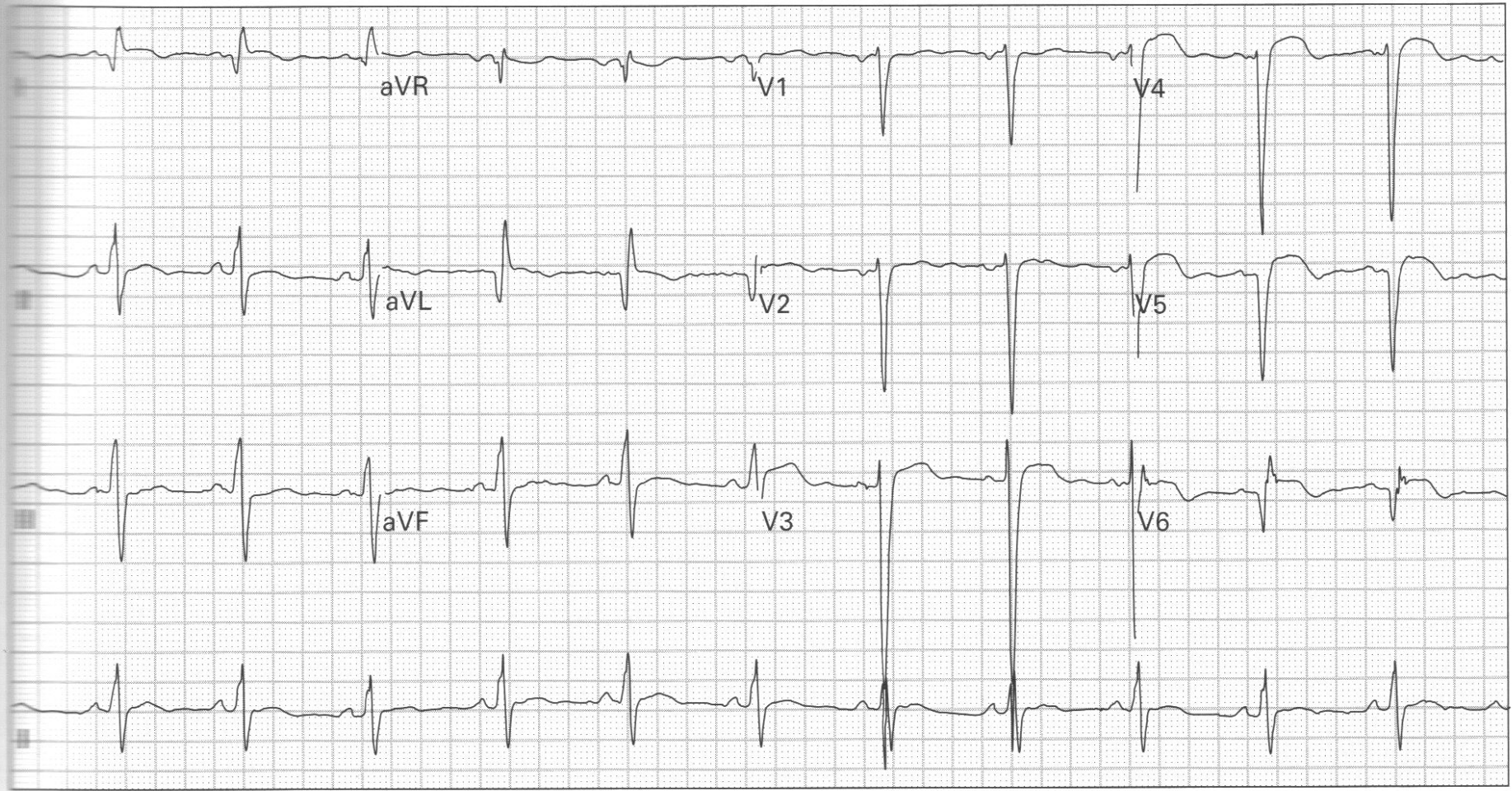
66. 36 year old woman has had intermittent episodes of palpitations and lightheadedness

EKG 11



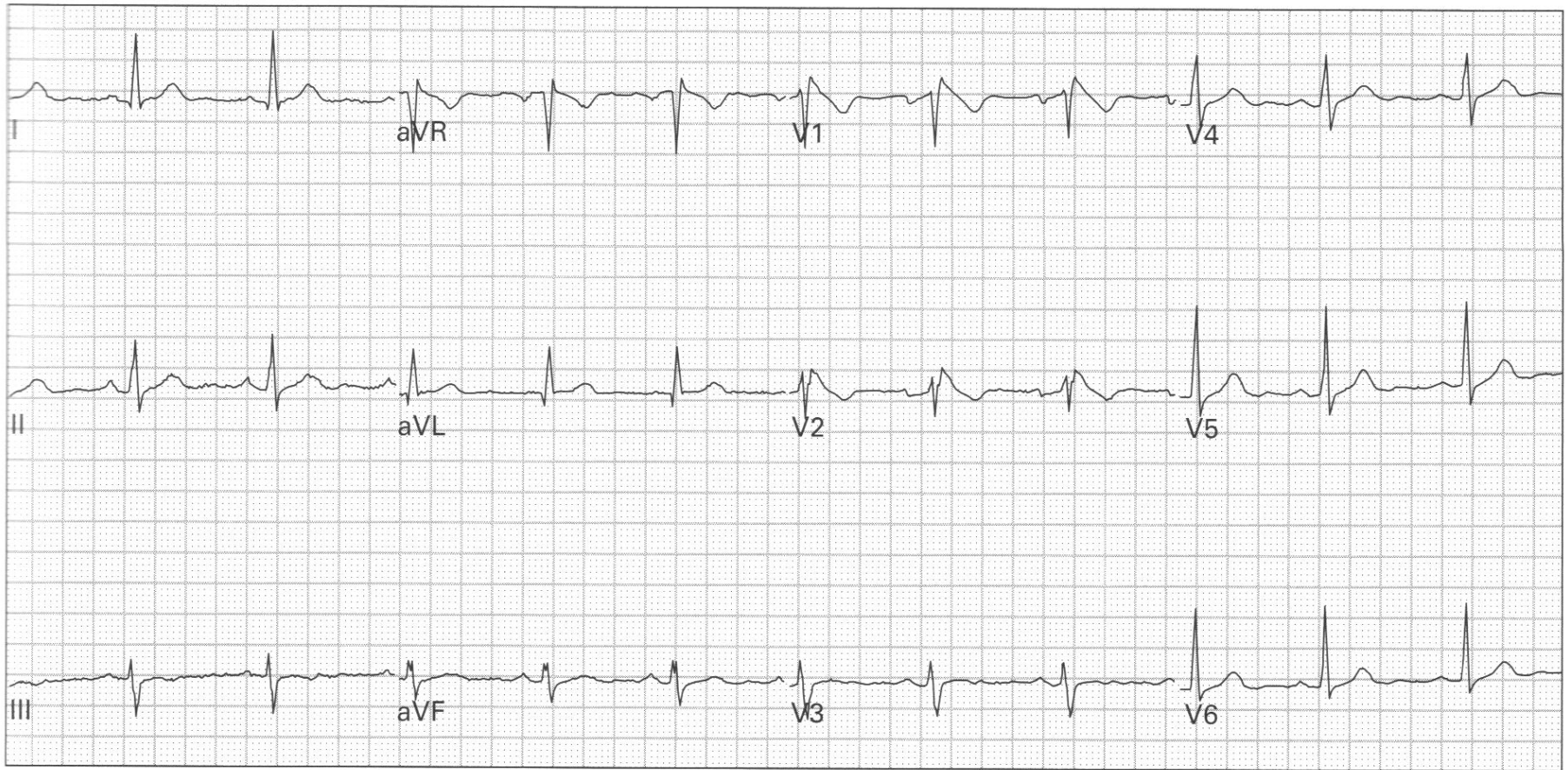
65. 34 year old woman presents unconscious with respiratory depression and pinpoint pupils

EKG 12



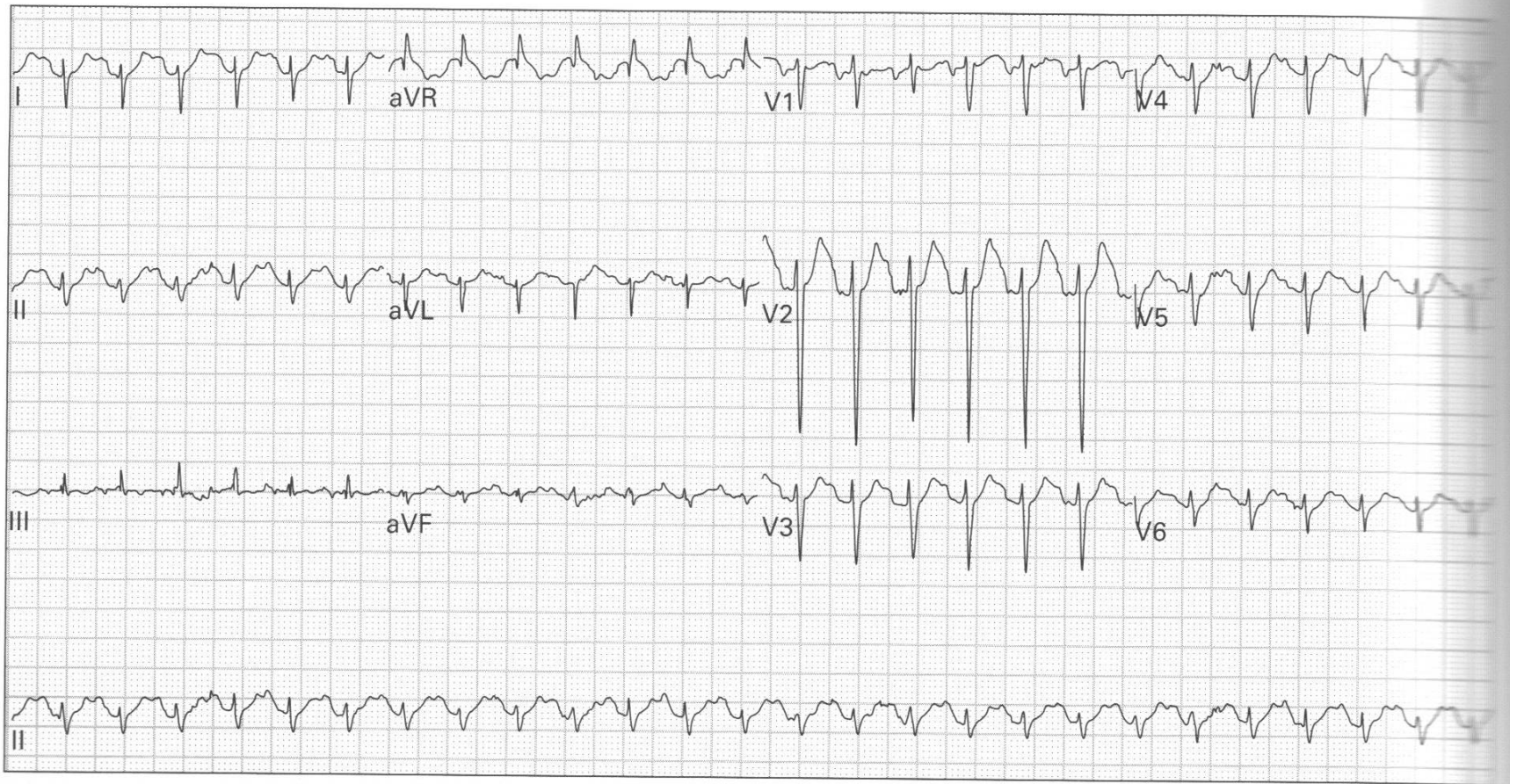
125. 56 year old woman with a history of a prior MI gets a pre-admission ECG; she is being admitted for cellulitis of the leg; she has no cardiopulmonary symptoms

EKG 13



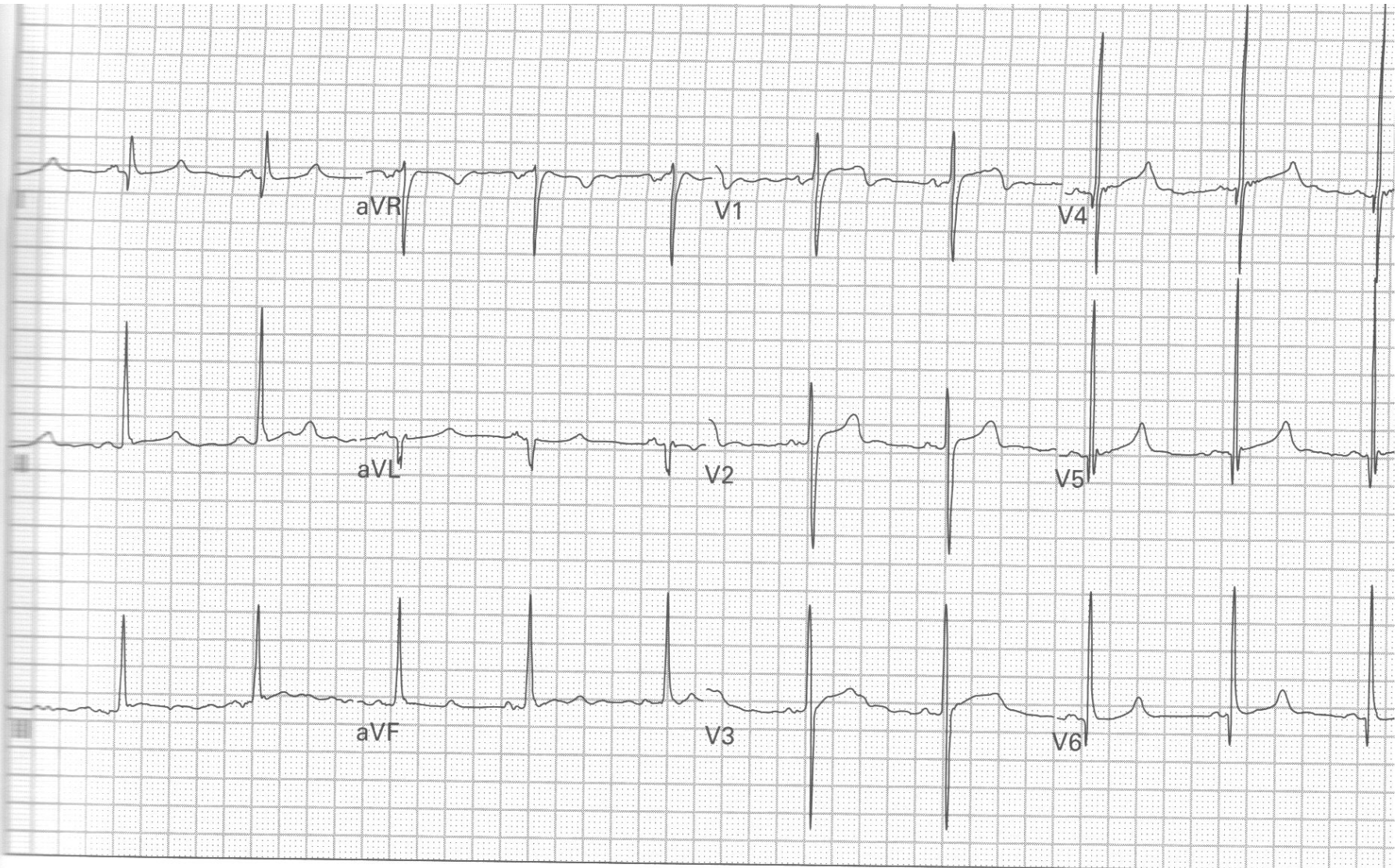
182. 54 year old woman presents after a syncopal episode

EKG 14



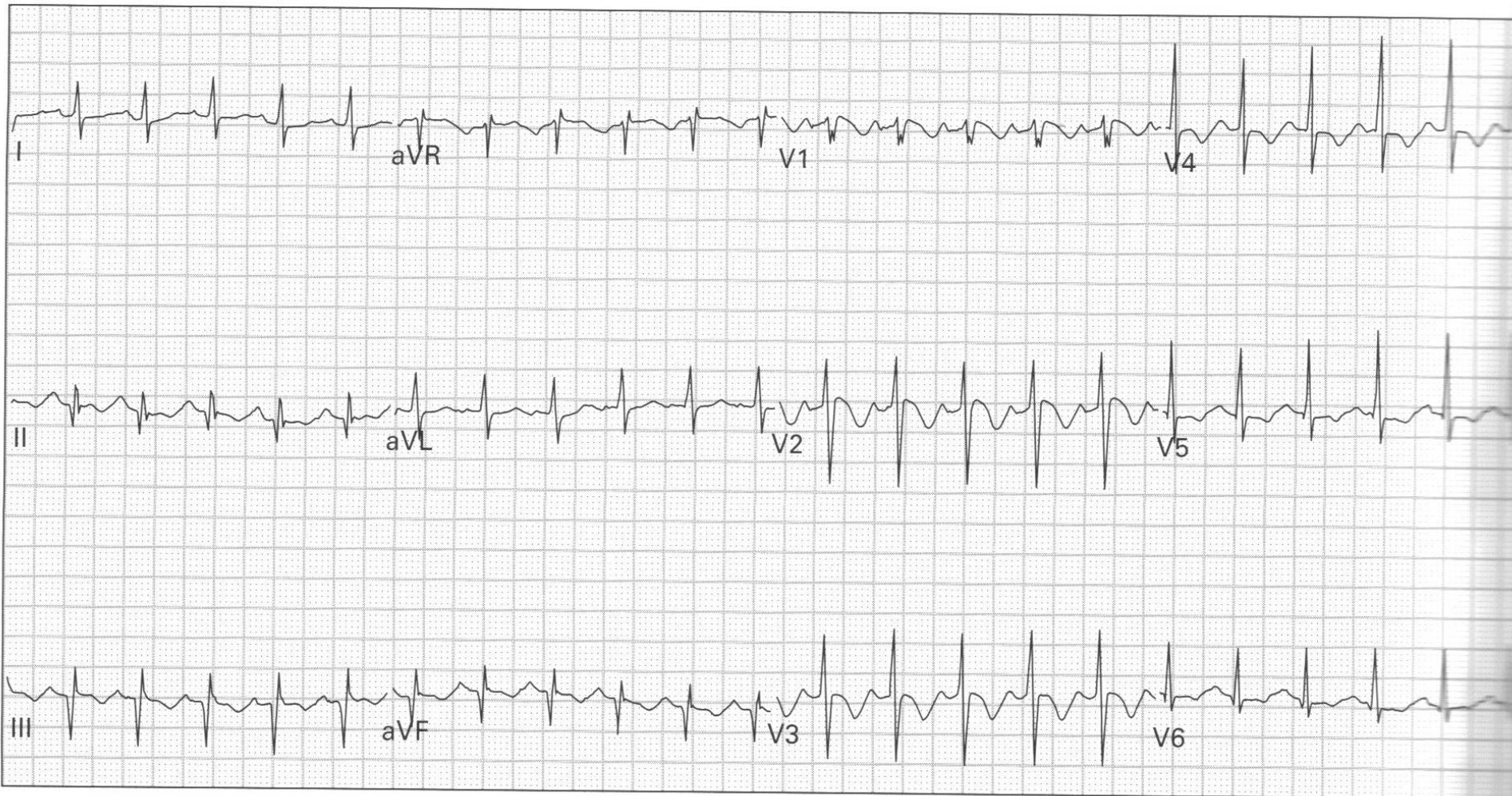
163. 37 year old woman presents after an unknown overdose

EKG 15



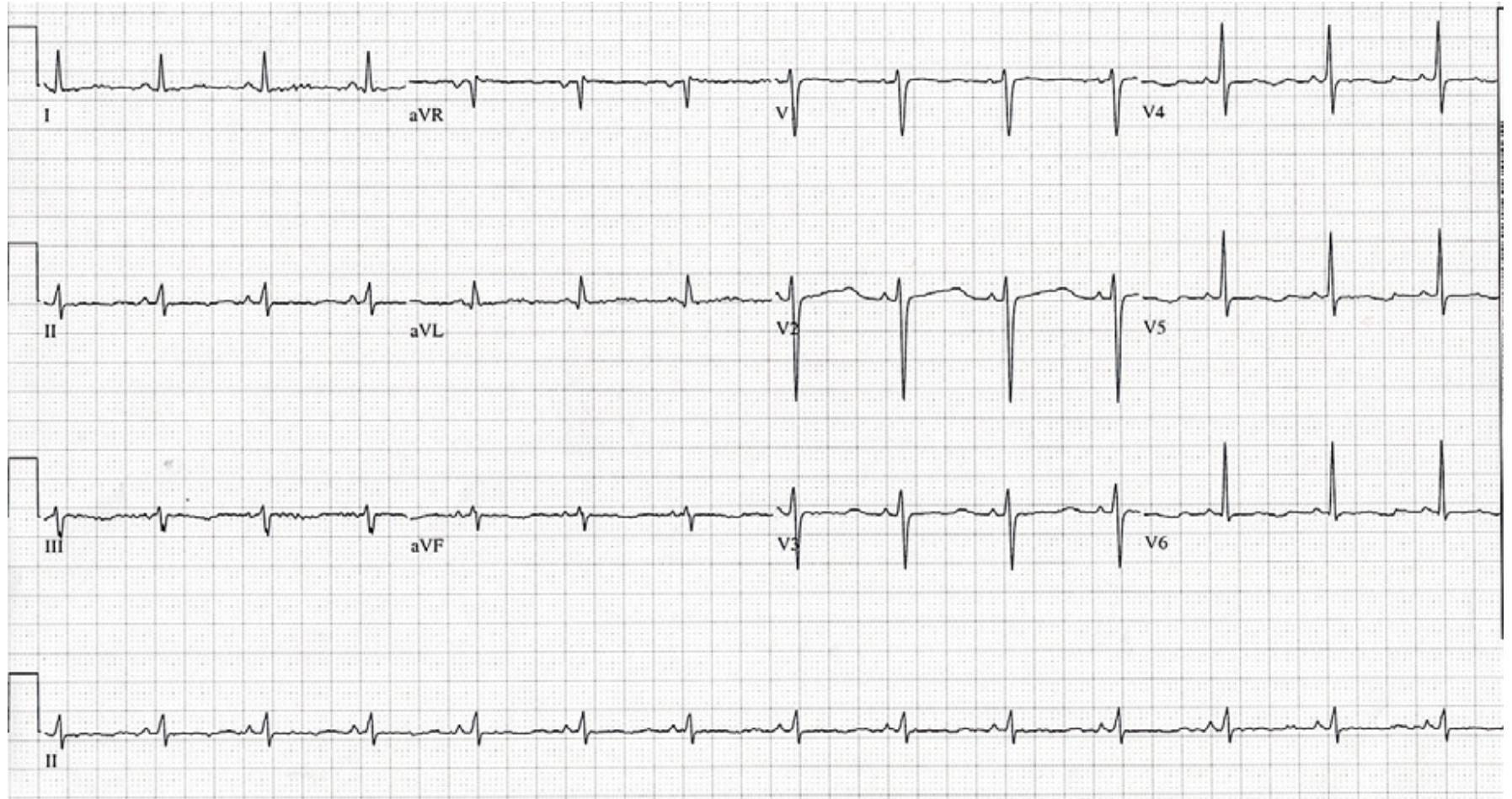122. 30 year old man with exertional palpitations and lightheadedness

EKG 16

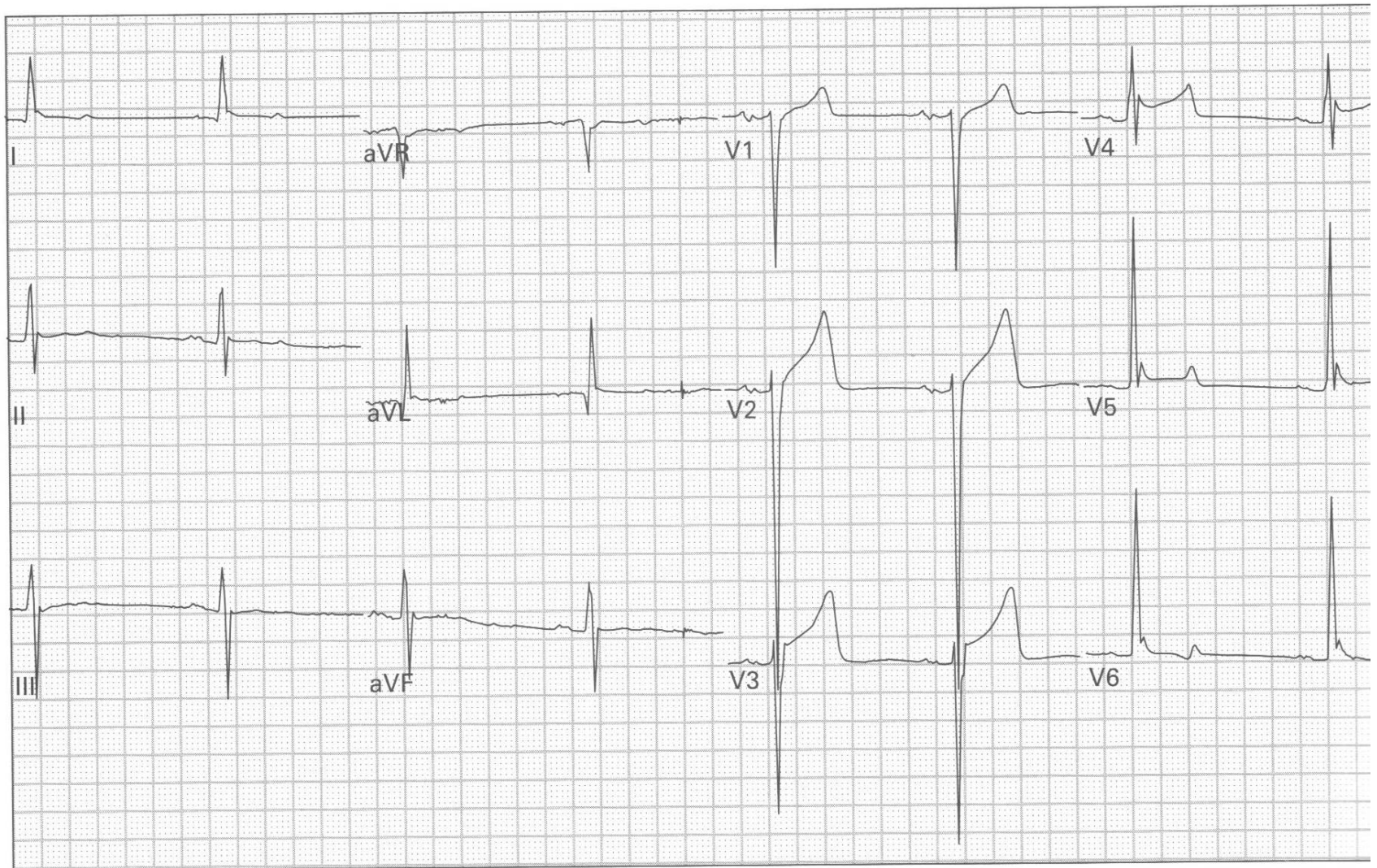


164. 50 year old man with chest pressure and dyspnea

EKG 17

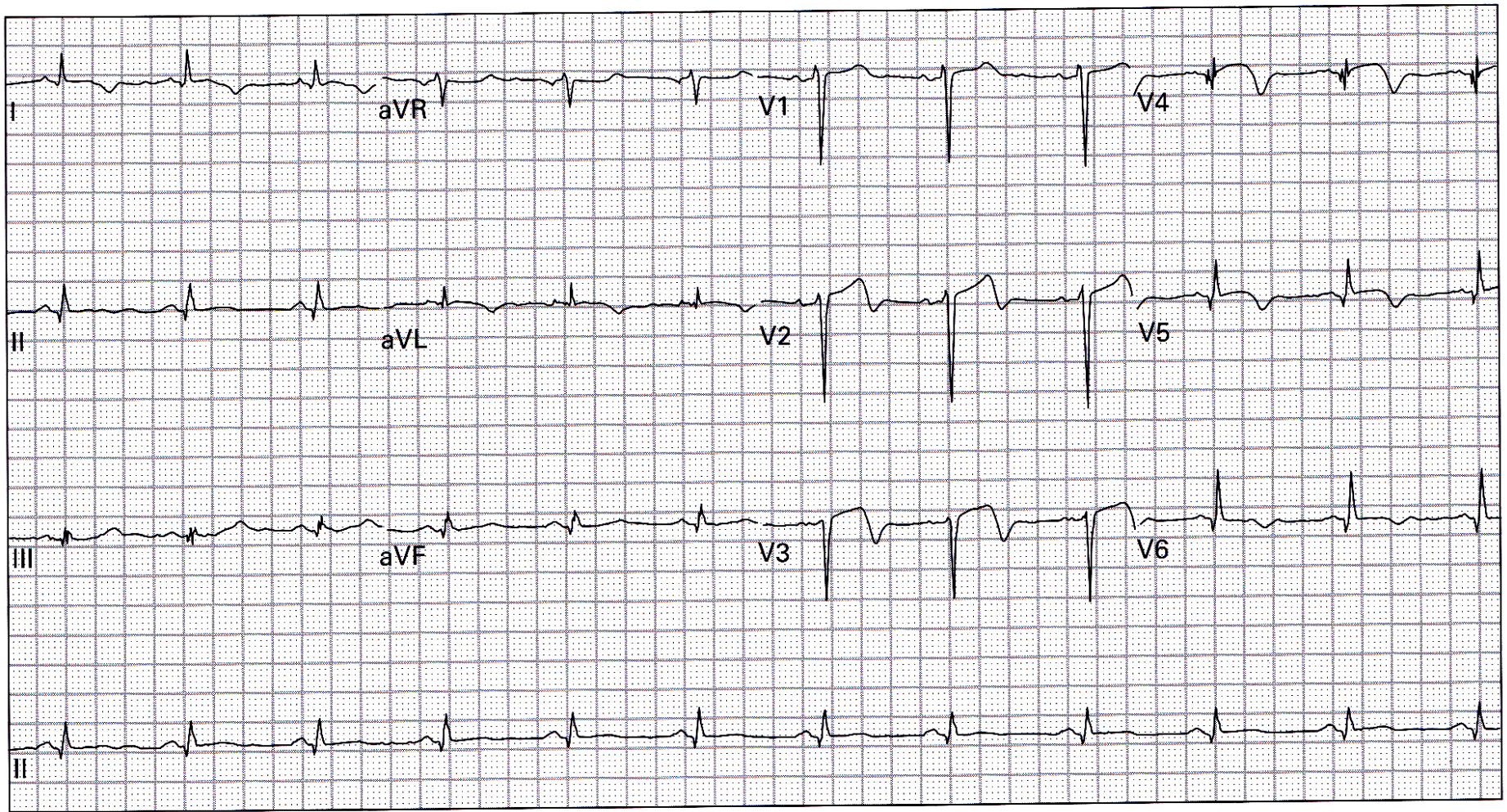


EKG 18



183. 71 year old man was sent to the emergency department from a nursing home because of lethargy

EKG 19



33. 54 year old man 24 hours after receiving thrombolytic therapy for acute myocardial infarction; currently asymptomatic