

CHEST[®]

Official publication of the American College of Chest Physicians



Ehlers-Danlos Syndrome and Cardiovascular Abnormalities

Jayant Antani and H. V. Srinivas

Chest 1973;63;214-217

The online version of this article, along with updated information and services can be found online on the World Wide Web at:
<http://chestjournal.chestpubs.org/content/63/2/214>

Chest is the official journal of the American College of Chest Physicians. It has been published monthly since 1935. Copyright 1973 by the American College of Chest Physicians, 3300 Dundee Road, Northbrook, IL 60062. All rights reserved. No part of this article or PDF may be reproduced or distributed without the prior written permission of the copyright holder.
(<http://chestjournal.chestpubs.org/site/misc/reprints.xhtml>) ISSN:0012-3692

A M E R I C A N C O L L E G E O F



C H E S T

P H Y S I C I A N S[®]

Ehlers-Danlos Syndrome and Cardiovascular Abnormalities

Jayant Antani, M.D., F.C.C.P.,* and H. V. Srinivas, M.D.**

During a period of seven years, a diagnosis of Ehlers-Danlos syndrome was made in 44 patients. The cases were studied with particular reference to involvement of the cardiovascular system. Fifteen patients had cardiac abnormalities and one patient had a vascular anomaly. There were two cases of atrial septal defect, one case of aortic incompetence, one case of left ventricular papillary dysfunction and one of dextrocardia. In the remaining cases, the cardiac abnormalities were nonspecific. One patient had a thoracic deformity and an apical systolic murmur. Electrocardiographic abnormalities included sinus bradycardia, grade 1 atrio-ventricular block, incomplete and complete right bundle branch block and non-specific ST-T changes. The literature on cardiovascular abnormalities in Ehlers-Danlos syndrome is reviewed. Cardiovascular abnormalities in Ehlers-Danlos syndrome are interesting and not an uncommon feature.

Ehlers-Danlos syndrome is a rare syndrome of considerable interest to the clinician, geneticist and cardiologist. It is a familial condition and is usually inherited as an autosomal dominant trait, though an x-linked form of the syndrome has also been described.¹

So far, more than 500 cases have been reported in the world literature. Many reports stress different interesting aspects of the cases.¹⁻¹⁰ There have been several reports of cardiac abnormalities in patients with Ehlers-Danlos syndrome, but it is not certain whether these anomalies are a part of the syndrome or whether they represent chance concomitants.⁸

Because of the infrequent reports of this syndrome in Indian patients, particularly with cardiovascular abnormalities, the results of the clinical and investigative aspects of these patients from the cardiovascular point of view, are presented in this paper.

MATERIAL AND METHODS

Material for this study consisted of 44 patients (26 members in six families, and 18 other cases) with the definite diagnosis of Ehlers-Danlos syndrome, examined personally in

*Consultant Physician and Cardiologist, Associate Professor of Medicine, Medical College, Gulbarga, Mysore, India.

**Assistant Professor of Medicine, Medical College, Gulbarga, Mysore, India.

Reprint requests: Dr. Antani, Mill Road, Gulbarga 2, Mysore, India

private consulting practice and in the medical unit of the Government General Hospital, over a period of seven years (1965-1971). The diagnosis of Ehlers-Danlos syndrome was made if any four of the following seven clinical features were present: hyperextensible skin which could be stretched for a few centimeters (Fig 1); skin which tended to split on minor

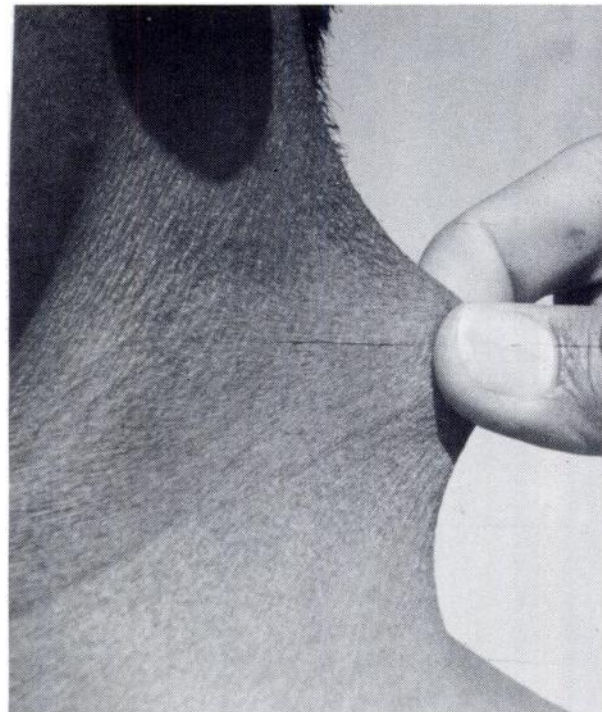


FIGURE 1. Ehlers-Danlos syndrome with hyperextensible skin.

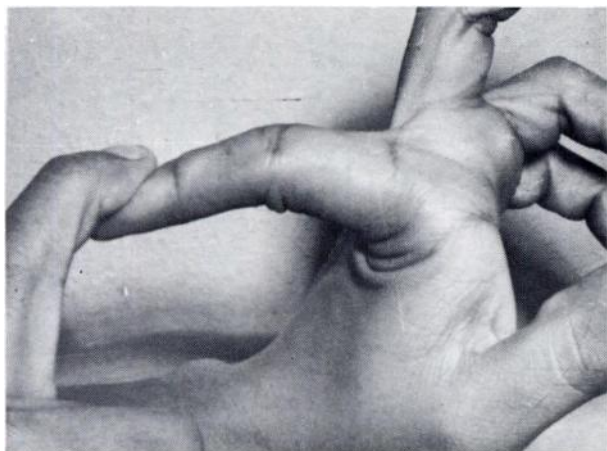


FIGURE 2. Ehlers-Danlos syndrome with joint hypermobility.

trauma and later heal with a thin scar; joint hypermobility (Fig 2); musculoskeletal deformity (Fig 3); a bleeding diathesis; a familial tendency; and nodules in the skin. The cardiovascular assessment was made by clinical, electrocardiographic and radiologic methods. In addition, routine blood counts, bleeding and clotting time, prothrombin time, and platelet counts were done in these patients.

RESULTS

There were 44 patients with Ehlers-Danlos syndrome, 16 who had cardiovascular abnormalities. In one patient a diagnosis of full fledged aortic incompetence with left ventricular hypertrophy and left heart failure was made. Two other patients had atrial septal defects. One patient had papillary dysfunction, left ventricular hypertrophy. In the remaining cases, the cardiac findings were not consistent with any valvular or congenital heart disease (Table 1). Four patients had a short, soft localized grade 2, midsystolic murmur in the mitral area, and one had a thoracic deformity, which might account for the murmur. One patient had a localized grade 3, pansystolic murmur in the mitral area, with no clue to the valvular lesion. Another patient had a soft localized grade 2 middiastolic murmur in the mitral area. A pulmonary ejection systolic murmur was heard in two patients. There

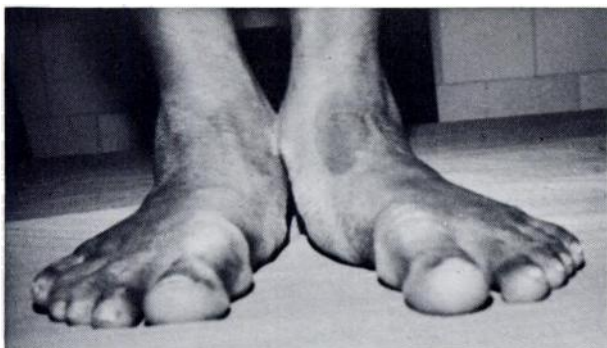


FIGURE 3. Ehlers-Danlos syndrome with flat foot musculoskeletal deformity.

were two patients with multiple ventricular premature beats, of which one had dextrocardia. One patient had sinus bradycardia and a normal heart. In another case, vascular abnormality presented as absent radial and ulnar pulses on both the sides. In this patient, the cardia was normal. Angiography was not performed.

Electrocardiographic and radiologic findings of left ventricular hypertrophy were corroborative in patients with aortic incompetence and papillary dysfunction. Incomplete right bundle branch block (RBBB) was observed in two patients with atrial septal defect (ASD) in whom radiologic examination revealed right ventricular hypertrophy. Complete RBBB was observed in one patient who had only a pulmonary ejection systolic murmur. Grade 1 atrioventricular (A-V) block was observed in one patient. Multiple multifocal ventricular premature beats were observed in two cases. One patient had sinus bradycardia. The diagnosis of dextrocardia in one case was confirmed through radiologic and electrocardiographic examinations. In the remaining cases, ECG findings were either normal or nonspecific (Table 1). The routine blood counts, bleeding, clotting and prothrombin time and platelet counts were within normal limits.

DISCUSSION

There are only a few reports in the world literature describing the cardiovascular findings in cases of Ehlers-Danlos syndrome. Beighton,⁶ in his study of 100 patients with Ehlers-Danlos syndrome, described 29 patients who had cardiac abnormalities. In his series, 24 patients had a systolic murmur which he attributed either to a thoracic wall deformity or were of a benign nature. Although in the present series there were six patients with apical systolic murmur, only one had a thoracic deformity. Of a total of 44 cases of Ehlers-Danlos syndrome associated with cardiac abnormalities so far described in the medical literature, six patients had anomalies of the aorta and the aortic arch (Table 2). In the present series, no patient had an aortic arch abnormality. One patient, a man aged 22, had gross aortic incompetence. Tucker et al,¹¹ and Gupta and Roshanlal,¹⁰ in their studies described one case each of aortic incompetence. This makes the third report of aortic incompetence in the Ehlers-Danlos syndrome so far reported. In one patient in the present observations, who had impalpable radial and ulnar arteries on both sides, detailed angiographic studies were not done.

There have been previous reports of mitral valvular disease in patients with Ehlers-Danlos syndrome.^{8,12} Mitral or tricuspid valvular lesions were

Table 1—Data on 16 patients with Ehlers-Danlos Syndrome with cardiac abnormalities

Case, No	Age, Yr	Sex	Cardiac Abnormality	ECG Findings	X-ray
1	23	man	AI* with LVH**	LVH**	aortic knuckle prominent
2	16	boy	ASD†	incomplete RBBB††	consistent with ASD
3	14	boy	apical pansystolic murmur	nonspecific ST-T changes	NRA•
4	20	woman	apical systolic murmur	grade 1 A-V block	NRA•
5	12	boy	ASD†	incomplete RBBB	consistent with ASD
6	32	man	papillary dysfunction, LVH**	LVH**	suggestive of LVH
7	8	girl	soft middiastolic murmur in apical area	normal	NRA•
8	14	boy	apical systolic murmur with thoracic deformity	normal	severe kyphosis
9	9	girl	pulmonary ejection systolic murmur	nonspecific ST-T changes	prominent pulmonary artery
10	15	boy	pulmonary ejection systolic murmur	RBBB††	NRA•
11	24	man	cardia normal, absent radial ulnar pulses	normal	NRA•
12	15	girl	apical systolic murmur	normal	NRA•
13	19	man	apical systolic murmur	normal	NRA•
14	21	man	cardia normal, multiple VPBs¶	multiple multifocal VPBs¶	NRA•
15	31	man	dextrocardia, multiple VPBs¶	multiple multifocal VPBs¶	dextrocardia
16	27	woman	cardia normal, bradycardia	sinus bradycardia pulse 40 per min	NRA•

*Aortic incompetence. **Left ventricular hypertrophy. †Atrial septal defect. ††Right bundle branch block.
•No radiologic abnormality. ¶Ventricular premature beats.

not demonstrable in any of the cases in the present study. Association of atrial septal defect has been reported in Ehlers-Danlos syndrome earlier.^{3,13,14} The present series is comprised of two cases of ASD with Ehlers-Danlos syndrome.

Gupta and Roshanlal¹⁰ described for the first

Table 2—Cardiac Abnormalities in Ehlers-Danlos Syndrome

Author	Yr	Cardiac Abnormality
Margarot et al ¹⁵	1933	systolic murmur
Freeman ¹³	1950	atrial septal defect
Wallach et al ¹⁶	1950	Fallot's tetralogy
Fantl et al ³	1961	partial atrioventricular canal; left leaflets of mitral and tricuspid valve
Sestak ¹⁴	1962	atrial septal defect with tricuspid incompetence
Madison et al ¹²	1963	mitral and tricuspid incompetence
Tucker et al ¹¹	1963	aortic regurgitation; aneurysm of right sinus of Valsalva, pulmonary hypertension
Robitaille ⁷	1964	abnormal aortic arch
Rubinstein and Cohen ¹⁹	1964	"congenital cardiac defect"
Mcfarland et al ¹⁷	1964	bicuspid tricuspid valve
Bopp et al ¹⁸	1965	abnormal aortic arch; bifid pulmonary artery
McKusick ⁸	1966	aortic stenosis and mitral incompetence
McKusick ⁸	1966	systolic and diastolic murmur with dilated right side of heart
Beighton ⁶	1969	systolic murmur 24 cases (11 with chest deformity); mitral incompetence 1 case; right aortic arch—1 case; RBBB—3 cases
Gupta and Roshanlal ¹⁰	1971	case with AI; one case with VPBs

time VPBs (ventricular premature beats) in a case of Ehlers-Danlos syndrome. The present study consists of two such cases. Beighton⁶ observed incomplete RBBB with pulmonary ejection murmur in two cases; whereas in the present study two patients with ASD had incomplete RBBB and one had complete RBBB with a pulmonary ejection murmur. Other abnormal ECG findings reported include sinus bradycardia, complete heart block, wandering pacemaker, low voltage flat T-waves and abnormal T-wave vectors. In the present study we observed one patient with sinus bradycardia and one with grade 1 A-V block.

Interesting manifestations and associations with Ehlers-Danlos syndrome such as rupture of the great vessels, arteriovenous malformations, Fallot's tetralogy, tricuspid stenosis, aortic arch abnormalities, aneurysm of the right sinus of Valsalva which was associated with aortic incompetence and pulmonary hypertension, tricuspid valve with two leaflets, diverticulosis of the colon, herniae, perforations of the bowel, and rupture of lung tissue, have all been documented in the world medical literature, in addition to the observations discussed in the present study.

It is difficult to attribute many of the cardiac findings noted in the present series, directly to this inherited connective tissue disorder. Beighton⁶ thought that the structural cardiac abnormalities in the Ehlers-Danlos syndrome were mostly a chance association or very infrequent true concomitants of the Ehlers-Danlo syndrome. However, it is certain that a wide spectrum of cardiac abnormalities

do occur in this interesting condition which is worth noting.

ACKNOWLEDGMENTS: We wish to thank Dr. Hanshetti, Principal, Medical College, Gulbarga and to Dr. Kantharaj Shetty, District Surgeon, Government General Hospital, Gulbarga for allowing us to publish the paper. Our thanks are due to Mr. Rao for his secretarial assistance.

REFERENCES

- 1 Beighton P: X-linked recessive inheritance in the Ehlers-Danlos syndrome. *Br Med J* 3:409, 1968
- 2 Beighton P: Lethal complications of the Ehlers-Danlos syndrome. *Br Med J* 3:656, 1968
- 3 Fantl P, Morris KN, Sawers RJ: Repair of cardiac defect in patient with Ehlers-Danlos syndrome. *Br Med J* 1:1202, 1961
- 4 Lynch HT, Larsen AL, Wilson R, et al: Ehlers-Danlos syndrome, and "congenital" arteriovenous fistulae. *JAMA* 194:1011, 1965
- 5 Premberton JW, Freeman HW, Schepens CL: Familial retinal detachment and the Ehlers-Danlos syndrome. *Arch Ophthalmol* 76:817, 1966
- 6 Beighton P: Cardiac abnormalities in the Ehlers-Danlos syndrome. *Br Heart J* 31:227, 1969
- 7 Robitaille GA: Ehlers-Danlos syndrome and recurrent hemoptysis. *Ann Intern Med* 61:716, 1964
- 8 McKusick VA: *Heritable Disorders of Connective Tissue*. St. Louis, C. V. Mosby, 1966, p 179-229
- 9 Krishna Mohan KB, Rami Reddy P: Ehlers-Danlos syndrome—a case report. *J Assoc Physicians India* 18:953, 1970
- 10 Gupta KK, Lal R: Two cases of Ehlers-Danlos syndrome with cardiac abnormalities. *Indian Heart J* 23:296, 1971
- 11 Tucker DH, Miller DE, Jacoby WJ: Ehlers-Danlos syndrome with a sinus of Valsalva aneurysm and aortic insufficiency simulating rheumatic heart disease. *Am J Med* 35:715, 1963
- 12 Madison WM Jr, Bradley EJ, Castillo AJ: Ehlers-Danlos syndrome with cardiac involvement. *Am J Cardiol* 11:689, 1963
- 13 Freeman JT: Ehlers-Danlos syndrome. *Am J Dis Child* 79:1049, 1950
- 14 Sestak Z: Ehlers-Danlos syndrome and cutis laxa, an account of families in the Oxford area. *Ann Hum Genet* 25:313, 1962
- 15 Margarot J, Deveze P, De Carrera AJ: Hyper laxite cutance at articulaire (syndrome de Danlos) existant chez trois membres d'une meme famille. *Bull Soc Fr Dermatol Syphiligr* 40:277, 1933
- 16 Wallach EA, Burkhart EF: Ehlers-Danlos syndrome associated with the tetralogy of Fallot. *Arch Dermatol* 61:750, 1950
- 17 McFarland W, Fuller DE: Mortality in Ehlers-Danlos syndrome due to spontaneous rupture of large arteries. *New Engl J Med* 171:1309, 1964
- 18 Bopp P, Hatam K, Bussat P: Cardiovascular aspects of the Ehlers-Danlos syndrome. *Circulation* 32:602, 1965
- 19 Rubinstein MK, Cohen NH: Ehlers-Danlos syndrome associated with multiple intracranial aneurysms. *Neurology (Minneapolis)* 14:125, 1964

Lunar Rhythms in the Propagation of Fish

The behavior of the fish, called grunion, offers a precise example of lunar periodicity. Exactly at the turning of the tide on the second, third and fourth nights of the highest night tides, pairs of these fish swim up the beach with the breaking waves. The female digs into the sand and deposits eggs about three inches below the surface. The male fertilizes the eggs, and on the next wave, the pair slips back into the sea. The eggs remain in

the sand until the next unusually high tides, about ten days later, at which time they are washed out of the sand. The eggs hatch as soon as they are immersed, and the tiny fish swim away.

Otto, J H and Towle, A: *Modern Biology*
New York, Holt, Rinehart & Winston,
1965

Ehlers-Danlos Syndrome and Cardiovascular Abnormalities

Jayant Antani and H. V. Srinivas

Chest 1973;63; 214-217

This information is current as of April 16, 2012

Updated Information & Services

Updated Information and services can be found at:

<http://chestjournal.chestpubs.org/content/63/2/214>

Cited By

This article has been cited by 4 HighWire-hosted articles:

<http://chestjournal.chestpubs.org/content/63/2/214#related-urls>

Permissions & Licensing

Information about reproducing this article in parts (figures, tables) or in its entirety can be found online at:

<http://www.chestpubs.org/site/misc/reprints.xhtml>

Reprints

Information about ordering reprints can be found online:

<http://www.chestpubs.org/site/misc/reprints.xhtml>

Citation Alerts

Receive free e-mail alerts when new articles cite this article. To sign up, select the "Services" link to the right of the online article.

Images in PowerPoint format

Figures that appear in *CHEST* articles can be downloaded for teaching purposes in PowerPoint slide format. See any online figure for directions.

A M E R I C A N C O L L E G E O F



P H Y S I C I A N S[®]