

Chronic Inflammatory Demyelinating Polyneuropathy

A 40-year-old female with no past medical history presents to the emergency department with worsening shortness of breath over the past 2 months. She states that she has been becoming increasingly weak, particularly when she initiates rising from a chair. She also admits to new-onset paresthesia in her bilateral lower extremities for the past month that has also worsened. She denies any preceding illness prior to symptom onset and has no known history of autoimmune disorders. She is afebrile. Vital signs, including blood pressure and heart rate, are within normal limits. On physical exam, she is alert and oriented but appears fatigued. There is evidence of increased work of breathing, but her lungs are clear to auscultation bilaterally with an oxygen saturation of 96%. Neurologically, she exhibits areflexia and 3/5 strength of bilateral lower extremities. She admits to numbness in her feet bilaterally which have altered her gait. Cranial nerve testing reveals no abnormalities. CT scan of the brain is shown in Figure 1. In addition to respiratory stabilization and ordering further brain imaging, which of the following is the most appropriate initial treatment?

- A. IVIG**
- B. Corticosteroids**
- C. Continuous nebulized albuterol**
- D. Thyroid ultrasonography**
- E. Supportive care only**

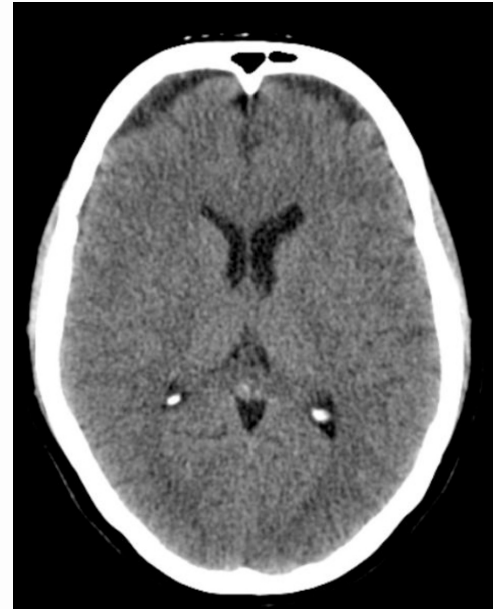


Figure 1. Example of a similar CT scan of our patient.²

Discussion

The correct answer is B. Though the definitive diagnosis is not fully ascertained by this point, an inflammatory or autoimmune demyelinating disease should be strongly considered as the underlying cause of the patient's exam and normal preliminary imaging findings. The onset and duration of these symptoms without a preceding illness makes chronic inflammatory demyelinating polyneuropathy a likely diagnosis. Multiple sclerosis should also be considered through MRI evaluation. As such, corticosteroids should be initiated, but IVIG should be considered if symptoms persist.

Chronic inflammatory demyelinating polyneuropathy (CIDP) is a rare neurological disorder affecting the myelin sheaths of both nerve roots and peripheral nerves throughout the body.¹ Myelin is a fatty material that surrounds nerve fibers in both the peripheral and central nervous system that enhances conduction between nerves. When myelin is broken down, nerve signals travel more slowly and can cause a constellation of signs and symptoms.

Symptoms of CIDP are typically non-specific neurological complaints, including proximal muscle weakness, hyporeflexia/areflexia, and sensory disturbances.³ Patients are typically diagnosed with another demyelinating disorder initially through clinical history and electromyographic findings of peripheral demyelination.⁴ CIDP is suspected when these motor/sensory symptoms persist or progress over the course of months.

Diagnosis of CIDP is largely based on history as diagnostic studies are generally non-specific. EMG studies will typically show segmental demyelination, which can be seen in a variety of peripheral neuropathies demonstrated in Figure 2. Nerve ultrasound studies may show in increased cross-section area in affected nerve groups. MRI studies may also demonstrate this nerve enlargement³ demonstrated in Figure 3.

CIDP is closely related to Guillain-Barre Syndrome (GBS), another neurological disorder that afflicts the body by a similar mechanism. Unlike CIDP, GBS is usually preceded by an infectious illness and typically resolves on its own over the course of months. CIDP typically exhibits a relapsing-remitting course that does not resolve unless treatment is initiated.³ Other forms include progressive, which worsens over time without remitting periods, and monophasic, which are single, 1-3 year long episodes that do not recur once the illness resolves.³

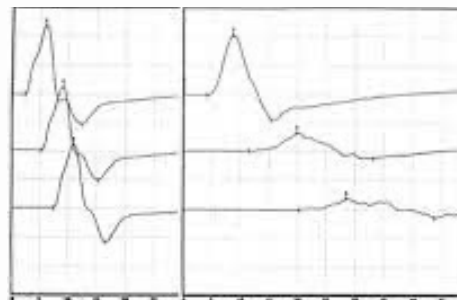


Figure 2.¹ Normal EMG findings (left) and segmental demyelinating disease findings (right) are shown in the image above. Note that the right shows decreased conduction velocities as the nerve is stimulated proximally to distally.

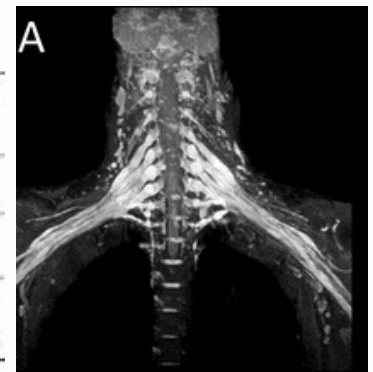


Figure 3.³ The above image is of an MRI in a patient with CIDP which affected their brachial plexuses bilaterally, demonstrating nerve enlargement.

Treatment

CIDP is generally treatment responsive, though there have been cases reported that are treatment-resistant, leading to ventilator dependence.

Treatment for CIDP revolves around the use of corticosteroids, IVIG, and plasma exchange. Corticosteroids help blunt the inflammatory effects of CIDP on peripheral nerves. For the majority of patients suffering from CIDP, corticosteroids are the mainstay of treatment for relapsing-remitting disease². IVIG has also been shown to be most effective at 1.0g/kg intravenously every 3 weeks to control symptoms. As a third-line therapy, plasma exchange has also been shown to be incredibly effective in controlling relapsing symptoms².

Each treatment regimen should be tailored to the patient's individual needs. Monotherapy or combination therapy could be appropriate depending on the patient's clinical presentation. Most patients improve after initiation of the therapies described above. The clinical progression of signs and symptoms should be tracked carefully and thoroughly as treatment is administered.

Take Home Points

- **CIDP should be suspected in patients with signs of a demyelinating disorder with a chronic, insidious onset.**
- **Diagnosis of CIDP should not rely on diagnostic studies alone; a thorough history and physical exam should raise your clinical suspicion.**
- **When an autoimmune or inflammatory polyneuropathy is suspected, there should be a low threshold for the initiation of corticosteroids or IVIg therapy.**
- **Trending clinical improvement is key as not every patient will respond to treatment equally.**




About the Author

Taylor Butts is a fourth-year medical student at Nova Southeastern University's Dr. Kiran C. Patel College of Osteopathic Medicine – Tampa Bay Regional Campus. He will be pursuing a career in the field of Neurology after graduation.

References

1. Bromberg, M. B. (2013). An electrodiagnostic approach to the evaluation of peripheral neuropathies. *Physical Medicine and Rehabilitation Clinics of North America*, 24(1), 153–168. <https://doi.org/10.1016/j.pmr.2012.08.020>
2. Cuete, D. (2022, January 1). Normal CT brain: Radiology case. *Radiopaedia Blog RSS*. Retrieved September 11, 2022, from <https://radiopaedia.org/cases/normal-ct-brain?lang=us>
3. Lehmann, H. C., Burke, D., & Kuwabara, S. (2019). Chronic inflammatory demyelinating polyneuropathy: Update on diagnosis, immunopathogenesis and treatment. *Journal of Neurology, Neurosurgery & Psychiatry*, 90(9), 981–987. <https://doi.org/10.1136/jnnp-2019-320314>
4. Lewis, R. A. (2021, January 4). Chronic inflammatory demyelinating polyneuropathy. *NORD (National Organization for Rare Disorders)*. Retrieved September 6, 2022, from <https://rarediseases.org/rare-diseases/chronic-inflammatory-demyelinating-polyneuropathy/>



 @browardem