

Gastrointestinal Surgery and Related Complications in Patients with Ehlers-Danlos Syndrome: A Systematic Review

Jakob Burcharth Jacob Rosenberg

Department of Surgery, Herlev Hospital, Herlev, Denmark

Key Words

Ehlers-Danlos syndrome · Complications · Vascular disorders · Abdominal wall hernias · Adhesions

Abstract

Introduction: Ehlers-Danlos syndrome (EDS) is a rare inherited group of connective tissue diseases characterized by joint hypermobility, skin hyperextensibility and bruising tendency. Common features of patients with EDS include vascular and gastrointestinal perforations. The purpose of this systematic review is to address gastrointestinal diseases and the complications associated with surgical treatment of diseases relating to the gastrointestinal system in patients with EDS. **Methods:** PubMed search including the Medical Subject Heading (MeSH) terms 'Ehlers-Danlos Syndrome' and 'Gastrointestinal Diseases', and an Embase search including the Map Term to Subject Heading 'Ehlers-Danlos Syndrome' with 'AND' function of the keyword 'Gastrointestinal'. **Results:** The literature search resulted in inclusion of 53 articles after application of eligibility criteria. The primary results drawn from the literature was that spontaneous ruptures of vessels and spontaneous perforations of the sigmoid colon occur in patients with EDS. **Conclusion:** Surgery in patients with EDS is associated with a high risk of complications, which is why preoperative indications should be

considered. Optimal therapy for these patients includes the awareness that EDS is a systemic disease involving fragility, bleeding and spontaneous perforations from almost all organ systems. Often, a nonsurgical approach can be the best choice for these patients, depending on the condition.

Copyright © 2012 S. Karger AG, Basel

Introduction

Ehlers-Danlos syndrome (EDS) is a heterogeneous group of hereditary connective tissue diseases characterized by abnormalities in the joints, skin and connective tissue. EDS is named after the Danish and French dermatologists Edvard Ehlers [1] and Henri-Alexandre Danlos [2] who in 1901 and 1908, respectively, independently described the relationship between joint hypermobility, recurrent subcutaneous hematoma and fragile skin. EDS is classified into six subtypes [3] (table 1) and the occurrence of all EDS subtypes combined is estimated to be 1:5,000 live births [4]. Despite the fact that EDS is inherited, there is knowledge of a large number of sporadic cases of spontaneous mutations without familial context [5]. The specific symptoms of EDS depend on the specific subtype, but varying degrees of fragility and hyperextensibility of skin, joint hypermobility and subcutaneous bleeding is

Table 1. Clinical description and subtype classification of Ehlers-Danlos syndrome

Clinical EDS subtype	Cardinal symptoms	Gastrointestinal diseases and complications	Inheritance	Genetic mutation (genetic name)	Percentage of total amount of EDS patients
Classical type	Skin hyperextensibility Atrophic scarring Joint hypermobility and dislocations Easy bruising	Recurrent hernias (inguinal, umbilical, incisional, hiatal) Rectal prolapse Spontaneous rupture of large vessels and bowel	AD	COL5A1 and COL5A2 (50%) Unknown (50%)	Approx. 80%
Hypermobility type	Joint hypermobility, dislocations and pain Skin hyperextensibility	Recurrent hernias (inguinal, umbilical, incisional, hiatal) Dysfunctional bowel motility	AD	Largely unknown COL5A1	Approx. 10%
Vascular type	Severe bleeding tendency Thin skin Spontaneous pneumothorax Recurrent joint dislocations	High frequency of surgical complications Spontaneous rupture of vessels, bowel, uterus, spleen Venous varices Recurrent hernias (inguinal, umbilical, incisional, hiatal) Colonic diverticulosis	AD	COL3A1 Many sporadic cases without familial correlation	Approx. 5%
Kyphoscoliotic type	Kyphoscoliosis Muscular hypotonia at birth Joint hypermobility Easy bruising Spontaneous rupture of bulbus oculi	Spontaneous rupture of large vessels	AR	PLOD	Very rare
Arthrochalasia type	Joint hypermobility and dislocations Skin hyperextensibility		AD	COL1A1 COL1A2	Very rare
Dermatosparaxis type	Severe skin fragility Sagging skin Easy bruising	Bladder rupture Diaphragm rupture Recurrent hernias (inguinal, umbilical, incisional)	AR	ADAMTS-2	Very rare

Adapted from [3, 8, 18, 59]. AD = Autosomal dominant; AR = autosomal recessive.

common, and in some subtypes spontaneous rupture of vessels and organs may occur [4]. A large number of patients with EDS have diseases in the gastrointestinal system which causes increased morbidity and mortality.

Collagen is the major constituent of connective tissue and plays a central pathogenic role in EDS. All EDS subtypes are due to mutations that cause either defective collagen or defective enzyme modulation of collagen fibers, resulting in the connective tissue losing its structural integrity [6]. The function of collagen is, for example, to form structural integrity of supportive structures such as bones, skin, ligaments, blood vessels and internal organs. Twenty-eight types of collagen have been discovered and the most frequent are: type I, which is found in many different tissues; type II and XI, which are primarily found

in cartilage; type III, which is found in skin, blood vessels, internal organs and uterus; and type V, which is produced together with collagen type I [7]. EDS is primarily caused by defective collagen type III and V, which results in affected soft connective tissues like skin, tendons, blood vessels and internal organs [8]. The amount of produced defective collagen type III seems to be inversely proportional to the risk of spontaneous rupture of blood vessels and internal organs [9].

EDS is characterized by symptomatic and genetic diversity, and classification and diagnosis of EDS is difficult. Diagnosis is based on clinical symptoms, laboratory studies using qualitative and quantitative testing of collagen subtypes, genetic mutation analysis, and possible detection of a positive family history [3]. The most common

subtypes are the classic type, the hypermobile type and the vascular type. The vascular type of EDS is also named the malignant type, and is the most severe subtype, with an overall mortality of 90% before the age of 50 because of spontaneous rupture of vessels and internal organs [10]. The vascular type of EDS constitutes approximately 5% of all EDS cases, but this is probably underestimated since only 16% of patients with vascular EDS have symptoms that could indicate EDS before the occurrence of a serious complication [9], and if serious complications occur, it is possible that the complication is not seen in the context of a systemic connective tissue disease [6]. This results in a late or alternatively postmortem diagnosis of EDS [11].

The purpose of this review is to present the most common gastrointestinal diseases and complications in patients with EDS and to describe the investigation and surgical treatment methods recommended for this heterogeneous and complex group of patients.

Methods

The main focus of this article is to describe the gastrointestinal diseases and the complications associated with surgical treatment of diseases relating to the gastrointestinal tract in patients with EDS.

A comprehensive literature search was performed in the Embase (January 1980 – September 2011) and PubMed (January 1966 – September 2011) databases using broad search terms relating to the design of the articles to maximize the possibility of identification of all relevant articles. The PubMed search included the Medical Subject Heading (MeSH) term 'Ehlers-Danlos Syndrome' and the MeSH term 'Gastrointestinal Diseases'. The Embase search included the Map Term to Subject Heading 'Ehlers-Danlos Syndrome' with 'AND' function of the keyword 'Gastrointestinal'.

Once identification of the possible relevant articles from the database search was performed, two reviewers screened the titles and abstracts of the articles. Only published articles were considered. Abstracts relating to presentations that had not been published as a full article in a peer-reviewed journal were not considered. Nor were personal communication or letters to the editor considered. Only articles published in English, Danish, Swedish or Norwegian were considered for this review article. This review focused on human studies or descriptions of patients with EDS, and therefore EDS was the only accepted connective tissue disorder. The eligibility criteria were all articles which included a case, group, cohort or a detailed description of gastrointestinal disease or a complication associated with surgical treatment of a gastrointestinal disease in patients with EDS. Articles in which the main focus was on other medical specialties and only briefly mentioned gastrointestinal problems in patients with EDS were not considered.

A total of 186 possible relevant articles were found from PubMed and Embase after duplicates were removed (fig. 1). The screening of abstracts excluded 55 articles because of language or non-human studies. A total of 131 full-text manuscripts were read and assessed for eligibility. Of those, 84 articles were excluded because the main

focus was something other than our eligibility criteria. By manually cross-checking reference lists, an additional 6 manuscripts were included. A total of 53 manuscripts were included in this review. Due to the rareness of EDS, this review is primarily based on smaller clinical trials and case reports since no randomized controlled trials regarding surgical intervention and EDS exists.

Results

Esophagus

Both large esophageal diverticula, megaesophagus and more commonly occurring defects such as hiatus hernia have been reported in patients with EDS [12, 13]. Spontaneous perforation has been described several times in connection with vomiting [14, 15]. No large clinical studies exist on this subject, and data regarding esophageal diseases in patients with EDS were based on only 4 case reports.

Stomach

The data on gastric symptoms in patients with EDS were derived from a single large clinical study including 100 patients [16] and case report data [17–21]. Gastric symptoms in patients with EDS extend from ordinary epigastric discomfort to severe bleeding, and in very rare cases, perforation of the stomach primarily in relation to trauma [17]. Peptic ulcers occur in patients with EDS [16], and complications of peptic ulceration have been described in patients with vascular-type EDS [18]. It has previously been postulated that the lack of perivascular structural integrity may predispose to increased bleeding from the gastric mucosa in patients with EDS [19].

Gastric diverticula are rare but have been reported frequently in patients with EDS [20, 16]. Other commonly occurring diseases of the stomach in patients with EDS are delayed gastric emptying and gastric atony [17, 21].

Small Intestine

In the transition from the stomach to the small intestine, the lack of structural integrity manifests in spontaneous perforations of the small bowel. These perforations occur in relation to small bowel diverticula [20], but perforations are also seen in the small bowel without presence of diverticula [22]. Spontaneous intramural hematoma of the small bowel wall in patients with EDS is seen and causes increased risk of focal necrosis of the intestinal wall which has been described to lead to perforation [19]. Other reported conditions from the small bowel are malabsorption due to altered gut motility [23], spontaneous cases of megaduodenum with bacterial overgrowth

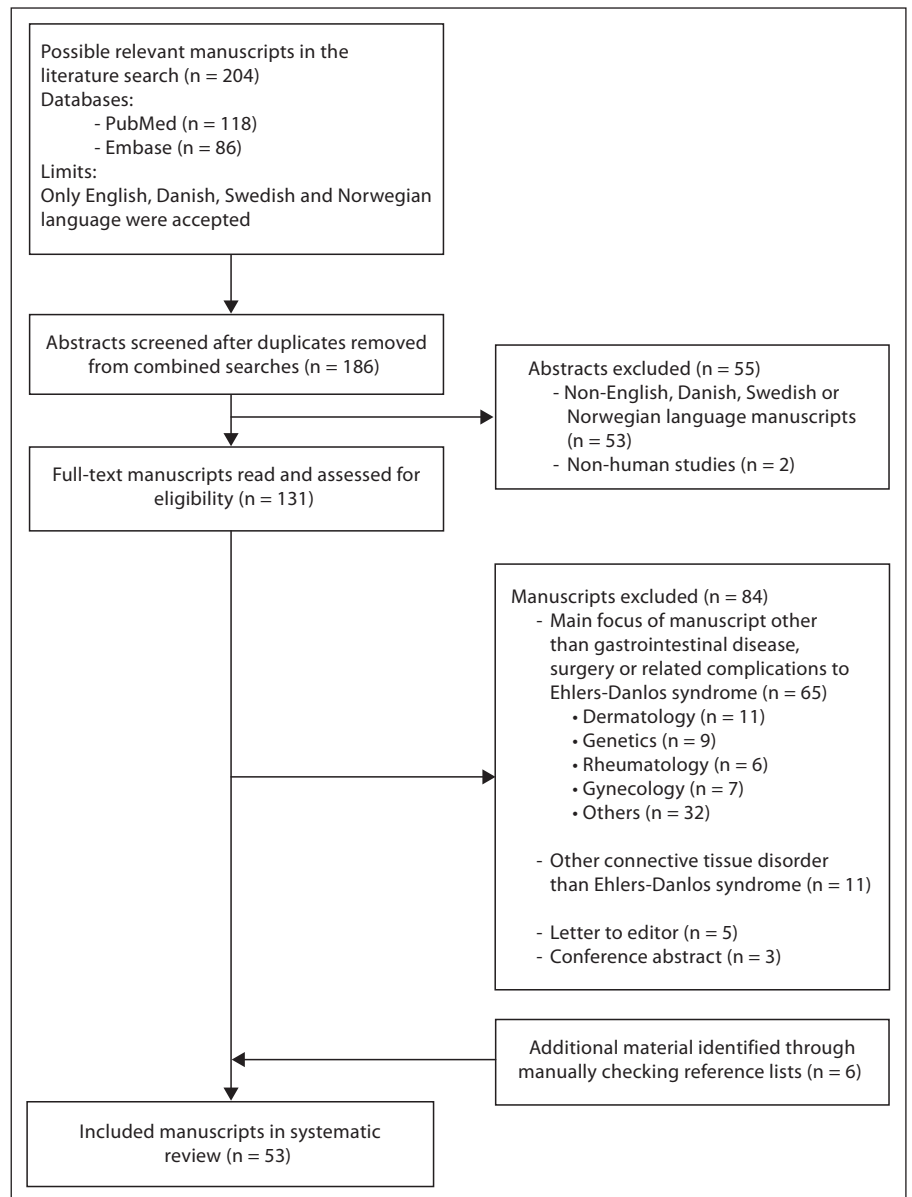


Fig. 1. Flow diagram of study selection.

[24] and spontaneous dilatation of the small intestine from the Treitz ligament to the terminal ileum [25]. The data regarding small intestine diseases in patients with EDS are merely based on case reports and no large-scaled data are available to support these clinical findings.

Liver, Spleen and Pancreas

Compared to the intestine, there are fewer complications reported from the liver, spleen or pancreas in patients with EDS. However, there are few documented case reports of spontaneous liver rupture [26], splenic

rupture [27] and gallbladder rupture [16], probably due to a reduced amount of structurally intact supportive tissue in these organs. Pancreatitis in patients with EDS has been described [28] and the cause is thought to be microvascular damage to the capillaries in the pancreas.

Colon

The colonic wall contains high amounts of collagen, and the most frequent anatomical location of colon perforation in patients with EDS has been reported to be in the sigmoid colon numerous times [10, 29–31]. Perfora-

tions are either spontaneous or iatrogenic (i.e. related to examination and treatment). Spontaneous colon perforation has been reported in patients with EDS from age 5 to old age, but it is most often seen among young people and most frequently among patients with the vascular type of EDS [32]. Iatrogenic colon perforation is seen in relation to sigmoidoscopy, colonoscopy and the treatment of chronic constipation [33, 34]. Data on colonic perforation are based on both case reports and the largest and most thorough clinical study to date on patients with EDS including 419 patients [10].

Patients with EDS, especially children and teenagers, are reported to suffer from chronic constipation, which is most likely due to decreased intestinal motility [34]. A case report has reported constipation as a cause of spontaneous colon perforation, probably due to a fragile colonic wall [35], which is why the authors recommend that enemas not be used as a treatment for constipation in patients with EDS, as the risk of traumatic perforation is increased [35]. Other case reports have reported increased risk of diverticulitis, enterocutaneous fistulae and intramural colonic hematomas [36].

Rectum

Data regarding rectal diseases in patients with EDS are based on a single clinical study [16] and on case report data [37, 38]. Patients with EDS have been reported to suffer from rectal prolapse from early childhood to the sixth decade [37, 16]. Surgical treatment of rectal prolapse has been reported to be associated with risk of complications, which is why some authors recommend careful consideration in planning the surgical treatment [38, 18]. Because of the risk of chronic constipation [35], it is suggested that patients with EDS maintain a regular laxative regime in order to try to avoid rectal prolapse [18].

Hernia

Data on occurrence of hernia among patients with EDS rely primarily on a single clinical study of 130 patients [39] as well as case reports [36, 40–42]. In all age groups, patients with EDS have an overall increased relative risk of 2.5 for development of inguinal hernias compared with the general population [39]. The highest risk was found among males aged 0–19 with a relative risk of 10.3 compared to the general population [39]. Patients with EDS may also be prone to ventral herniation [40]. A single case documented a large intercostal hernia after coughing [41], a hernia type which is not seen in other patients. In particular, patients with vascular-type EDS have poor wound healing, which causes a high frequency

of incisional hernias after abdominal incisions [36]. When operating inguinal and ventral hernias in patients with EDS, a mesh should always be considered in order to reduce risk of recurrence [40, 42].

Vascular

Data on rupture of vessels in the thorax and abdomen in patients with EDS are based on one large clinical study including 419 patients [10] and several case reports [43–46]. In the large clinical study, 217 arterial complications in 419 patients were reported [10]. About 50% of the vascular ruptures occurred in medium-to-large-sized arteries in the thorax and abdomen [10], but rupture of the aorta has also been reported [43, 44]. Vascular ruptures into the thorax or abdomen is life-threatening and requires immediate surgical intervention, whereas ruptures of vessels in closed cavities can be self-limiting by tamponade from the cavity itself, and surgical intervention may be harmful because of the patients' high risk for complications [45]. Vascular rupture has been reported as a more frequent cause of death (75%) than gastrointestinal rupture (8%) among vascular-type EDS patients [10]. Patients with EDS have been reported to suffer from varicose veins, but because of a high risk of intraoperative bleeding and complications, surgery for varicose veins can be risky [46].

Discussion

The basic findings of this systematic review are that gastrointestinal diseases in patients with EDS have been reported from all parts of the gastrointestinal tract, but with different frequency and severity. Of the six types of EDS according to the Villefranche nosology [3], patients with the vascular form of EDS seem to be at the highest risk for developing gastrointestinal diseases and complications. Of all complications, spontaneous rupture of the aorta and medium-to-large-size vessels are the most frequent, where spontaneous and iatrogenic rupture of colon sigmoideum are the most common gastrointestinal complications reported.

Invasive surgical procedures are generally not recommended for patients with EDS, apart from acute irreversible situations, since the tissues of patients with EDS are described as being very vulnerable with 'wet tissue' texture and poor ability to hold sutures [47]. Furthermore, several cases of problematic intraoperative bleeding and massive amounts of intraperitoneal adhesions have been reported [18]. Especially patients with vascular-type EDS are at a high risk of bleeding, and unless the procedure is

considered absolutely life-saving, several authors have concluded that surgery should be avoided whenever possible in this group of patients [18, 29, 48, 49]. If a procedure can be performed under local anesthesia instead of general anesthesia, this can be considered due to reported risk of lesions of the skin, cavum oris, pharynx, larynx, and risk of cervical atlantoaxial subluxation due to laxity of the cervical ligaments and increased risk of temporomandibular dislocation in connection with endotracheal intubation [50, 51]. However, local anesthesia has been reported to have a reduced effect on patients with EDS, and therefore it is recommended to combine several different types of local anesthesia in order to achieve sufficient effect [52, 53]. Spinal and epidural anesthesia are possible alternatives to general anesthesia, with the reservation that kyphoscoliosis and needle displacement are seen more frequently in patients with EDS, as increased elasticity of the ligaments around the spine can make it harder for the anesthesiologist to feel the needle advancement [50]. Another alternative to the above-mentioned methods is peripheral nerve blockade that can be used if the surgical procedure is on the extremities [54].

Considerations during the surgical procedure are general caution, minimal surgical dissection and use of minimal lateral force during incisions, retraction and suturing [42]. Arteries and intestinal walls are very sensitive to mechanical handling, and it can be difficult to achieve surgical hemostasis [29]. Clamping of bleeding vessels should be avoided due to risk of tearing, but if clamping is necessary the hemostats should be held lightly because once torn, the ends of arteries and veins will retract, and hemostasis will be very difficult [42]. The fragility of the skin in patients with EDS manifests itself in problems with skin closure. One of the most frequent problems is wound rupture even several weeks after surgical procedures. Therefore, special precautions during skin closure should be taken (table 2). When performing surgery in general anesthesia, it is important to pay particular attention to the positioning of the patient in order to avoid joint dislocations and damage to the skin [50]. Treatment of patients with EDS should in general consist of a minimum of invasive procedures, such as needle punctures, intramuscular injections and catheterizations, due to increased risk of bleeding and complications [42]. Postoperatively, patients with vascular-type EDS should be closely observed since a risk of developing postoperative arterial rupture due to generally increased collagenase activity as a result of the surgical trauma has been reported [17, 30].

Epigastric symptoms in patients with EDS may advantageously be treated conservatively, but in cases of bleed-

Table 2. Precautions at skin closure after surgical incisions in patients with EDS

-
- Skin closure should be performed:
- In two layers (subcutaneously and cutaneously) without tension
 - With sufficient amount of sutures
 - With deep stitches
 - Using proper distance to the incision in order to avoid sutures cutting through the fragile tissue
 - Without the use of skin clips
 - With the use of steri strips to support the sutures
 - Sutures should be left twice as long as normally recommended in order to avoid wound rupture
-

Adapted from [8, 59]. Wound rupture is often seen in patients with EDS 1–2 weeks after the surgical procedure.

ing, strangulation or perforation, acute surgery is indicated [55]. Reflux symptoms should be investigated, as this has been reported in the vascular type of EDS in particular, probably due to weakness in the lower esophageal sphincter. Mucosa in these patients is vulnerable and fragile, and bleeds easily [56]. Some recommend noninvasive diagnostics and therapy with antacids and proton pump inhibitors in case of epigastric discomfort, and then investigation by gastroscopy if there is a lack of improvement [18]. In the literature, gastroscopy has not demonstrably been associated with an increased complication rate in patients with EDS [33]; however, some authors still advocate against the use of gastroscopy as a primary diagnostic modality [18]. The presence of a gastric diverticulum is rare and could make the doctor aware that it may be a patient with EDS. In case of bleeding from the gastrointestinal tract in a patient with EDS, it is important to pay extra attention to future possible perforations since there is a risk of intramural hematoma formation, which could weaken the tissue and potentially lead to perforation [18].

There are no randomized studies on treatment of colon perforation in patients with EDS, but data from non-randomized studies suggest that some surgical treatments should be avoided, especially in patients with vascular-type EDS. Segmental colon resection with either one-stage primary anastomosis or Hartmann's resection with a temporary colostomy and closure of the rectum and later secondary reanastomosis of the colon should not be used in patients with vascular-type EDS due to the risk of anastomotic leaks and up to 55% reperforations of the colon [10, 29, 48, 57]. Since mortality rates of up to 66% have been reported in cases of anastomotic leak [48], segmental colon resection with permanent colostomy

may be performed instead. This reduces the risk of subsequent perforation compared with a primary colon anastomosis, but does not eliminate the risk completely since recurrent spontaneous colon perforations and stenosis of the proximal colon have been reported [31, 48]. This has led some to suggest that a subtotal colectomy with preservation of the rectum and construction of a permanent ileostomy, which virtually eliminates the risk of further perforation of intestine, is the correct treatment option [29, 31, 48]. In younger patients who do not accept or tolerate a permanent ileostomy, or if other factors make this surgical procedure technically impossible, another option is to make a two-stage operation in which the colon is initially resected with construction of a temporary ileostomy and closure of the rectum, and subsequent creation of an ileorectal anastomosis [5, 31, 57]. In cases of small bowel perforation, surgery is mandatory and can be performed by local resection and end-to-end anastomosis without increased risk of anastomotic leaks compared to the general population [33].

Iatrogenic colonic perforation when performing sigmoidoscopy or colonoscopy has been reported in patients with EDS, and some authors advocate that these procedures should be reserved for patients with a high potential therapeutic benefit and not as diagnostic modalities [18, 33, 34]. Patients with EDS are recommended to keep their stools soft and avoid constipation by sufficient fiber intake and oral laxatives [26]. In cases of spontaneous colon perforation in a patient where no obvious cause is found during the operation, such as diverticulitis, neoplasia, inflammatory bowel disease or prolonged use of steroids, one should consider EDS as a differential diagnosis [49].

General vascular fragility, particularly among patients with vascular-type EDS with spontaneous rupture of arteries and veins, is dominant in the third and fourth decade, and can present as acute abdominal pain, hematemesis, hemoptysis, hematuria, muscle swelling and shock [8]. In the case of acute abdominal pain in a patient with EDS, complications from the vascular system should therefore always be considered as a differential diagnosis. When suspecting vascular diseases, it is recommended to use noninvasive diagnostic modalities such as ultrasound, CT or MRI since angiography has been reported to be associated with a 17–67% complication risk and a 6–19% mortality rate in patients with EDS [9, 48, 58]. So far, nothing can be done to prevent spontaneous vascular rupture. Screening programs will probably not provide full benefit, as the majority of vascular ruptures occur independently of aneurysms and thus will not be found in a screening program.

The limitations of almost all results presented in this review are that they are based on nonrandomized studies and case reports. Due to the rarity of EDS, and the fact that EDS often is diagnosed in association with acute disease [48], it is very difficult to plan and conduct randomized controlled studies.

Conclusion

Optimal therapy for this group of patients starts with the awareness that EDS is a systemic disease involving tissue fragility, bleeding and spontaneous perforations from almost all organ systems. The sooner EDS is diagnosed, the sooner the surgeon and patient together can make informed choices about the diagnosis and treatment strategy. Despite the fact that these patients should be followed and treated at selected centers, it will often be surgeons at local hospitals who initially see and treat these patients when they are admitted with complications before diagnosis. If a surgeon is presented with a patient suffering from EDS, it is important to seek expert help so that the maximum number of precautions can be taken.

Fact Box

Precautions When Planning and Performing Surgery in a Patient with EDS

- Gastrointestinal surgery in patients with EDS may be problematized by intraoperative bleeding and massive amounts of intraperitoneal adhesions.
- Invasive surgical procedures should be reserved for acute irreversible situations for patients with EDS. Patients with vascular-type EDS are at the highest risk for complications.
- Local anesthesia or peripheral nerve blocks could be used instead of general anesthesia if the surgical procedure allows it.
- Minimal surgical dissection and limited use of lateral force during incisions, retraction and suturing are advisable.
- Diagnostic colonoscopy should not be performed in patients with EDS. The sigmoid colon is the most frequent location of spontaneous perforation. In case of a colonic perforation:
 - primary or secondary colonic anastomosis is at risk of perforating;
 - either a colostomy, a terminal ileostomy or a ileorectal anastomosis can be performed instead.
- Hernia recurrences occur in patients with EDS and mesh should be used to reduce risk of recurrence.
- In vascular diagnosing the noninvasive diagnostic modalities such as ultrasound, CT or MRI should be preferred over intravascular angiography due to the risk of complications.

References

- 1 Ehlers E: Cutis laxa, neigung zu haemorrhagien in der haut, lockerung mehrerer artikulatio-nen. *Derm Zschr* 1901;18:173–175.
- 2 Danlos M: Un cas de cutis laxa avec tumeurs par contusion chronique des coudes et des genoux (xanthome juvénile pseudo-diabé-tique de MM Hallepeau et Marc de Lépinay). *Bull Soc Franc Derm Syph* 1908;19:70–72.
- 3 Beighton P, De Paepe A, Steinmann B, et al: Ehlers-Danlos syndromes: revised nosology, Villefranche, 1997. Ehlers-Danlos National Foundation (USA) and Ehlers-Danlos Sup-port Group (UK). *Am J Med Genet* 1998;77: 31–37.
- 4 Pyeritz RE: Ehlers-Danlos syndrome. *N Engl J Med* 2000;342:730–732.
- 5 Demirogullari B, Karabulut R, Demirtola A, et al: A novel mutation in the vascular Ehlers-Danlos syndrome: a case presenting with colonic perforations. *J Pediatr Surg* 2006; 41:e27–e30.
- 6 Bläker H, Funke B, Hausser I, et al: Pathol-ogy of the large intestine in patients with vascular type Ehlers-Danlos syndrome. *Virchows Arch* 2007;450:713–717.
- 7 Birk DE: Type V collagen: heterotypic type I/V collagen interactions in the regulation of fibril assembly. *Micron* 2001;32:223–237.
- 8 De Paepe A, Malfait F: Bleeding and bruising in patients with Ehlers-Danlos syndrome and other collagen vascular disorders. *Br J Haematol* 2004;127:491–500.
- 9 Cikrit DF, Glover JR, Dalsing MC, et al: The Ehlers-Danlos specter revisited. *Vasc Endo-vascular Surg* 2002;36:213–217.
- 10 Pepin M, Schwarze U, Superti-Furga A, et al: Clinical and genetic features of Ehlers-Dan-los syndrome type IV, the vascular type. *N Engl J Med* 2000;342:673–680.
- 11 Barabas AP: Ehlers-Danlos syndrome type IV. *N Engl J Med* 2000;343:366.
- 12 Toyohara T, Kaneko T, Araki H, et al: Giant epiphrenic diverticulum in a boy with Ehlers-Danlos syndrome. *Pediatr Radiol* 1989;19: 437.
- 13 Iglesias JL, Renard T: Diaphragmatic hernia in an 8-year-old with Ehlers-Danlos syn-drome. *Pediatr Surg Int* 1998;13:553–555.
- 14 Reis ED, Martinet OD, Mosimann F: Spont-aneous rupture of the oesophagus in an ado-lescent with type IV Ehlers-Danlos syn-drome. Ehlers-Danlos and spontaneous oesophageal rupture. *Eur J Surg* 1998;164: 313–316.
- 15 Habein HC: Ehlers-Danlos syndrome with spontaneous rupture of the esophagus. Re-port of first case. *Rocky Mt Med J* 1977;2: 78–80.
- 16 Beighton P, Horan FT: Surgical aspects of the Ehlers-Danlos syndrome. A survey of 100 cases. *Br J Surg* 1969;56:255–259.
- 17 Garvin JT, Joyce M, Redahan M, et al: Surgi-cal management of Ehlers-Danlos syndrome type IV following abdominal trauma. *J Trau-ma* 2008;64:1376–1379.
- 18 Solomon JA, Abrams L, Lichtenstein GR: GI manifestations of Ehlers-Danlos syndrome. *Am J Gastroenterol* 1996;91:2282–2288.
- 19 Byard RW, Keeley FW, Smith CR: Type IV Ehlers-Danlos syndrome presenting as sud-den infant death. *Am J Clin Pathol* 1990;93: 579–582.
- 20 Aldridge RT: Ehlers-Danlos syndrome caus-ing intestinal perforation. *Br J Surg* 1967;54: 22–25.
- 21 McEntyre RL, Raffensperger JG: Surgical complications of Ehlers-Danlos syndrome in children. *J Pediatr Surg* 1977;12:531–535.
- 22 Leake TF, Singhal T, Chandra A, et al: Occult small bowel perforation in a patient with Ehlers Danlos syndrome: a case report and review of the literature. *Cases J* 2010;3:57.
- 23 Sigurdson E, Stern HS, Houpt J, el-Sharkawy TY, Huizinga JD: The Ehlers-Danlos syn-drome and colonic perforation. Report of a case and physiologic assessment of underlying motility disorder. *Dis Colon Rectum* 1985;28:962–966.
- 24 Hines C, Davis WD: Ehlers-Danlos syn-drome with megaduodenum and malab-sorption syndrome secondary to bacterial overgrowth. A report of the first case. *Am J Med* 1973;54:539–543.
- 25 Harris RD: Small bowel dilatation in Ehlers-Danlos syndrome – an unreported gastroin-testinal manifestation. *Br J Radiol* 1974;47: 623–627.
- 26 Gelbmann CM, Köllinger M, Gmeinwieser J, et al: Spontaneous rupture of liver in a pa-tient with Ehlers Danlos disease type IV. *Dig Dis Sci* 1997;42:1724–1730.
- 27 Privitera A, Milkhu C, Datta V, et al: Spont-aneous rupture of the spleen in type IV Ehlers-Danlos syndrome: report of a case. *Surg Today* 2009;39:52–54.
- 28 Sarra-Carbonell S, Jimenez SA: Ehlers-Dan-los syndrome associated with acute pancre-atitis. *J Rheumatol* 1989;16:1390–1394.
- 29 Berney T, La Scala G, Vettorel D, et al: Surgi-cal pitfalls in a patient with type IV Ehlers-Danlos syndrome and spontaneous colonic rupture. Report of a case. *Dis Colon Rectum* 1994;37:1038–1042.
- 30 Asherson RA, Bosman C, Tikly M, et al: Ehlers-Danlos syndrome type IV in a young man. *J Rheumatol* 2006;33:2091–2096.
- 31 Stillman AE, Painter R, Hollister DW: Ehlers-Danlos syndrome type IV: diagnosis and therapy of associated bowel perforation. *Am J Gastroenterol* 1991;86:360–362.
- 32 Collins MH, Schwarze U, Carpentieri DF, et al: Multiple vascular and bowel ruptures in an adolescent male with sporadic Ehlers-Danlos syndrome type IV. *Pediatr Dev Pathol* 1999;2:86–93.
- 33 Baichi MM, Arifuddin RM, Mantry PS: Gas-trointestinal bleeding in a patient with Ehlers-Danlos syndrome: an endoscopic di-lemma. *Dig Dis Sci* 2005;50:1342–1343.
- 34 Soucy P, Eidus L, Keeley F: Perforation of the colon in a 15-year-old girl with Ehlers-Dan-los syndrome type IV. *J Pediatr Surg* 1990; 25:1180–1182.
- 35 Sentongo TA, Lichtenstein G, Nathanson K, et al: Intestinal perforation in Ehlers-Danlos syndrome after enema treatment for consti-pation. *J Pediatr Gastroenterol Nutr* 1998;27: 599–602.
- 36 Sykes EM: Colon perforation in Ehlers-Danlos syndrome. Report of two cases and review of the literature. *Am J Surg* 1984;147: 410–413.
- 37 Douglas BS, Douglas HM: Rectal prolapse in the Ehlers-Danlos syndrome. *Aust Paediatr J* 1973;9:109–110.
- 38 Pope FM, Nacisi P, Nicholls AC, et al: Clinical presentations of Ehlers Danlos syndrome type IV. *Arch Dis Child* 1988;63: 1016–1025.
- 39 Liem MS, van der Graaf Y, Beemer FA, et al: Increased risk for inguinal hernia in patients with Ehlers-Danlos syndrome. *Surgery* 1997; 122:114–115.
- 40 Giroto JA, Malaisrie SC, Bulkely G, et al: Re-current ventral herniation in Ehlers-Danlos syndrome. *Plast Reconstruct Surg* 2000; 106:1520–1526.
- 41 de Weerd L, Kjæve J, Gurgia L, Weum S: A large abdominal intercostal hernia in a pa-tient with vascular type Ehlers-Danlos syn-drome: a surgical challenge. *Hernia* 2012; 16:117–120.
- 42 Deysine M: External abdominal wall herni-orrhaphy in patients with Ehlers-Danlos syndrome. Technical considerations. *Hernia* 1998;2:63–66.
- 43 Karkos CD, Prasad V, Mukhopadhyay U: Rupture of the abdominal aorta in patients with Ehlers-Danlos syndrome. *Ann Vasc Surg* 2000;14:274–277.
- 44 Hosaka A, Miyata T, Shigematsu H, et al: Spontaneous mesenteric hemorrhage associ-ated with Ehlers-Danlos syndrome. *J Gas-trointest Surg* 2006;10:583–585.
- 45 Shepherd RFJ, Rooke T: Uncommon arteriopathies: what the vascular surgeon needs to know. *Semin Vasc Surg* 2003;16: 240–251.
- 46 Brearley S, Fowler J, Hamer JD: Two vascular complications of the Ehlers-Danlos syn-drome. *Eur J Vasc Surg* 1993;7:210–213.
- 47 Bade MA, Queral LA, Mukherjee D: Endo-vascular abdominal aortic aneurysm repair in a patient with Ehlers-Danlos syndrome. *J Vasc Surg* 2007;46:360–362.
- 48 Freeman RK, Swegle J, Sise MJ: The surgical complications of Ehlers-Danlos syndrome. *Am Surg* 1996;62:869–873.
- 49 Kashtan H, Goldman G, Stadler J: Recurrent spontaneous perforation of the colon. *Dis Colon Rectum* 1986;29:586–587.
- 50 Lane D: Anaesthetic implications of vascular type Ehlers-Danlos syndrome. *Anaesth In-tensive Care* 2006;34:501–505.

- 51 Aiello G, Metcalf I: Anaesthetic implications of temporomandibular joint disease. *Can J Anaesth* 1992;39:610–616.
- 52 Kålund S, Høgså B, Grevy C: Reduced strength of skin in Ehlers Danlos syndrome, type III. *Scand J Rheumatol* 1990;19:67–70.
- 53 Arendt-Nielsen L, Kaalund S, Bjerring P: Insufficient effect of local analgesics in Ehlers Danlos type III patients (connective tissue disorder). *Acta Anaesthesiol Scand* 1990;34:358–361.
- 54 Wegener JT, Frässdorf J, Stevens MF: Effective plexus anaesthesia in a patient with Ehlers-Danlos syndrome type III. *Eur J Anaesthesiol* 2009;26:619–621.
- 55 Serry C, Agomuoh OS, Goldin MD: Review of Ehlers-Danlos syndrome. Successful repair of rupture and dissection of abdominal aorta. *J Cardiovasc Surg* 1988;29:530–534.
- 56 Bechi P, Naspetti R, Santucci M, et al: A variety of Ehlers-Danlos syndrome type IV presenting with haematemesis and gastroesophageal reflux. *Ital J Surg Sci* 1987;17:63–66.
- 57 Fuchs JR, Fishman SJ: Management of spontaneous colonic perforation in Ehlers-Danlos syndrome type IV. *J Pediatr Surg* 2004;39:e1–e3.
- 58 Habib K, Memon MA, Reid DA, et al: Spontaneous common iliac arteries rupture in Ehlers-Danlos syndrome type IV: report of two cases and review of the literature. *Ann R Coll Surg Engl* 2001;83:96–104.
- 59 Malfait F, Paeppe AD: The Ehlers-Danlos Syndrome. I: Stone JH, ed. *A Clinician's Pearls and Myths in Rheumatology – Overview of Ehlers Danlos syndrome*. London, Springer London Ltd, 2009, pp 467–475.