GASTON RADIOLOGY
Providing Professional Services for CaroMont Imaging

www.gastonradiology.com (704) 671-7730

Vertebroplasty for Treatment of Spine Fracture

By: Mark T. Edge, MD, PhD
Gaston Radiology

Pre-procedure patient consultation

Back pain is a very common ailment among people of all ages. When a physician is faced with a patient complaining of back pain, there are a great many considerations for establishing the cause of the pain. These causes might include simple muscle strain and overuse, arthritis, disc herniation and compression of the nerves exiting the spine, as well as fracture of the spine.

While fractures of the spine often involve trauma, that's not always the case. In fact, one of the most common causes of non-traumatic spine fracture is osteoporosis.

Osteoporosis as a Cause of Spine Fracture

Osteoporosis sometimes is thought of as "softening" or thinning of the bone. The bones become fragile and may break even under normal stresses. While osteoporosis may be associated with aging, it also is found in persons as young as or younger than 50. It affects more than 40 million Americans in all ethnic groups, of whom nearly 80 percent are women.

There are usually no symptoms of osteoporosis until a fracture occurs. About 300,000 hip fractures and over 700,000 spine fractures are reported each year, but many spine fractures are never diagnosed or they are identified late after the fact.

Typical osteoporotic fractures of the spine are called compression fractures. To understand this term better, picture the spine as a column of stacked cans that are separated by round discs of soft tissue, which create a joint between the cans. Compressing together the two ends of a can, or vertebral body, would result in deformity and loss in normal height. This loss in vertebral body height may range from just a few percent to a nearly complete flattening of the bone.

Many activities can lead to a compression fracture. A fall is an obvious cause. However, in osteoporotic bone, even minor activities such as a misstep, lifting, and bending may lead to a fracture. Some surprising causes leading to a fracture have been coughing and rolling over in bed.

After a fracture, the patient may experience abrupt back pain ranging in severity from merely annoying to completely debilitating. The pain may not be confined to or even be located in the back. Many patients complain of chest or abdominal pain, which may confuse or delay the diagnosis. If left untreated, some fractures will heal and the pain may improve

Vertebral Body Cement Prep

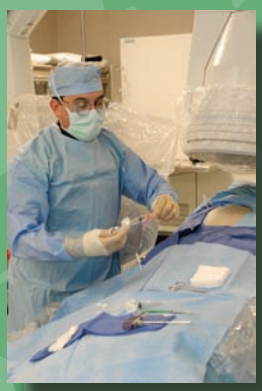

Dr. Edge Performing Routine Kyphoplasty/ Vertebroplasty

after a few weeks, while in others, the pain may not improve and it may become chronic.

Once a patient experiences a compression fracture, it's estimated their risk for additional vertebral body fractures increases as much as a five-fold. The fracture may lead to loss in stature and increased curvature of the spine—the so-called dowager's hump—as well as diminished lung capacity, increased risk of pneumonia, weight loss, lost independence, psychological deterioration and depression. For these reasons, alleviating the pain becomes very important in breaking a potentially downward spiral of worsening physical and mental health.

Initial treatment may include pain mediation and bed rest. Even in the recent past, these measures have been the mainstay in treatment of compression fractures. In 1984, a French radiologist injected bone cement into a severely weakened vertebra in a procedure he termed vertebroplasty. In 1993, the first patient in the United States underwent vertebroplasty at the University of Virginia. Success in pain relief was routinely dramatic and the procedure is now performed thousands of times each year all over the world.

Vertebroplasty Candidate Selection

The goal of the procedure is pain relief. Although most fractures may eventually heal on their own, the patient may experience prolonged pain. Debilitation secondary to pain may also lead to complications. The patient may not breathe properly, increasing the risk of pneumonia. Drugs to control pain may lead to constipation further aggravating back pain. Inability to walk properly due to pain and pain medications leads to risk of falling and additional injuries. Treatment is therefore directed toward patients with recent fractures who have failed to respond to bed rest and pain control. If a fracture is chronically painful, however, patients may still be eligible for vertebroplasty even one or two years after the fracture occurred.

Patients of any age may be considered for the procedure. Most patients are treated because of osteoporotic fractures. However, fractures may occur due to tumors of the spine or after trauma in which there is delayed healing of the bone accompanied by chronic pain.

Additional Tests

Fractures of the vertebrae may compress nerve roots or compromise the spinal canal through which the spinal cord runs. In order to determine the architecture of the fracture and assess the safety of the approach to the fracture, tests such as CAT scans may be needed to supplement the x-rays. When multiple fractures are present, an MRI or nuclear medicine study may be performed in order to determine which fracture or fractures are actively causing the back pain.

(704) 671-7730
www.gastonradiology.com

A.

B.

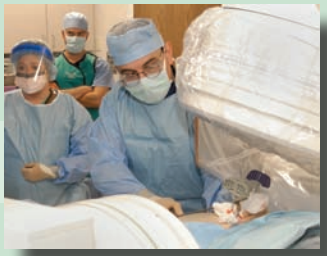

C.

Performing Routine Kyphoplasty/Vertebroplasty Procedure

Procedure

A consultation between the patient and the physician performing the vertebroplasty takes place a week or so before the actual procedure. Prior to the procedure, some medications such as blood thinners may be temporarily stopped. At the procedure, the patient lies on their stomach and the back is prepared in a sterile environment. An antibiotic and medications for sedation are administered through an intravenous line. Once the patient is comfortable, local anesthetic is applied over the broken bone and a needle is advanced into the vertebral body under x-ray guidance. Bone cement is then injected forming an internal cast of the bone, stabilizing the fractures. The needles are removed, a bandage is applied, and the patient is sent to the recovery area. After about four hours, they can be discharged to return home.

Recovery

Response times to recovery vary considerably between patients. Some patients are pain-free immediately following the procedure although most experience relief within a day or two. The patient is instructed to return to light activity as much as comfort will allow. The patient follows up with their doctor who may decide to formulate a treatment plan for osteoporosis if one has not already been established.

Possible Complications

Complications are unusual and are estimated to occur in fewer than 1% of patients. These include nerve damage possibly requiring additional treatment, cement migration away from the vertebral body fracture, infection, and failure to respond to treatment.

Case Example: Lumbar Spine Fracture

Needles are placed into the fractured part of the vertebral body under x-ray guidance. The picture on the left is a view of the spine from the side, while on the right is a view projecting through the back.

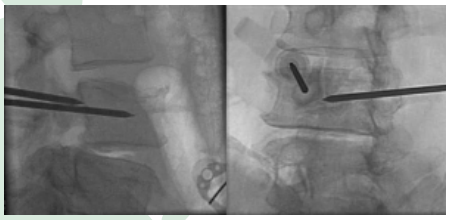

Similar views were obtained in these photographs revealing further positioning of the needles into the spine and placement of the cement (black material) into the bone.

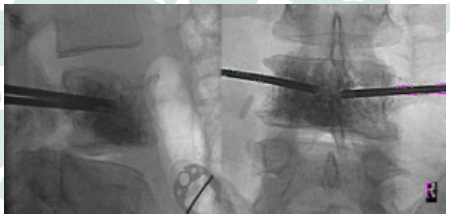

Resources

Patients with significant back pain should see their doctors immediately. Their physicians is the best source of information available for treatment options. If a fracture of the spine is present, vertebroplasty and its cousin kyphoplasty are treatments aimed at alleviating the pain associated with fractures of the spine. The procedures are quick and safe and offer profound relief of back pain in the great majority of patients.

Many websites are devoted to increasing public awareness of osteoporosis and enhancing knowledge of treatments to include vertebroplasty and similar other methods. Here are just a few:

http://www.radiologyinfo.org/en/info.cfm?pg=vertebro&bhcp=1

www.vertebroplasty.com

http://www.emedicine.com/radio/topic871.htm

http://www.nof.org/

Written by:
Mark T. Edge, MD, PhD
Neuroradiologist

Gaston Radiology
620 Summit Crossing Place
Suite 106
Gastonia, NC 28054

Dr. Mark T. Edge