

Surgical Offloading the Diabetic Foot

ACLES Annual Conference
May 4, 2017

Richard T. Bauer III DPM, AACFAS

Summit Foot and Ankle

1072 Troy-Schenectady Road, Suite 303

Latham, NY 12110

Medical Director, Seton Wound Care Center

rbauer.dpm@gmail.com



ST PETER'S HEALTH
PARTNERS

Objectives

- Understand options to consider when conservative offloading fails.
- Recognize Orthopedic Deformities which may pose a problem in the neuropathic patient.
- Evaluate Risk vs Benefit of Surgical Reconstruction in the Diabetic Patient

Principles of Standard Wound Care

- Adequately perfused
- Metabolic syndrome addressed
- Appropriately offloaded
- Infection Addressed, soft tissue and or bone
- Thorough wound preparation, debridement and removal of all necrotic and non-viable tissue

Conservative Offloading

- PTBB
- CROW
- CAM
- TCC
- Orthopedic Shoes
- Unweighted AFOs

Conservative Offloading

- Every Patient CANNOT be placed in a TCC!

Classification of Diabetic Foot Surgery

- Class I: Elective, Reconstructive procedures on Patients who do not have LOPS
- Class II: Prophylactic, Reconstructive Procedures performed to reduce the risk of ulceration or re-ulceration in patients who have LOPS but no open wound
- Class III: Curative, Procedures performed to assist in healing of an open wound
- Class IV: Emergent, Procedures performed to arrest or Limit progression of infection.

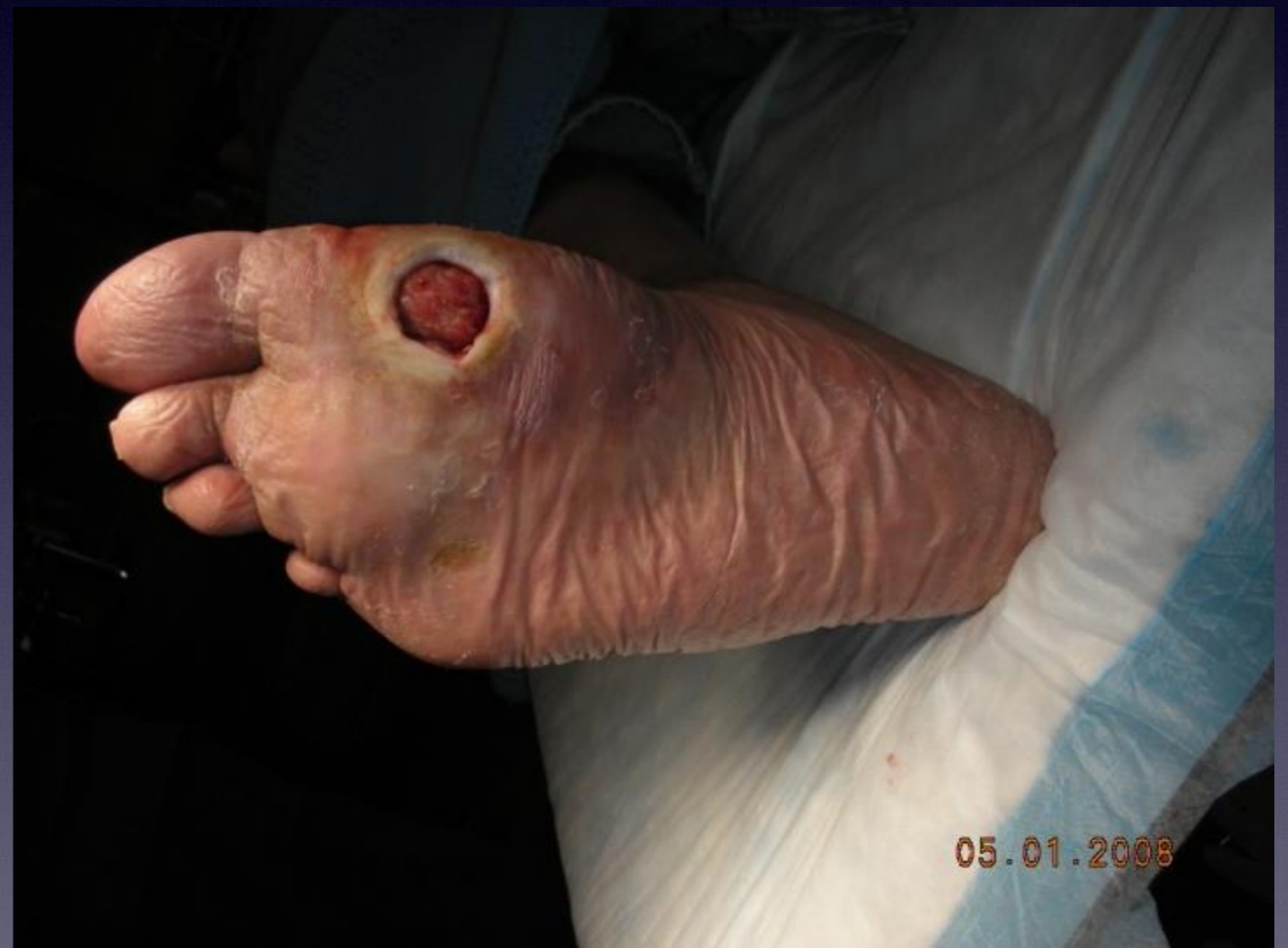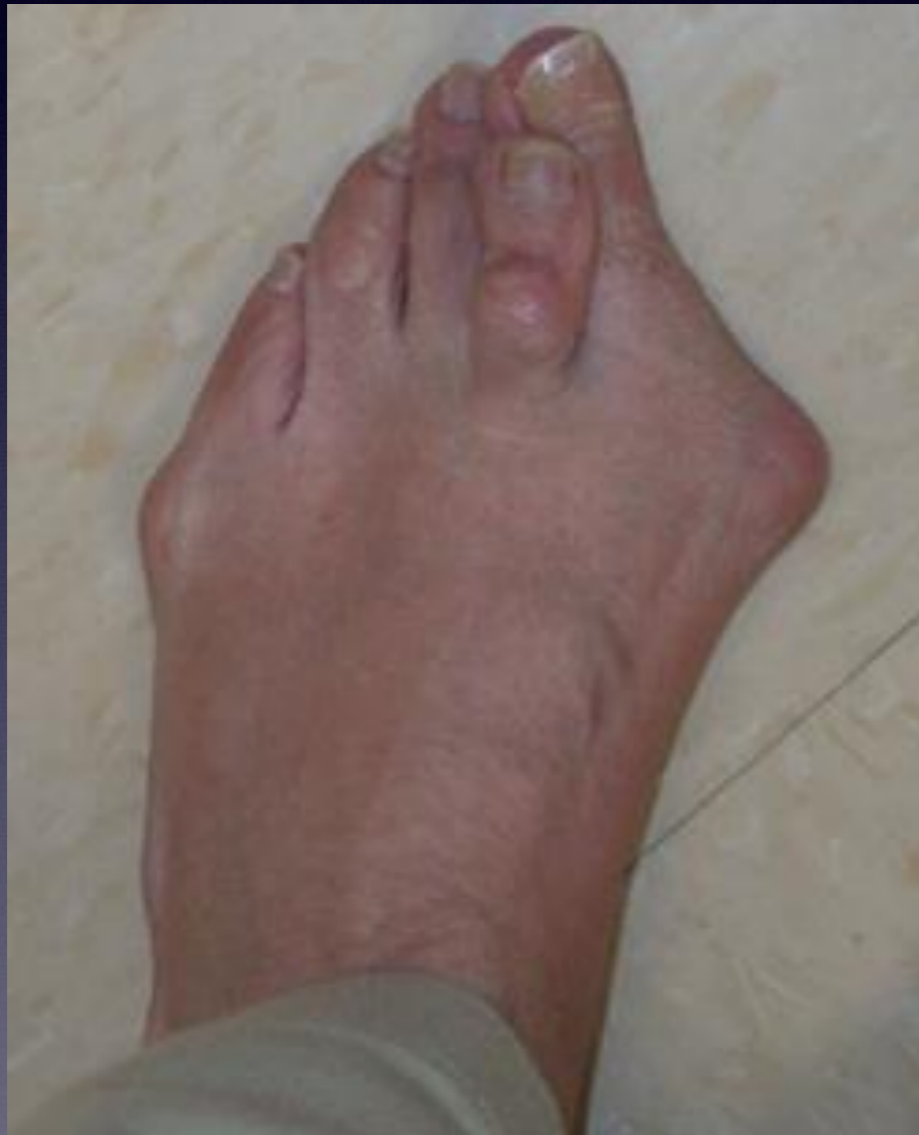Forefoot and Digital Deformities

- Hallux Limitus
- Hallux Valgus
- Fat Pad Atrophy with Prominent Met Heads
- Intrinsic Minor Foot
- Hammertoes - PIPJ Contracture
- Claw Toes - DIP, PIP, MTPJ Contractures

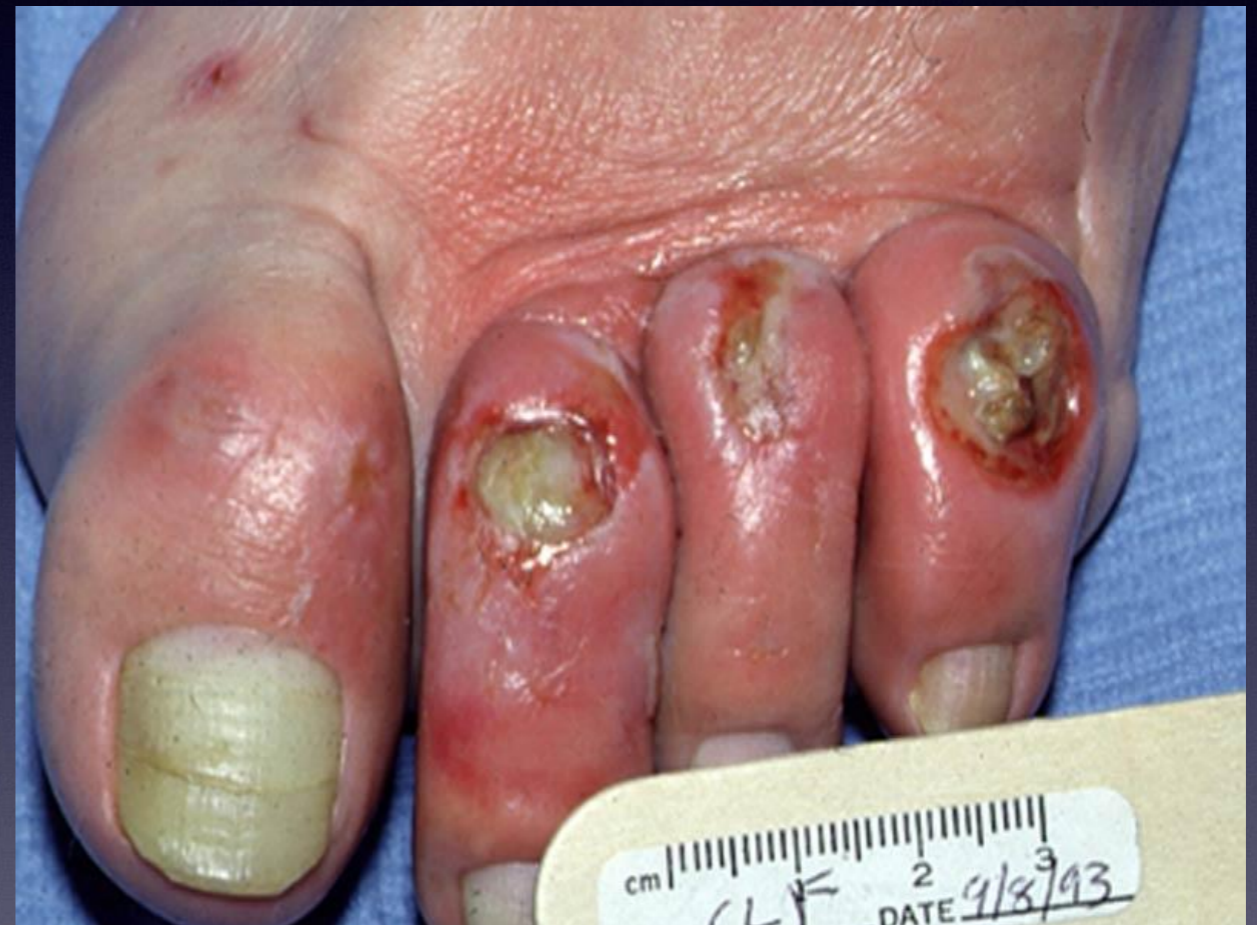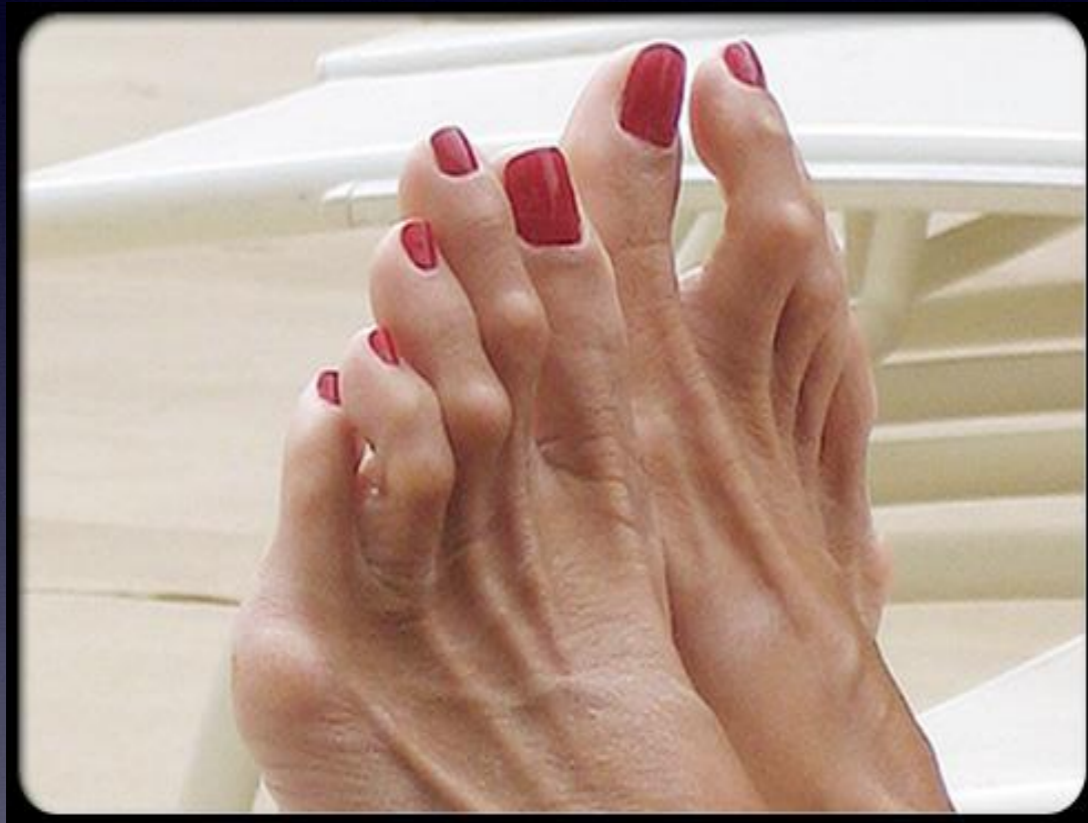Midfoot/Hindfoot Deformities

- Neuropathic Joint (Charcot)
- Acquired Pes Planus, PTTD
- Hindfoot, Ankle Valgus
- Again Evaluate for Equines

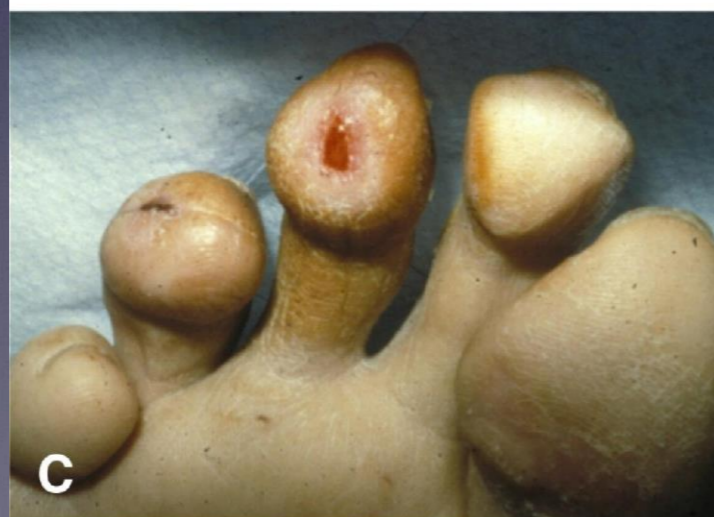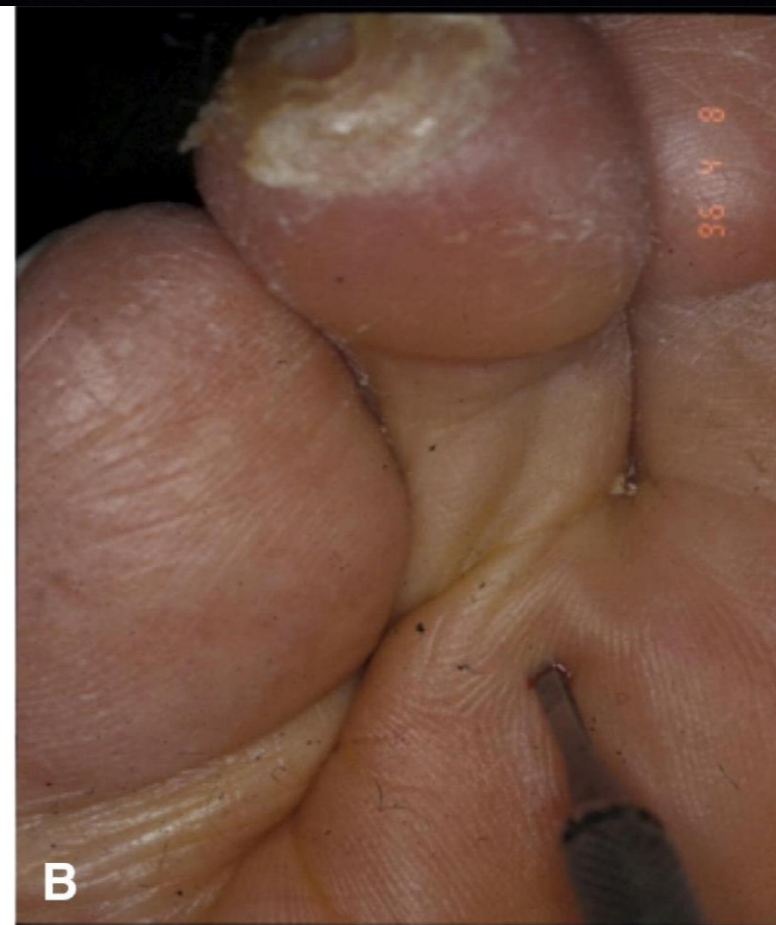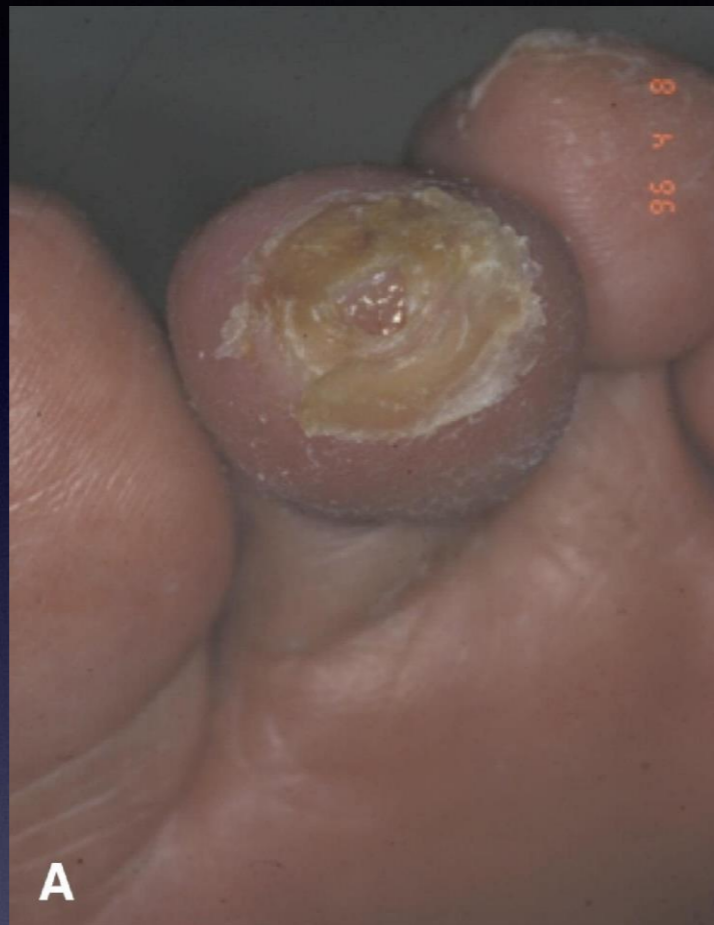Biomechanical Risks: Hallux Valgus; Hallux Rigid



Biomechanical Risks: Contracted Claw Toes; Hammertoes



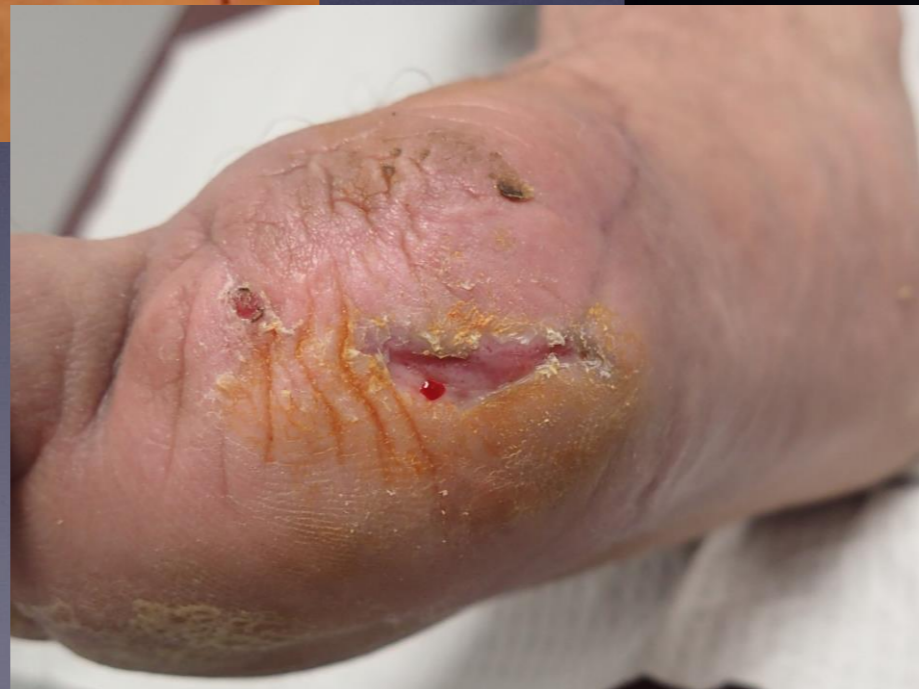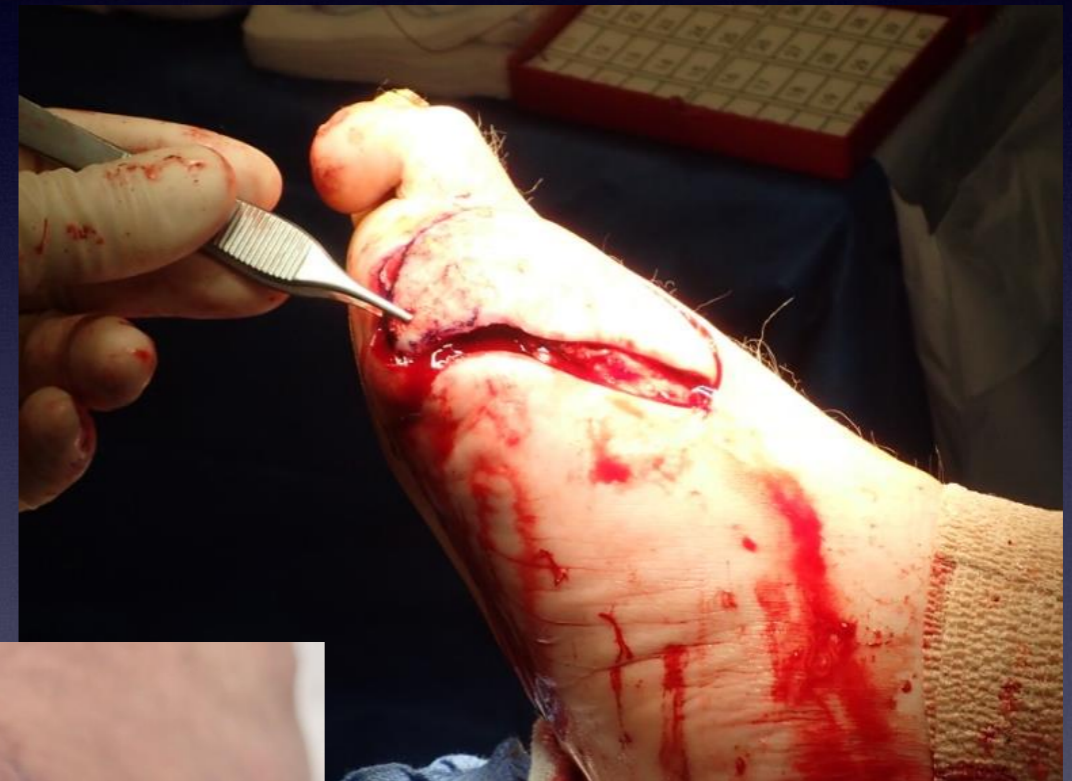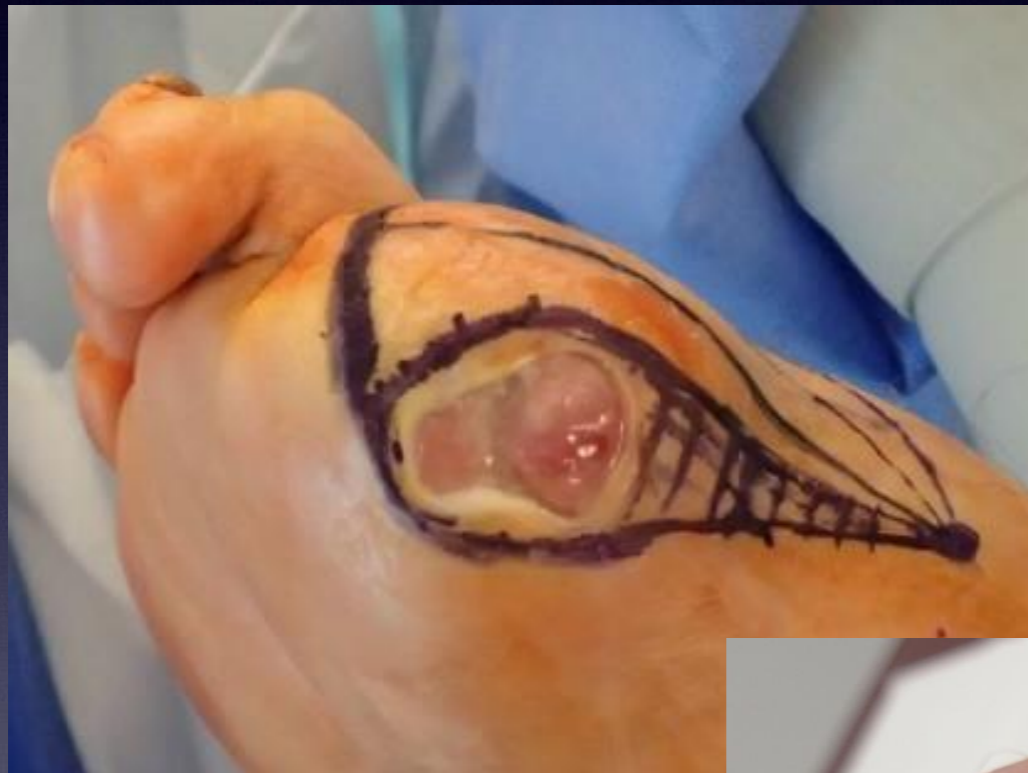Percutaneous Flexor, Extensor Release



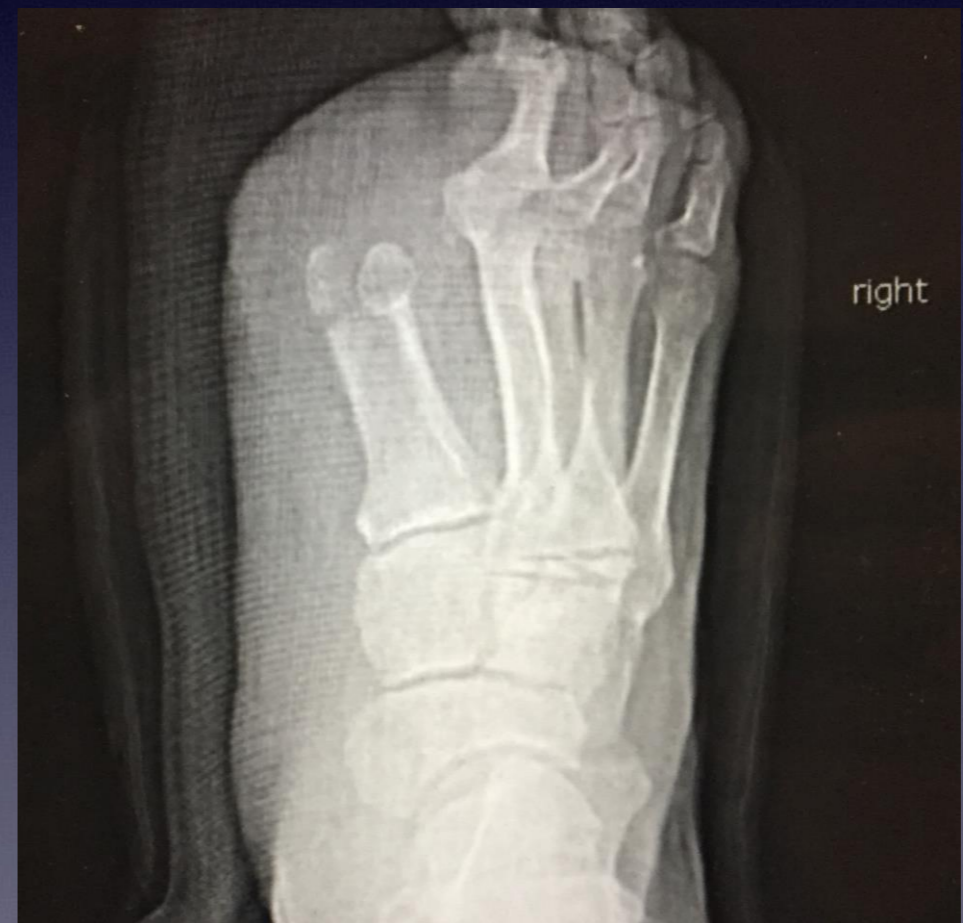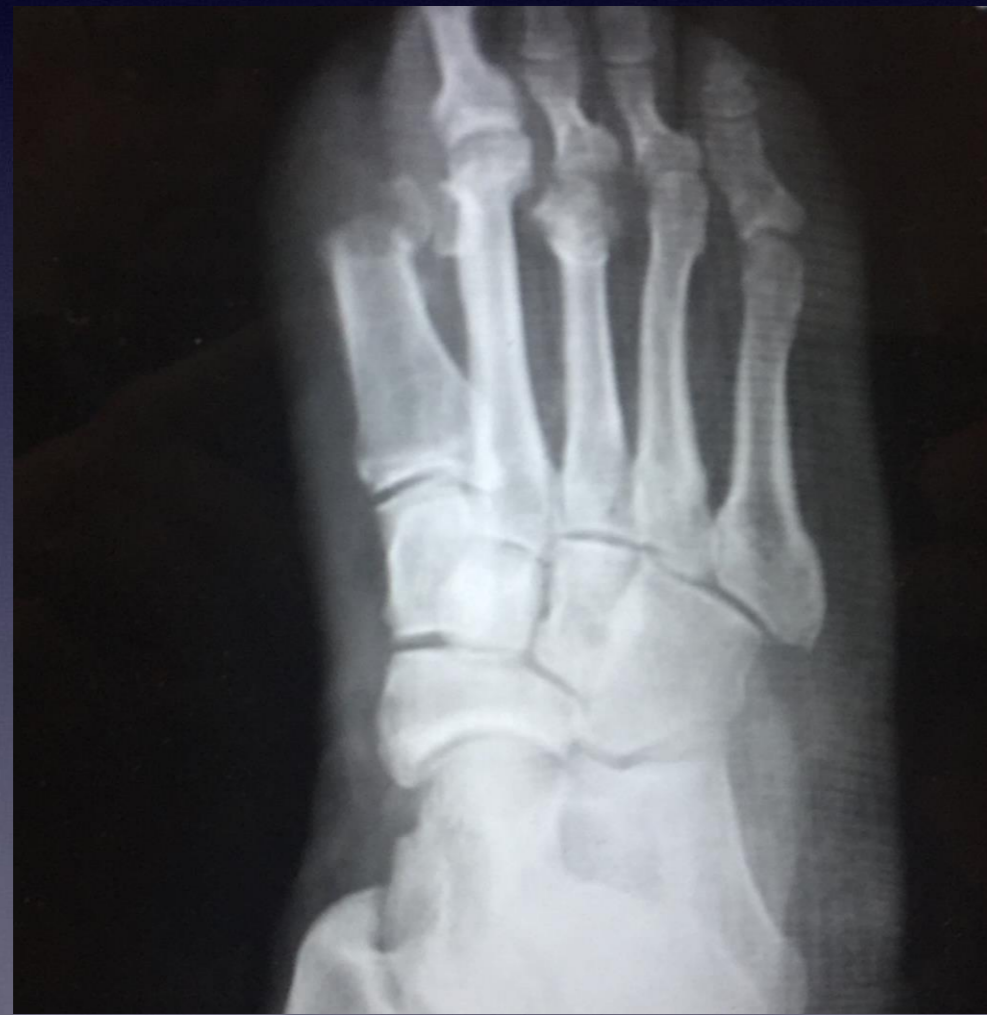Metatarsal Head Resection

- Indications
 - Sub Met 2-5 Wound or Pre-Ulcerative Lesion
 - Osteomyelitis
 - Intrinsic Minus foot, Contracted toes
 - Previous amputation with transfer lesion.
 - Evaluate for Equines

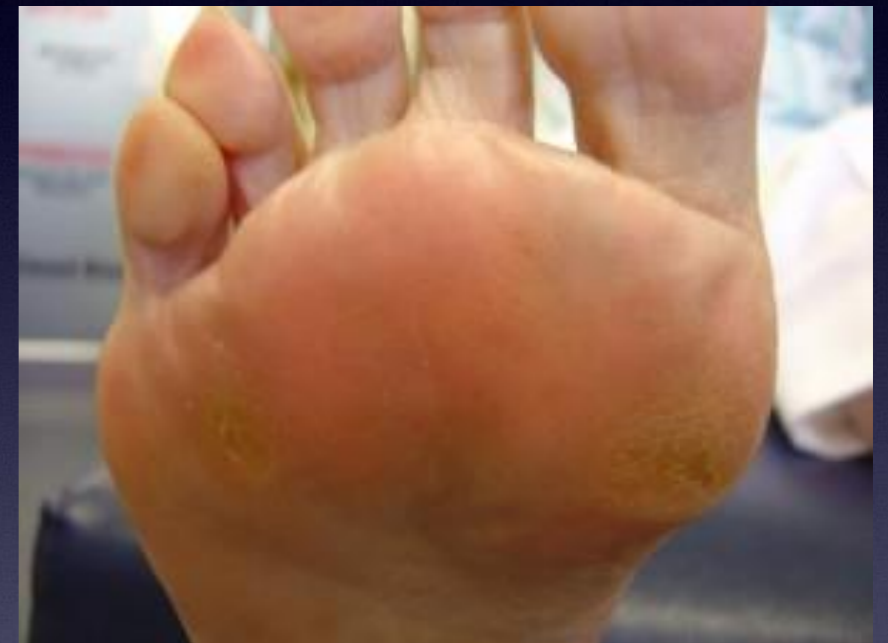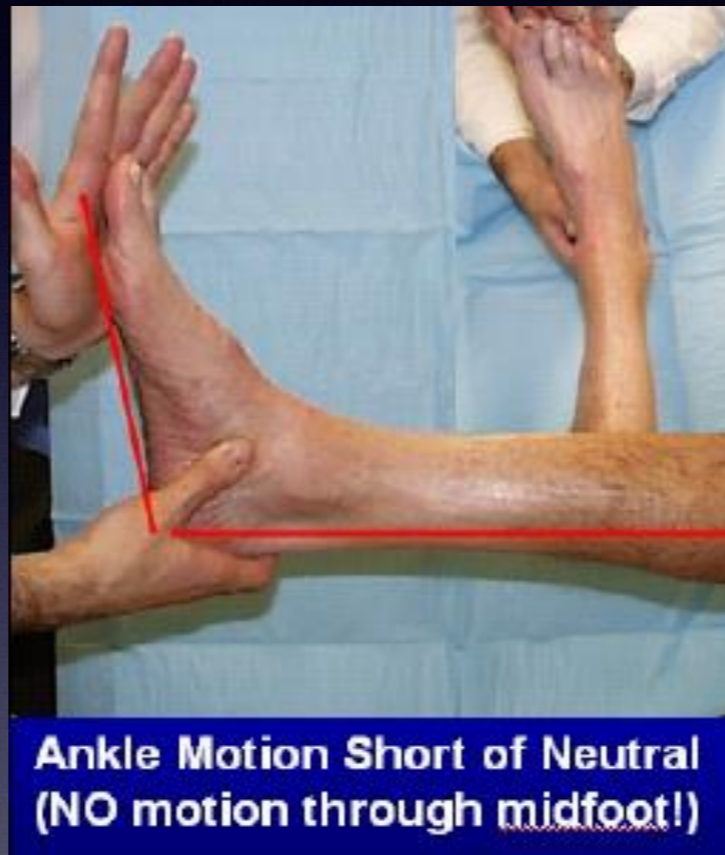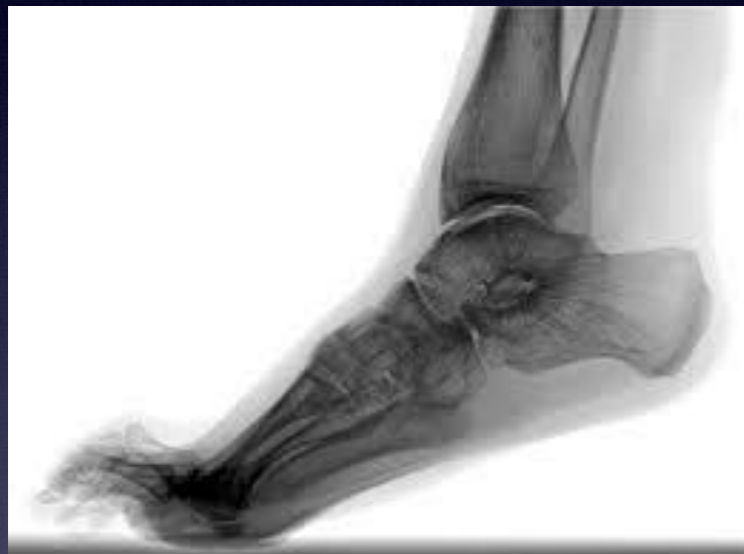Class III: Met Head Resection with Adjacent Flap Closure



Met Head Resection with Adjacent Flap Closure

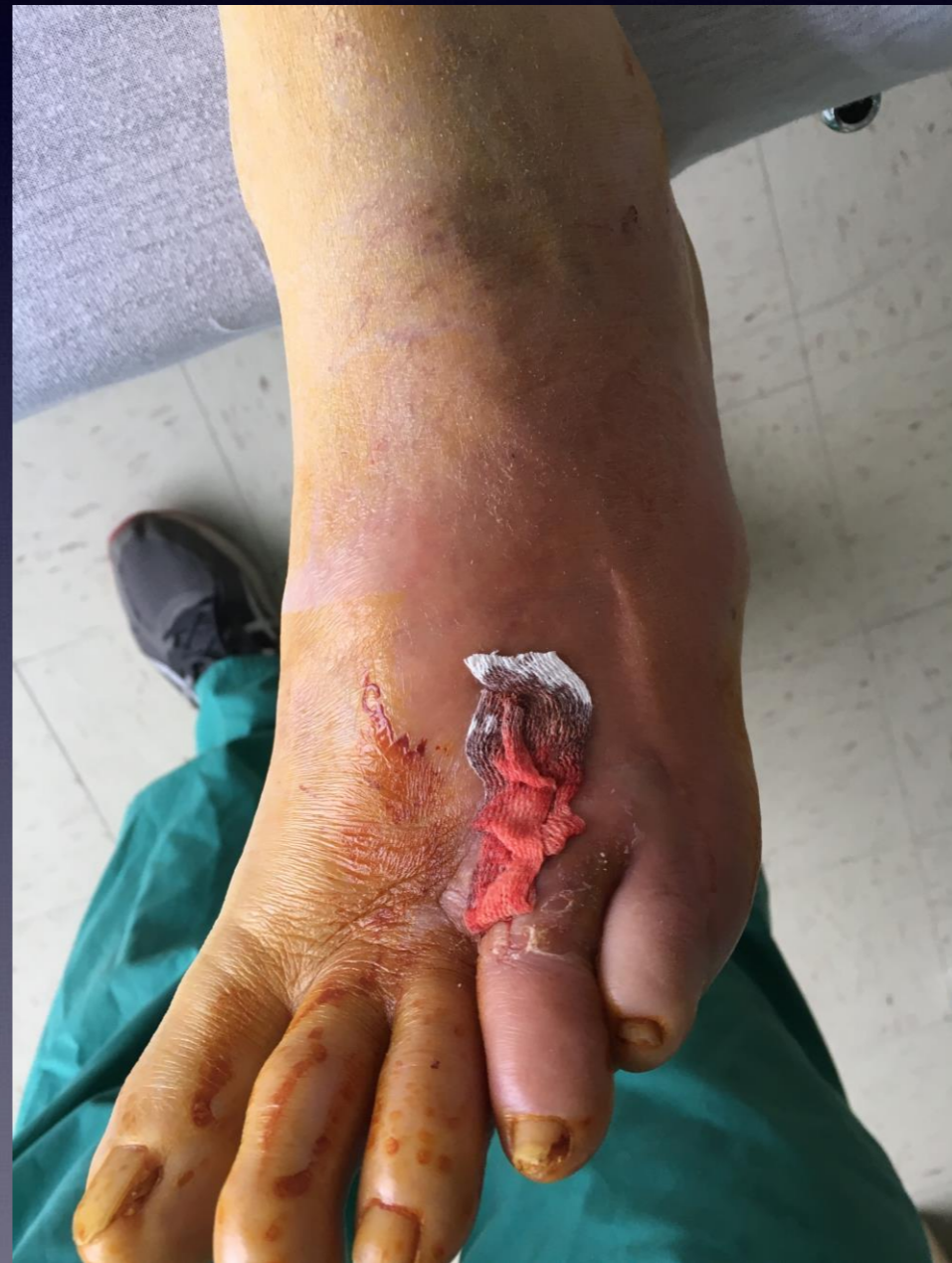
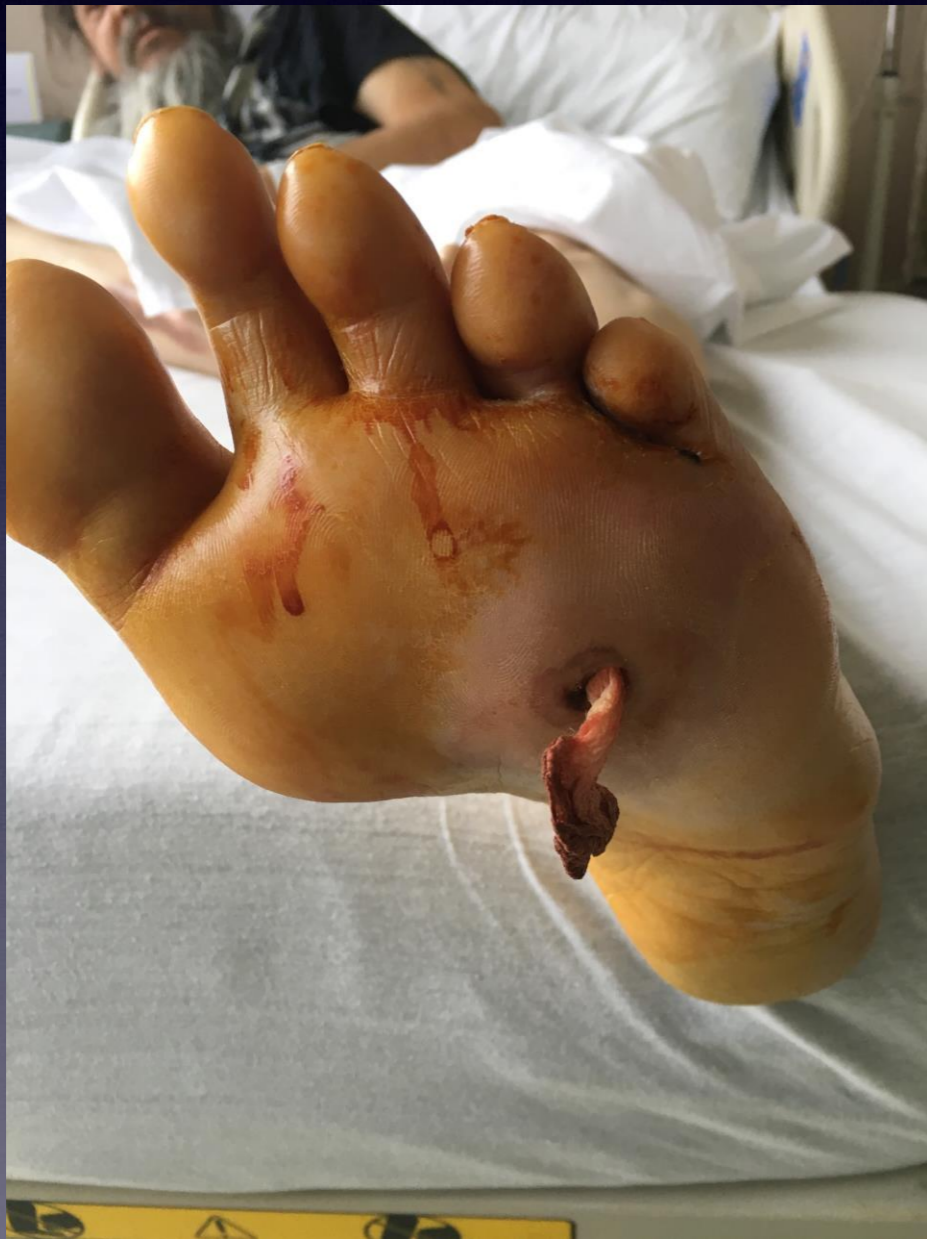
Biomechanical Risks: Ankle Equinus

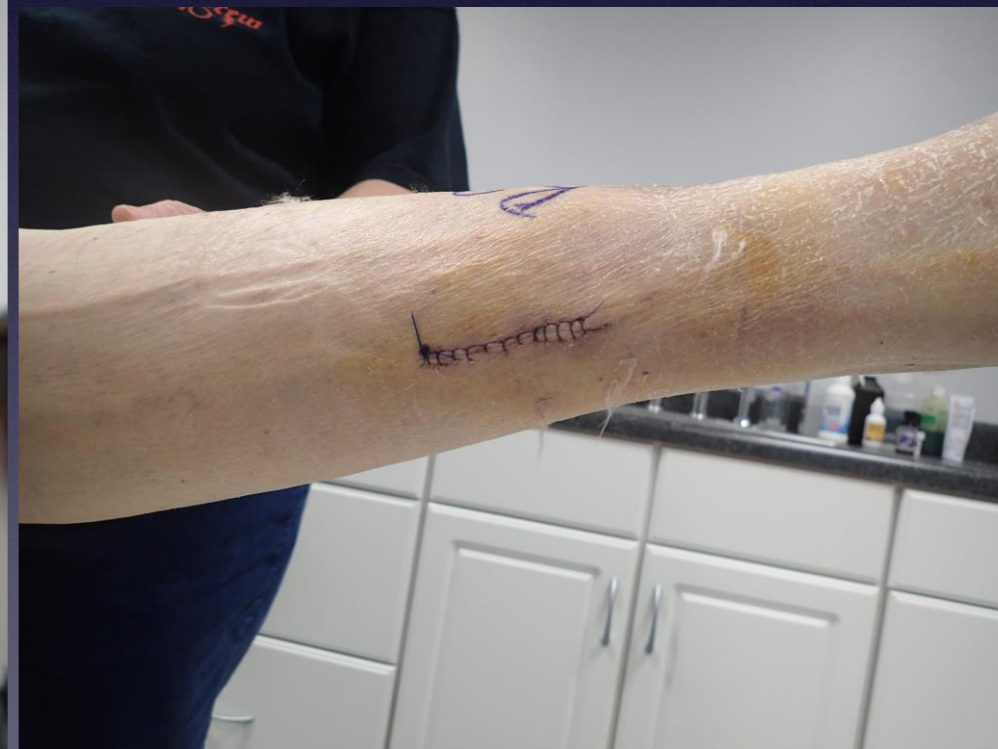
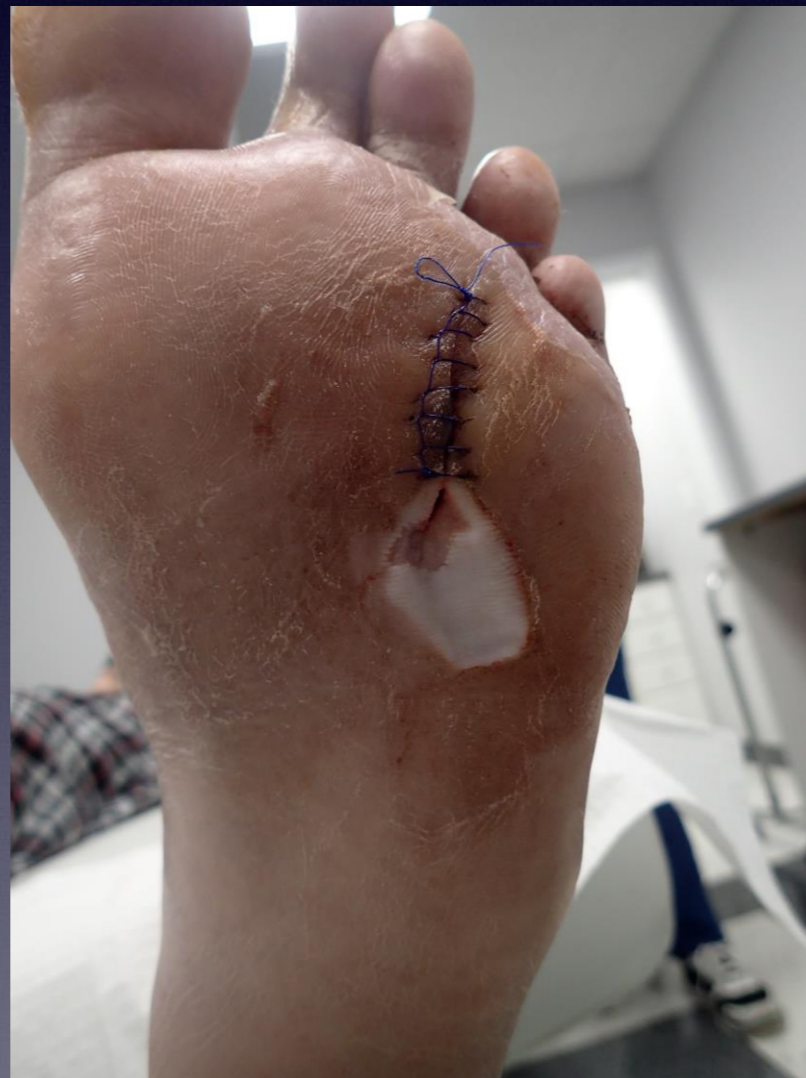
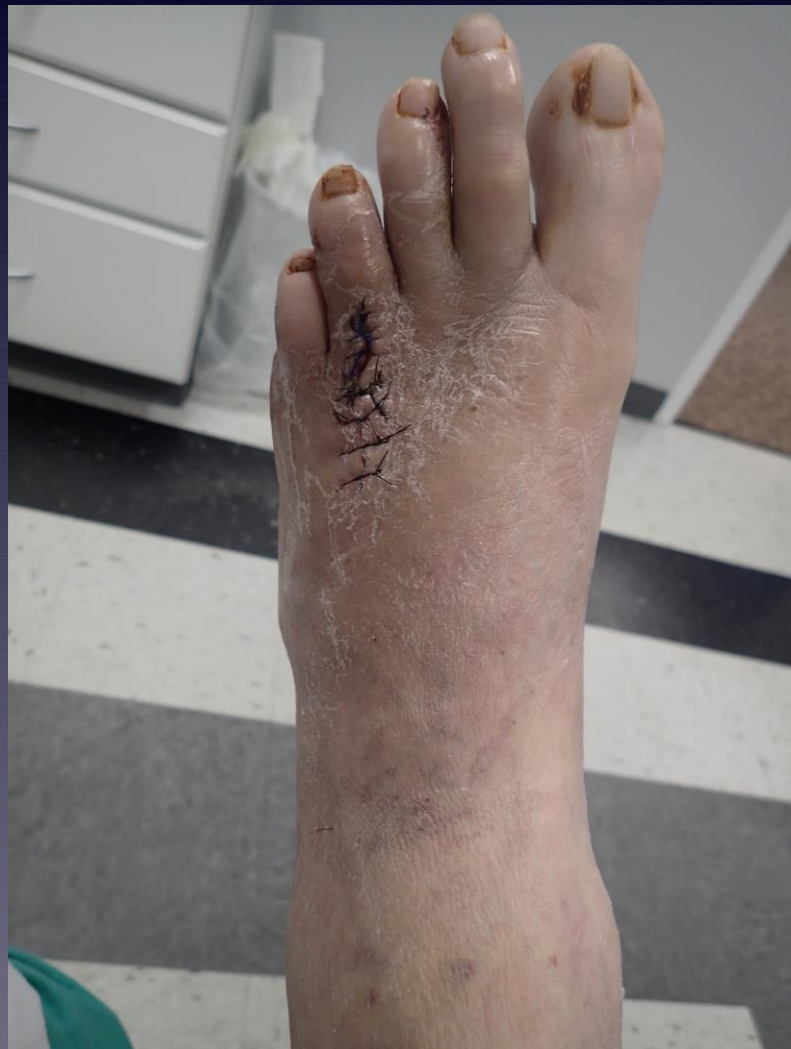- Restriction at the Ankle Joint is #1 Deforming force on the foot

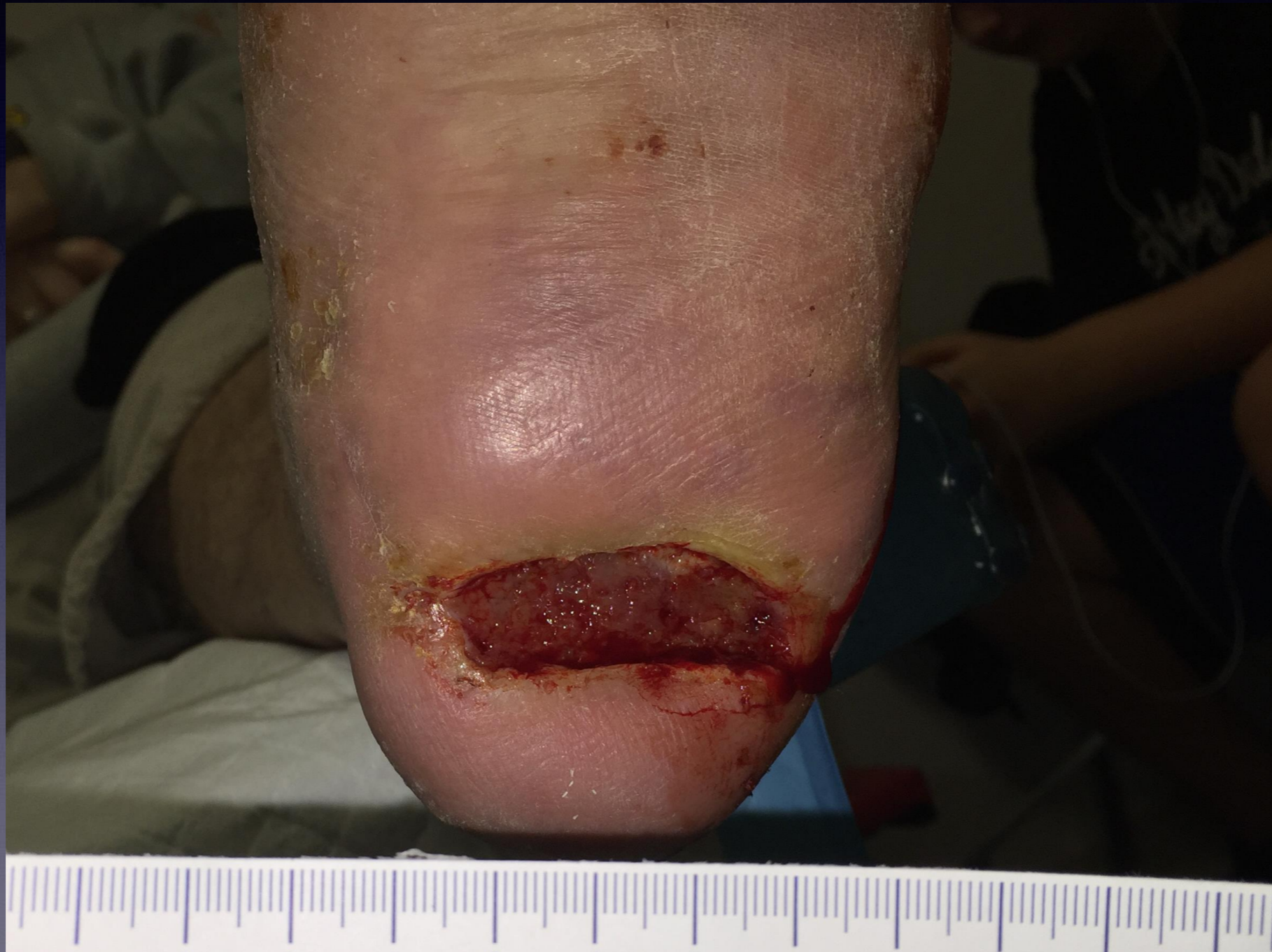Class III: DFI/DFU, Equinus, OM 4th Met Head



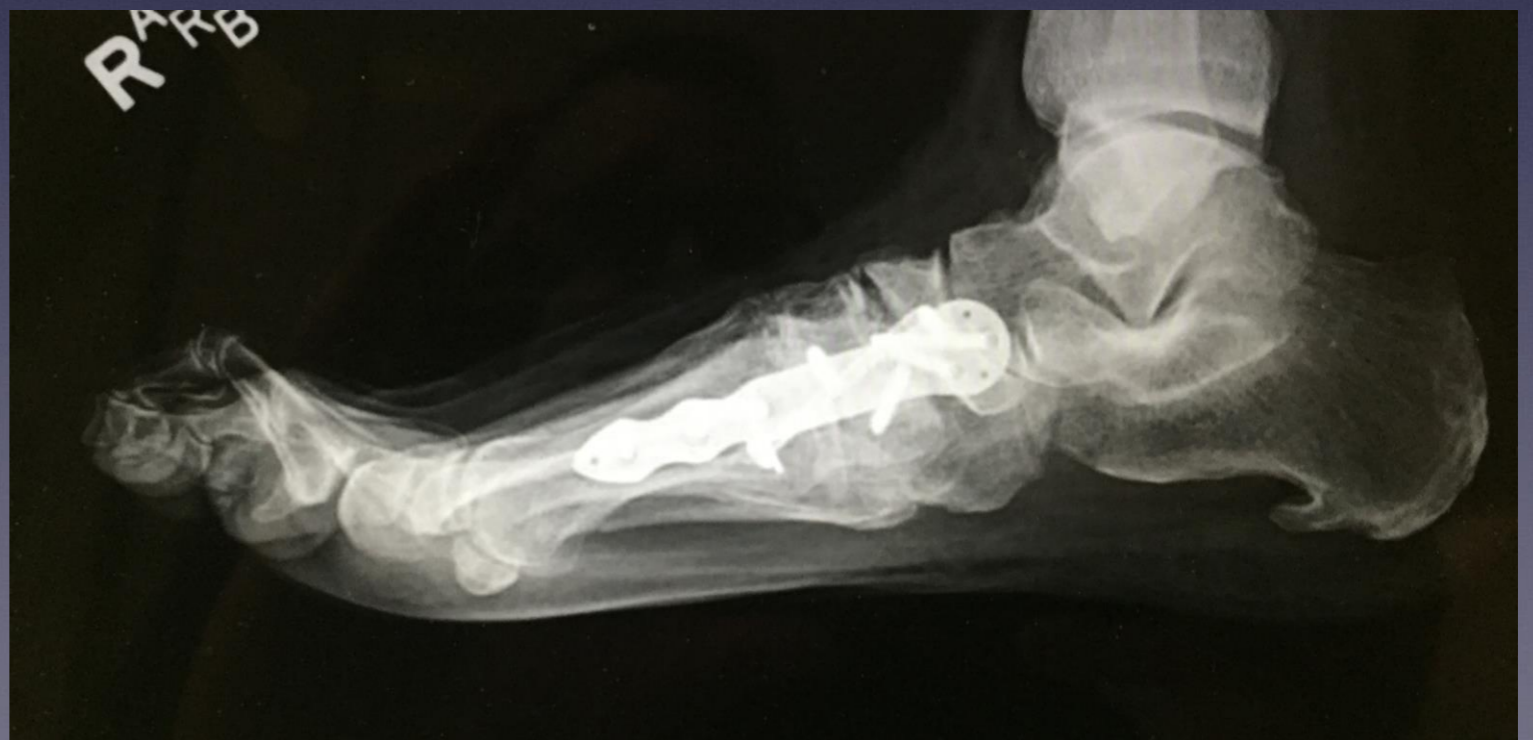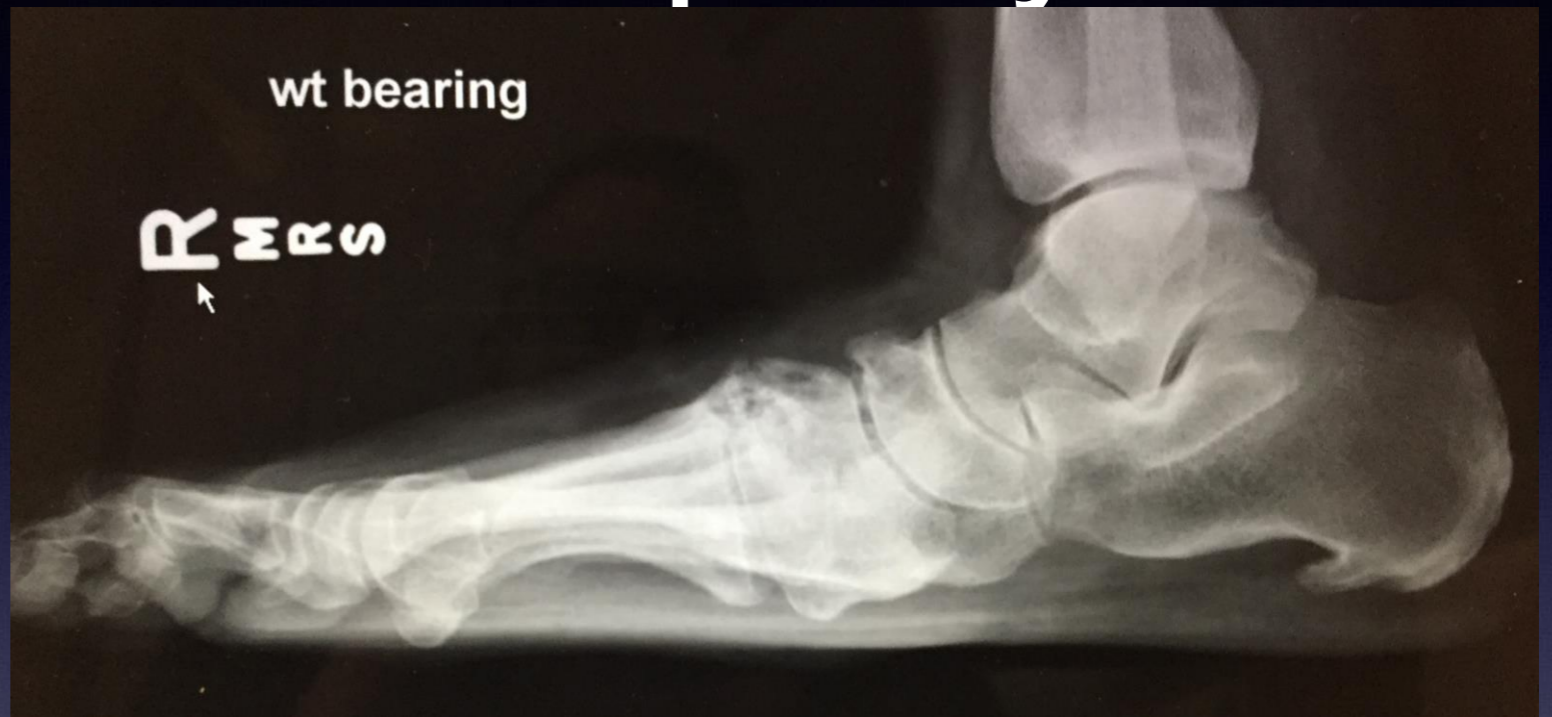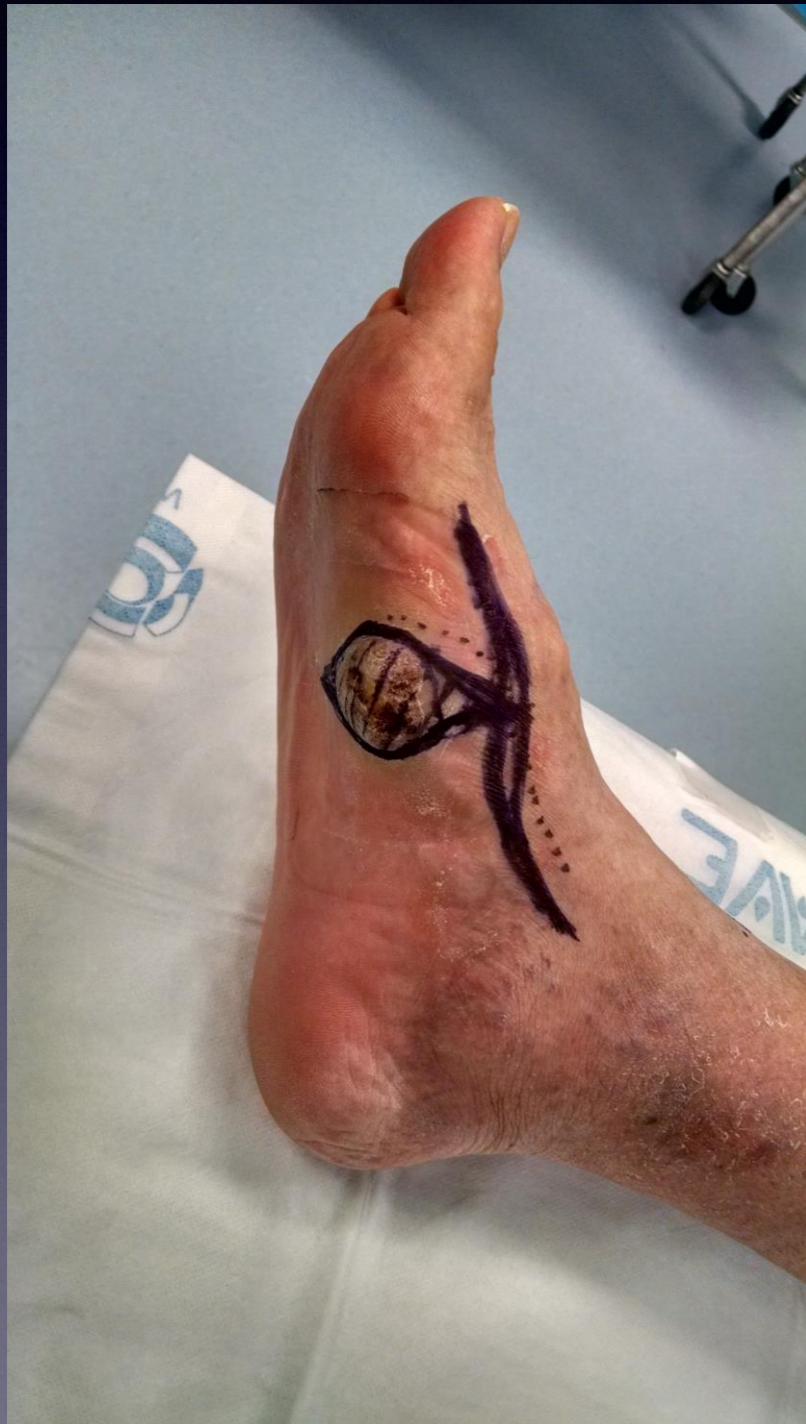Class III: DFI/DFU, Equinus, OM 4th Met Head



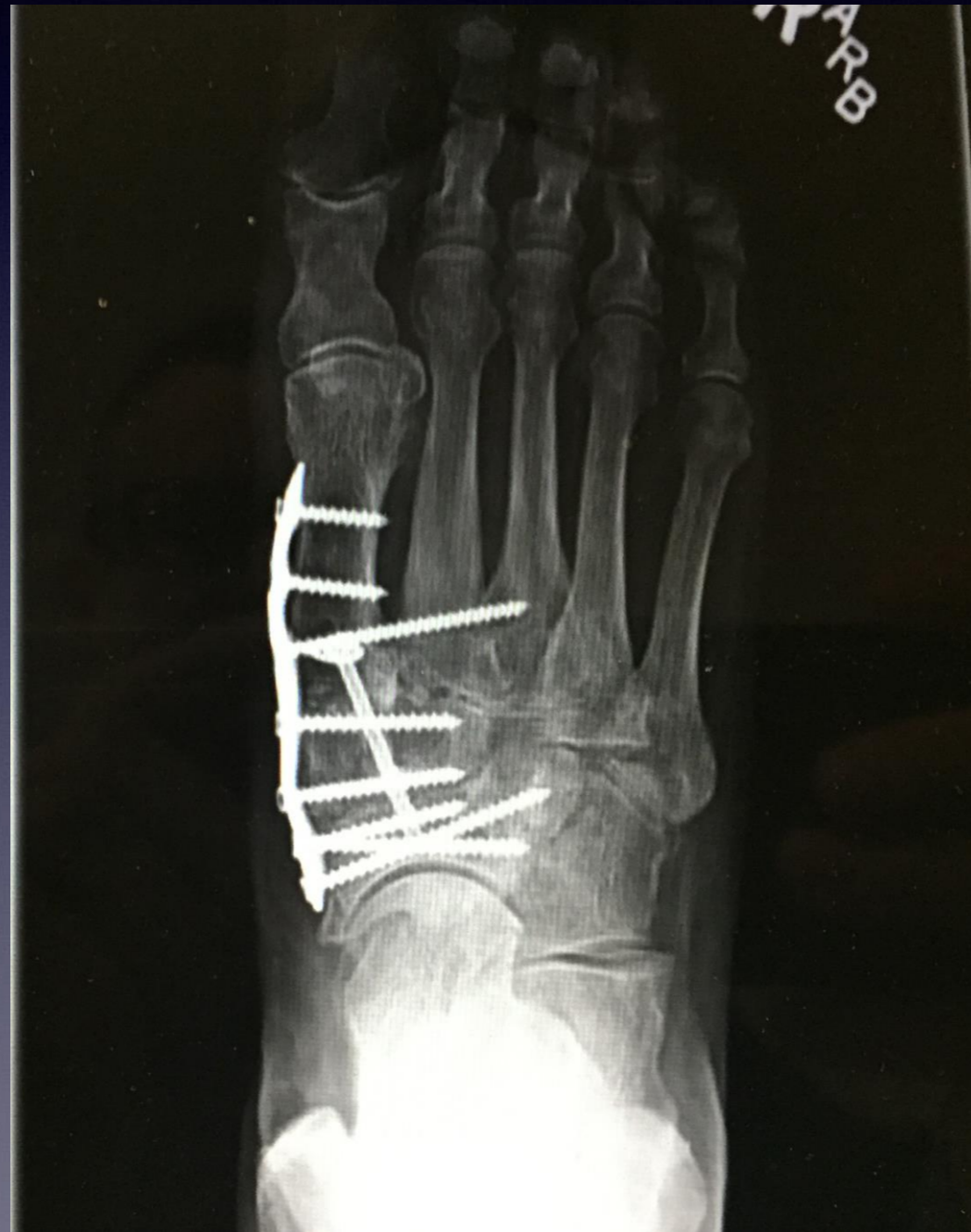Take Caution!



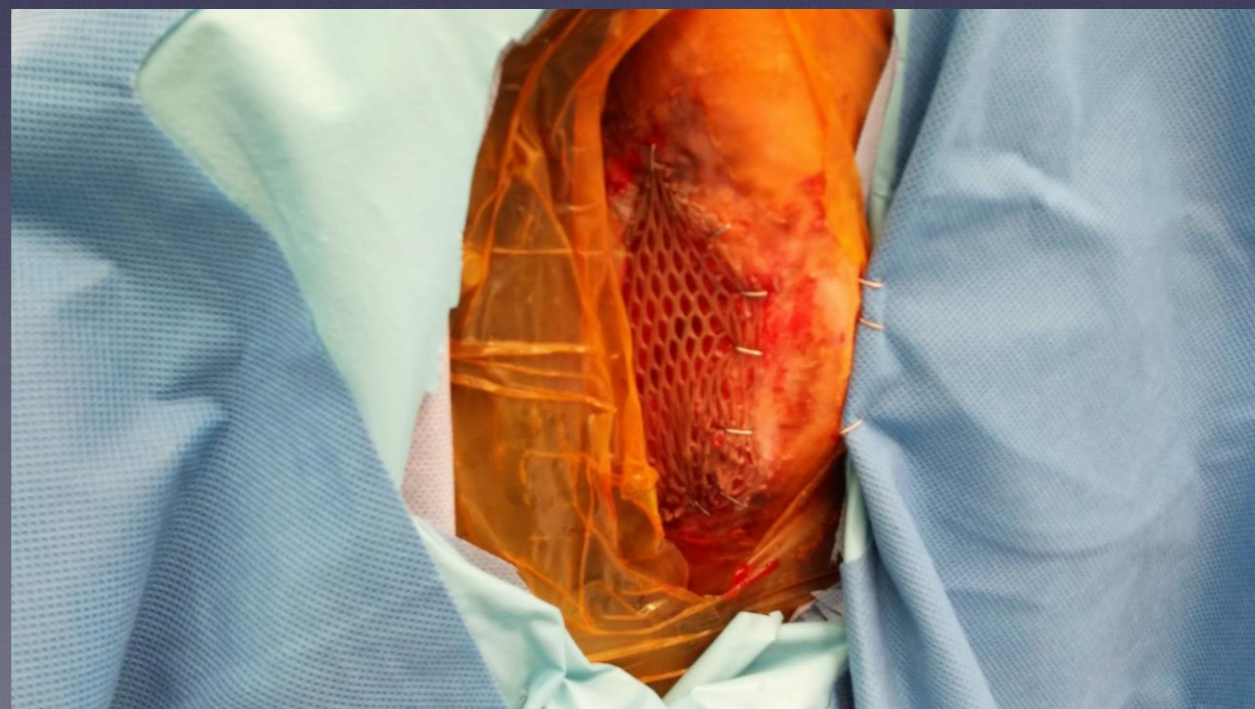
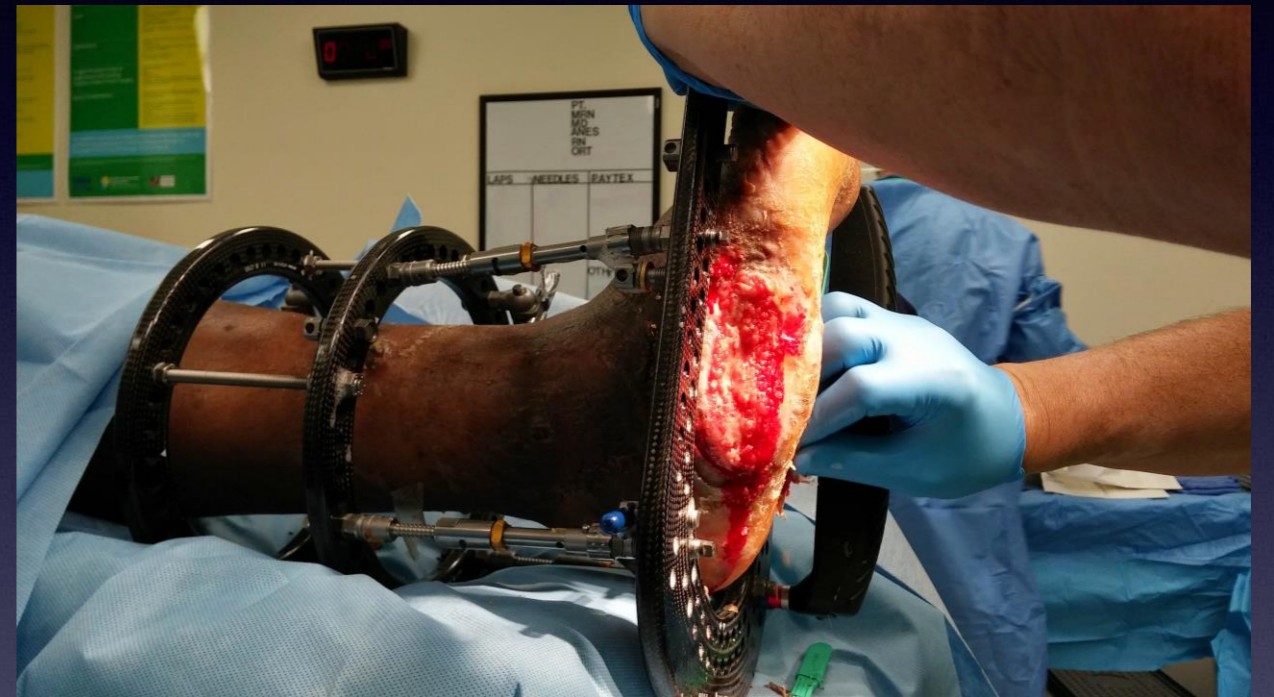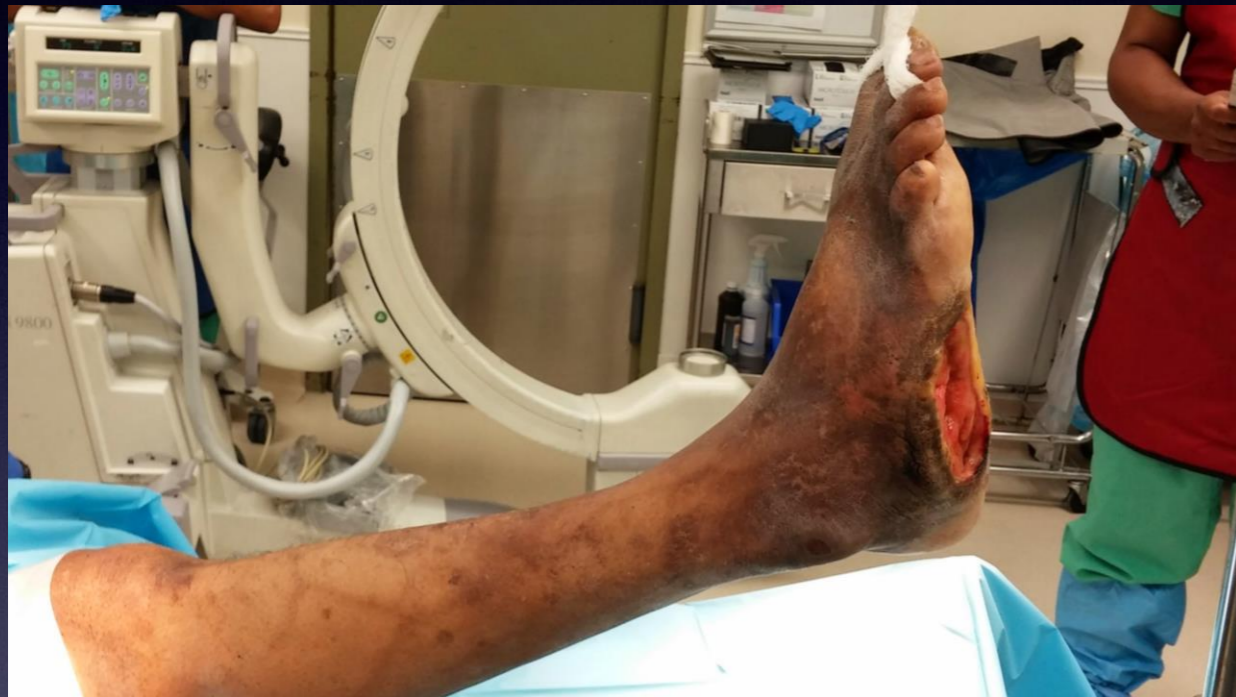Coalesced Neuropathic Midfoot Arthropathy



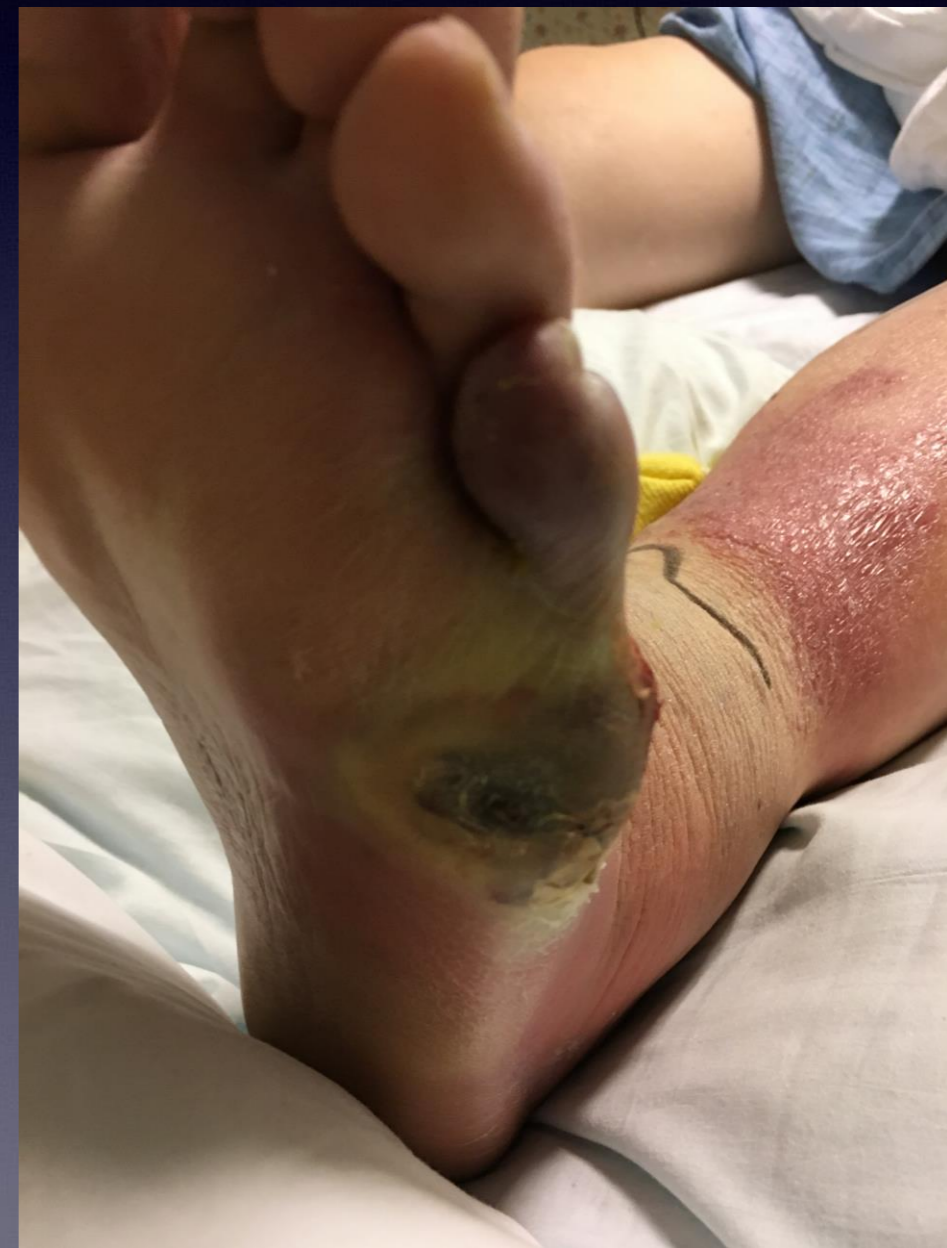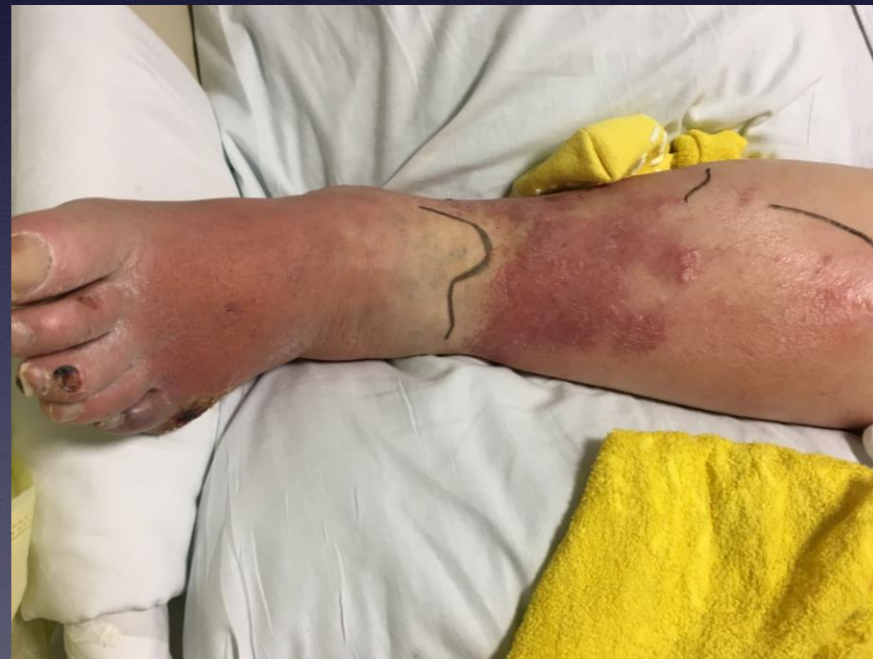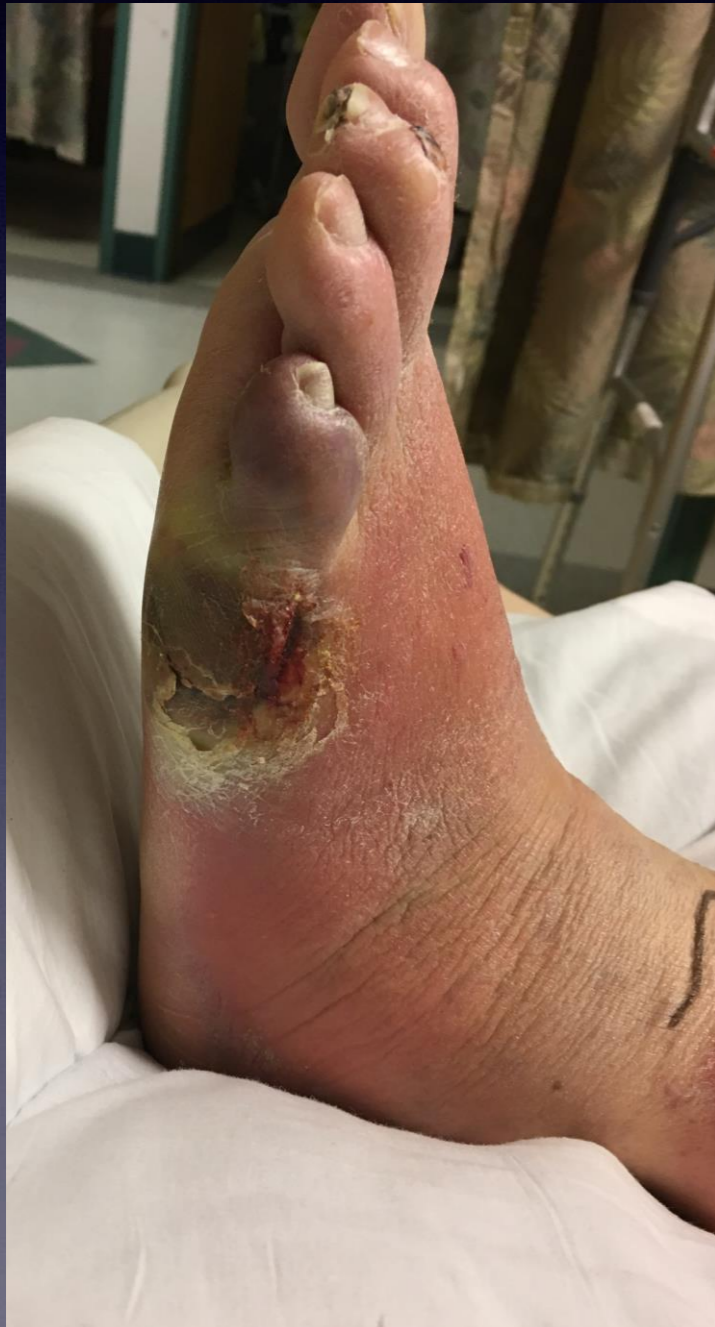Coalesced Neuropathic Midfoot Arthropathy



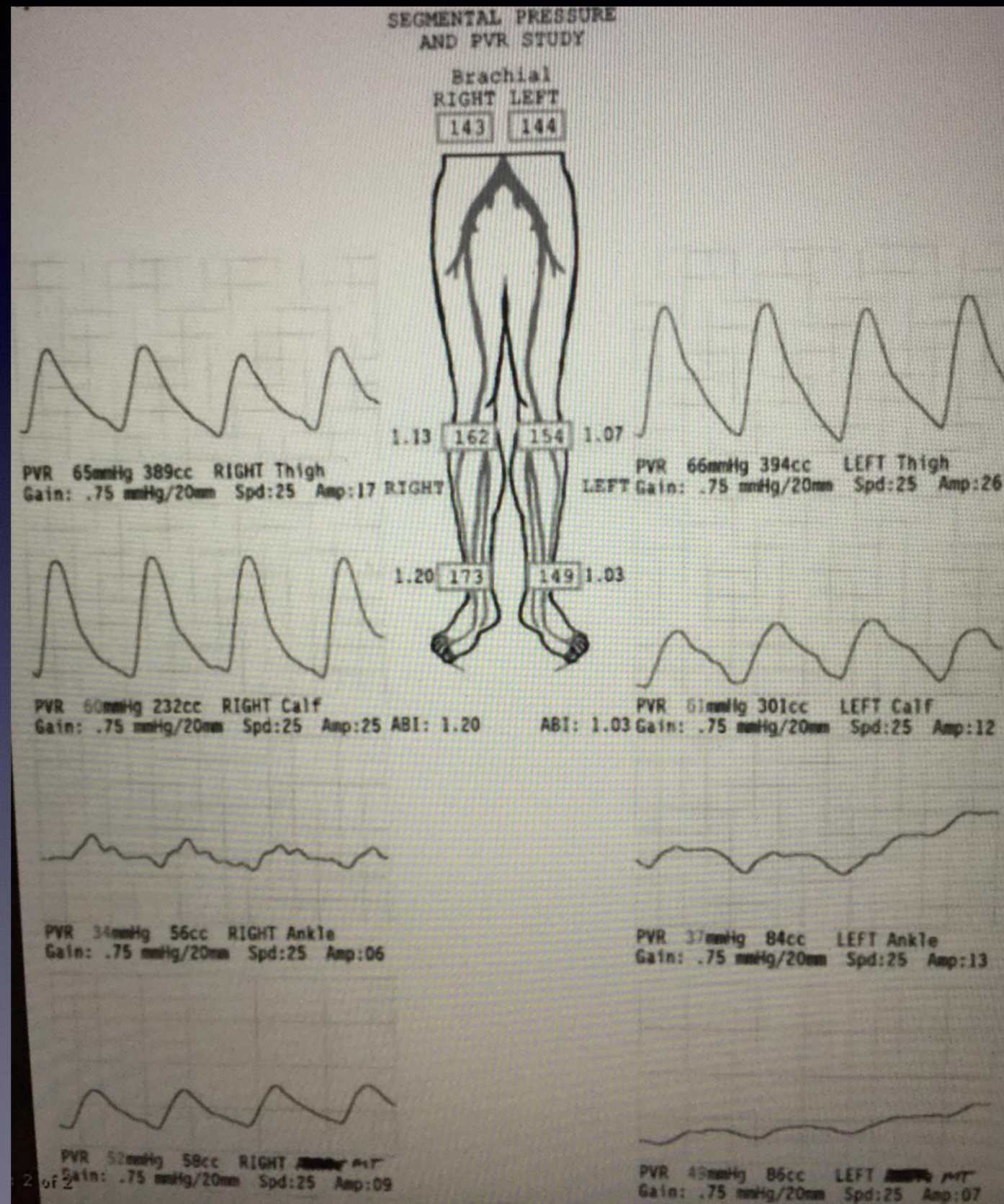
Class III: Chronic Wound, Equino Varus



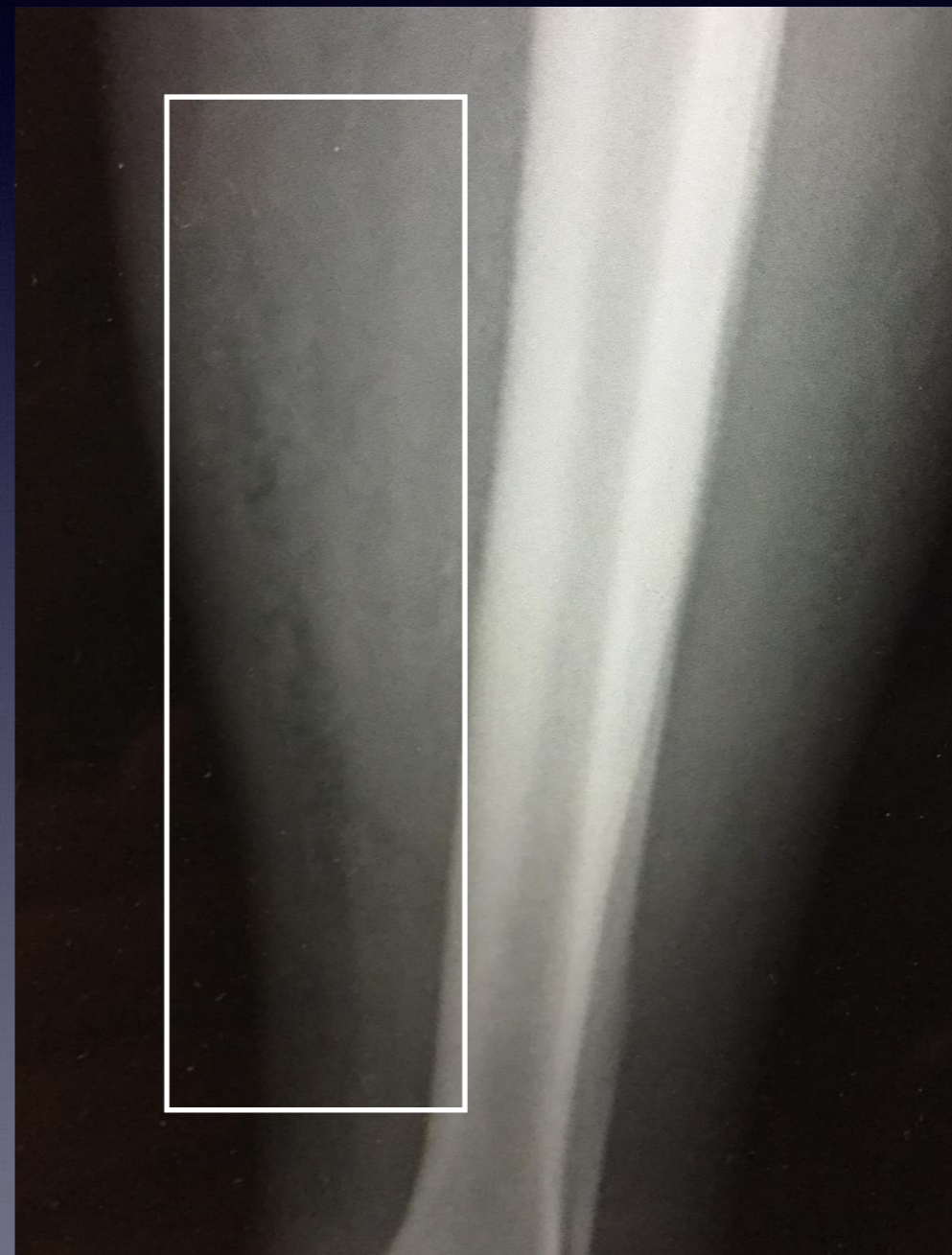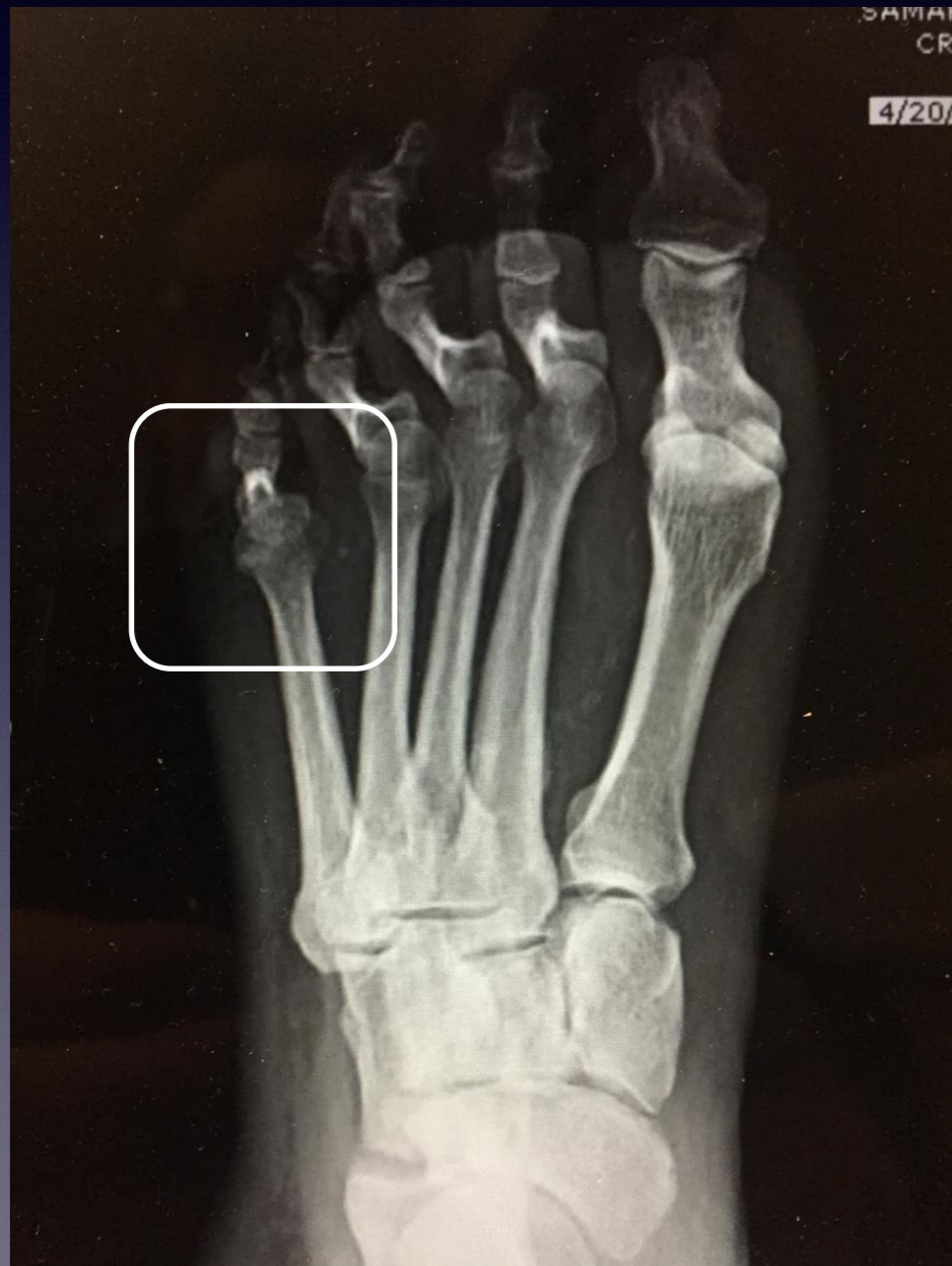Class 4: Limb Threatening Infection



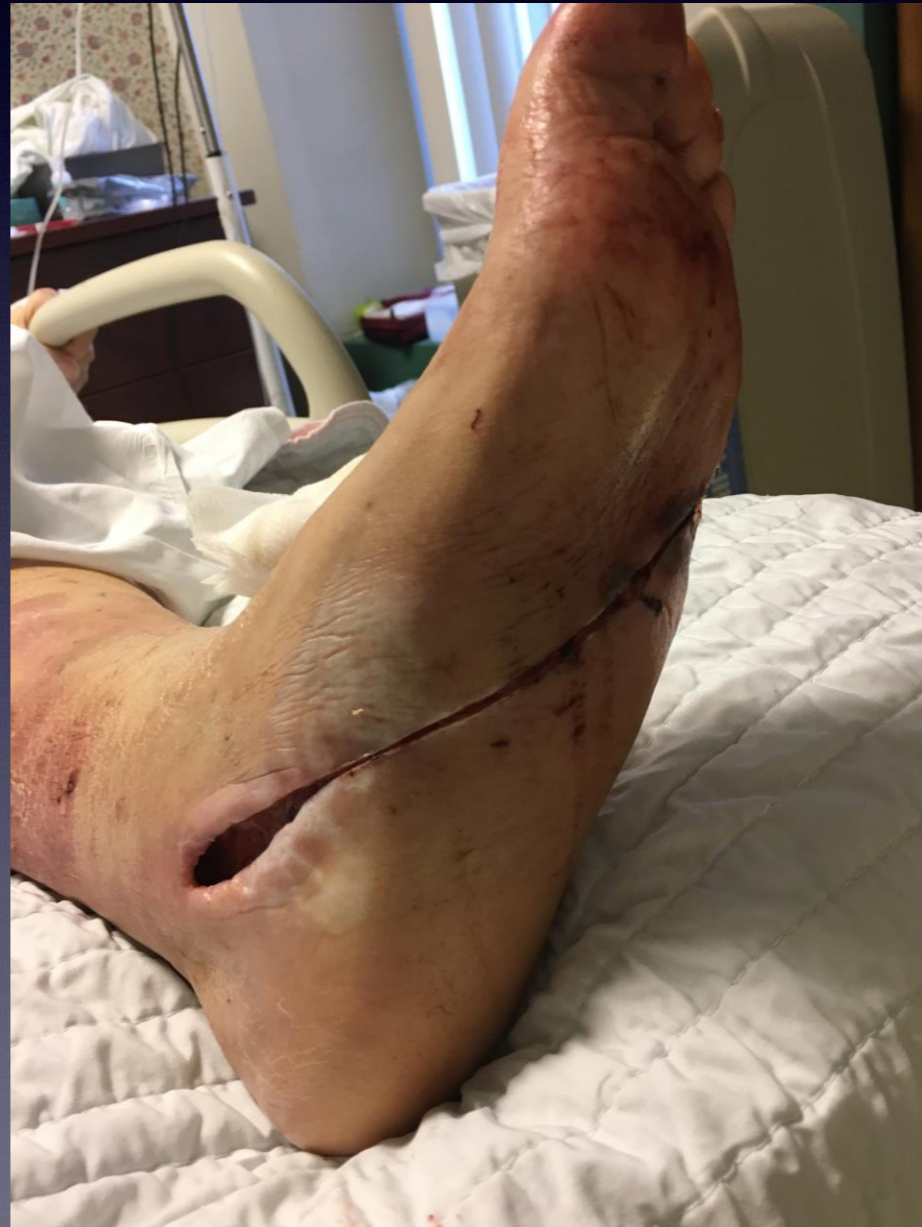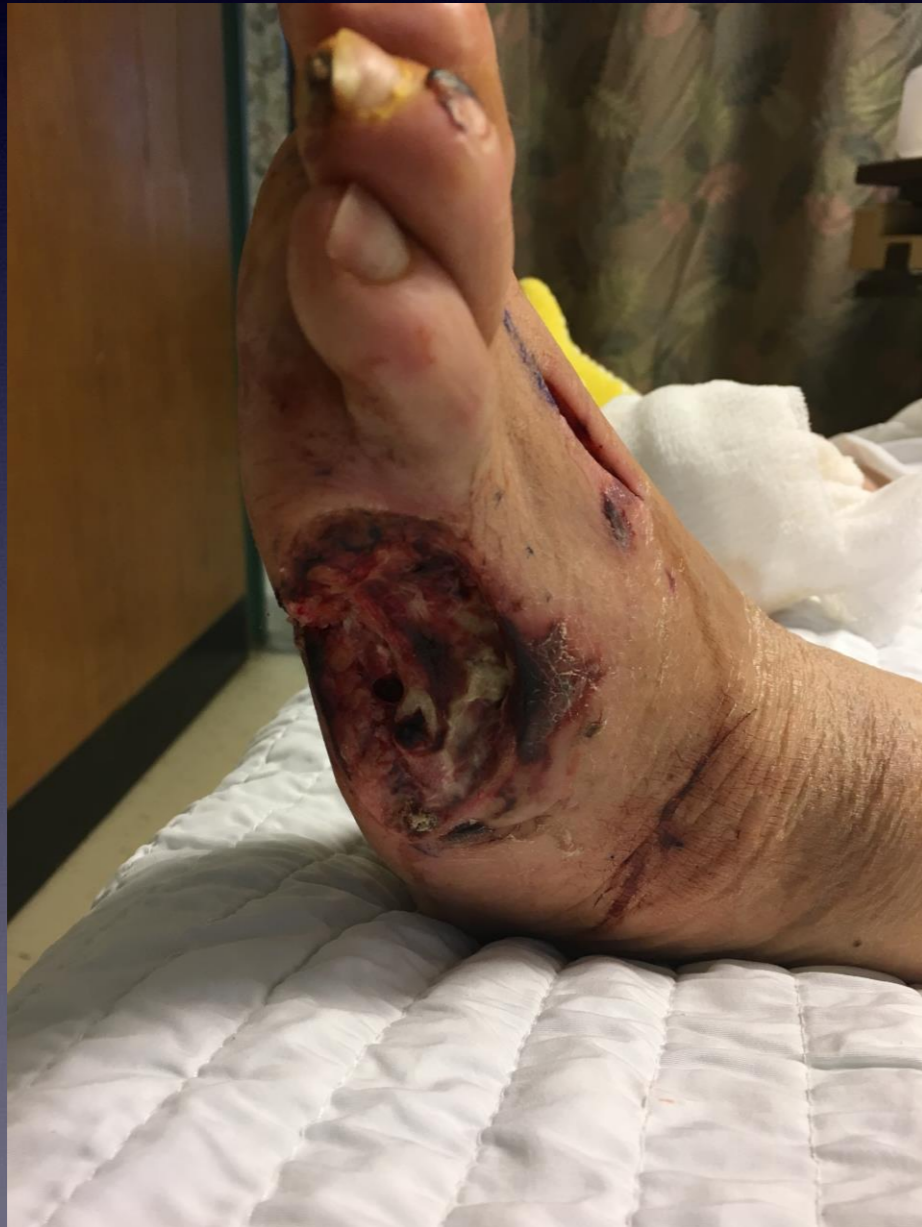Class 4: Limb Threatening



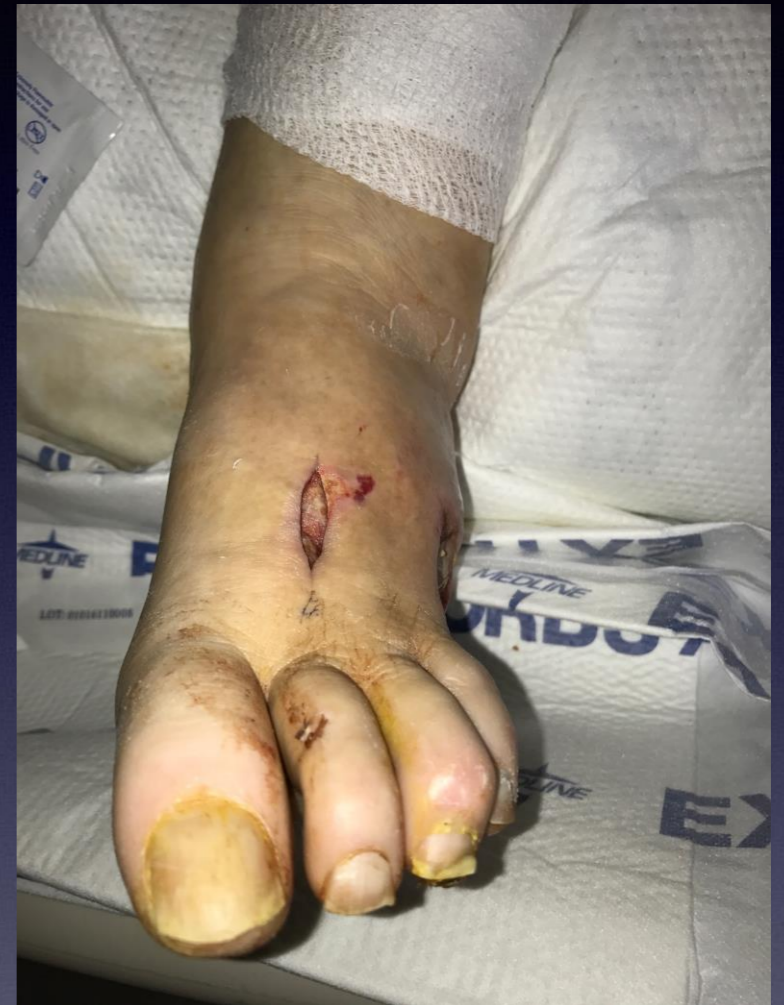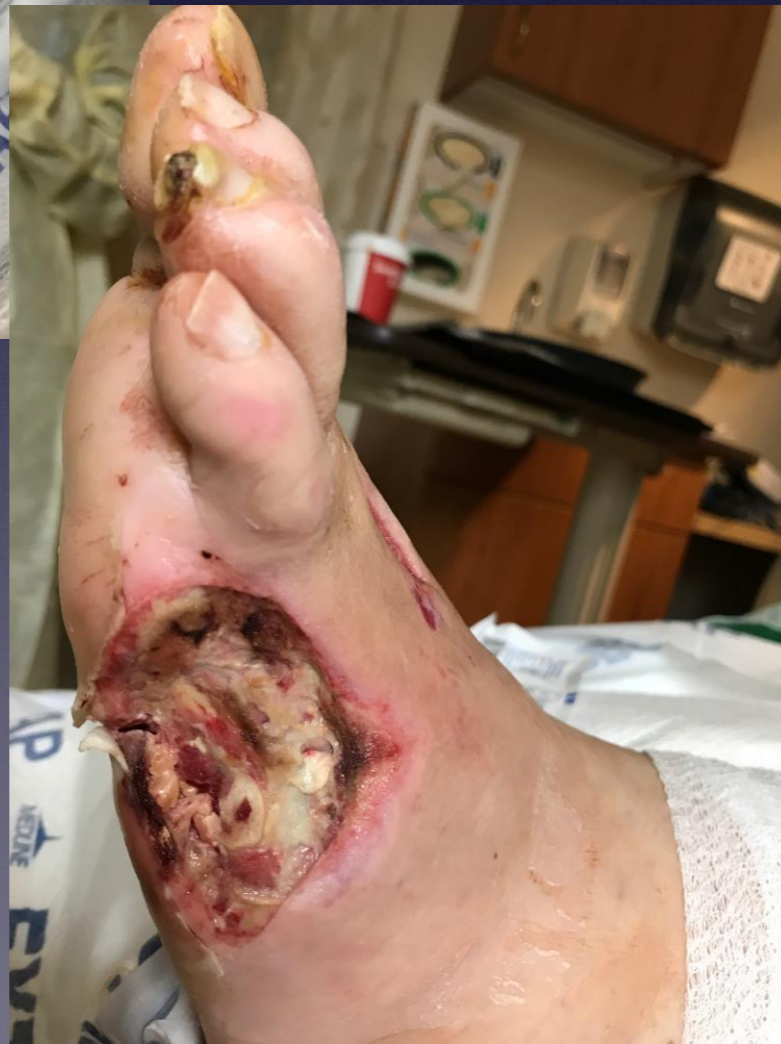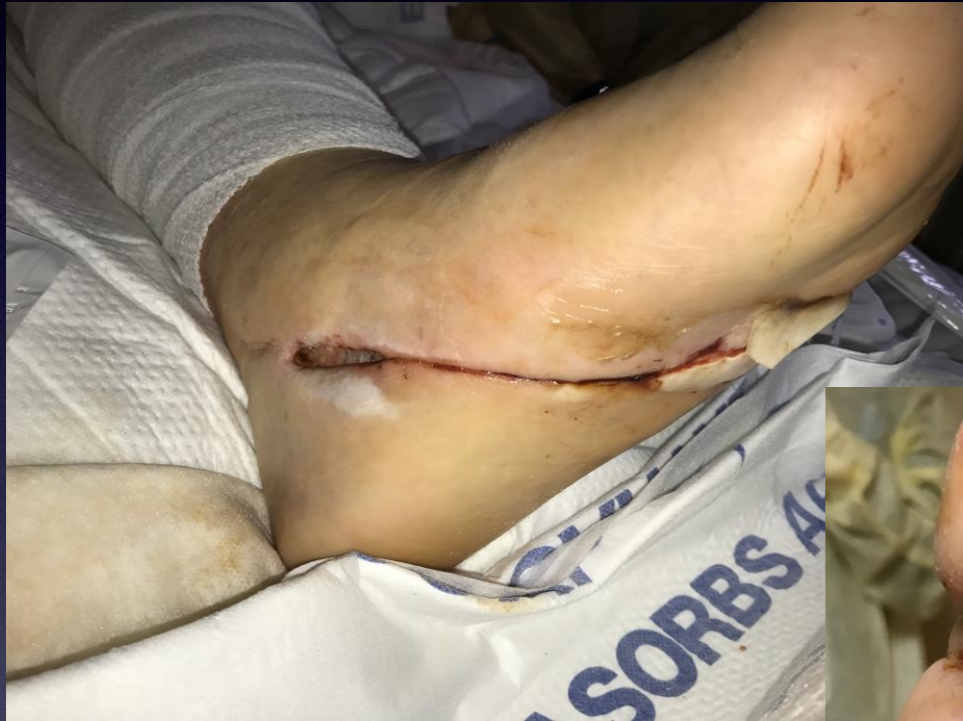Class 4: Limb Threatening Infection



Class 4: Limb Threatening Infection



Class 4: Limb Threatening Infection



Thank you!

Richard T. Bauer III DPM, AACFAS

Summit Foot and Ankle

1072 Troy-Schenectady Road, Suite 303

Latham, NY 12110

Medical Director, Seton Wound Care Center

rbauer.dpm@gmail.com