

EM CASE OF THE WEEK.

BROWARD HEALTH MEDICAL CENTER
DEPARTMENT OF EMERGENCY MEDICINE



Care Warriors

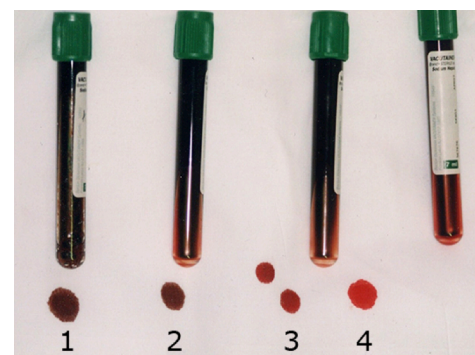
Author: Dona Rose | Editor: Benita Chilampath DO, PGY-II

April 2018 | Vol 4 | Issue 67

Acquired Methemoglobinemia

A 34-year-old female presents to the ED with a 24-hour history of dyspnea, headaches, and weakness. Past medical history reveals she had a kidney transplant 4 years ago but currently has normal renal function. Home medications include Tacrolimus, Metoprolol, Metoclopramide and Dapsone. Physical examination reveals gray skin discoloration, pale conjunctiva, and 3/5 muscle strength in all extremities bilaterally. Pulse oximetry shows 85% saturation on room air, however an arterial blood gas reveals a PaO₂ of 96 mmHg. Co-oximetry is performed and confirms the diagnosis. Which of the following is the most appropriate management for this condition?

- A. High-flow oxygen via non-rebreathing mask
- B. Hyperbaric oxygen therapy
- C. Methylene Blue
- D. Observation with supportive care
- E. Sodium Nitrite



©2017 UpToDate®
Methemoglobinemia

Methemoglobinemia causes a change in blood color based on percentage of methemoglobin present.

Note the “chocolate brown” color to blood in tubes 1 and 2 where there is a > 70% methemoglobin concentration. Tube 3 has a 20% methemoglobin concentration. Tube 4 is normal.

EM Case of the Week is a weekly “pop quiz” for ED staff.

The goal is to educate all ED personnel by sharing common pearls and pitfalls involving the care of ED patients. We intend on providing better patient care through better education for our nurses and staff.

BROWARD HEALTH MEDICAL CENTER

Department of Emergency Medicine
1625 SE 3rd Avenue
Fort Lauderdale, FL 33316

The correct answer is C. Methylene Blue

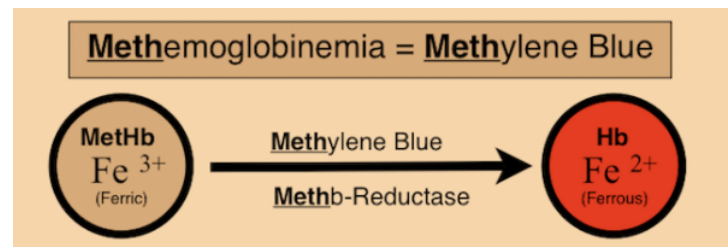
Methemoglobinemia is an acquired or congenital modification in hemoglobin in which the normal ferrous iron of heme is oxidized to the ferric state. This prevents hemoglobin from readily binding to oxygen leading to tissue hypoxia. Think of methemoglobinemia in a patient with low oxygen saturation on pulse oximetry but normal PaO₂ on ABG. Treatment is with either methylene blue or ascorbic acid.

Etiology

Methemoglobinemia can be acquired through various exogenous agents including medication overdose, poisonings or even standard doses of certain medications. Patients with G6PD deficiency, cytochrome b5 reductase deficiency, infants and premature infants are particularly at risk. Dapsone and topical anesthetic agents such as benzocaine, lidocaine and prilocaine are the most common precipitating agents of Methemoglobinemia. These drugs are commonly added to "street drugs" such as cocaine and heroin and should be considered as a cause of methemoglobinemia in illicit drug users. Other causes of acquired methemoglobinemia include inhaled nitrous oxide and aniline and its' derivatives.

Signs and Causes for Clinical Suspicion

Clinical suspicion for acquired methemoglobinemia may arise when there is a sudden onset of cyanosis with symptoms of hypoxia after ingestion or administration of a substance with oxidative potential. The hypoxia in methemoglobinemia does not improve with increased oxygen administration. There will also be an abnormal coloration to blood, often described as "chocolate brown", which does not change when exposed to oxygen. There is also strong suspicion of methemoglobinemia when a normal PaO₂ is present in the setting of signs and symptoms of hypoxia including low pulse oximetry.



(via www.BaronRocks.com)

Diagnosis

The preferred method for detecting methemoglobinemia includes analysis of methemoglobin directly by analyzing a freshly obtained blood sample for its' absorption spectrum. Methemoglobin has a peak absorption at 631nm. It is imperative to use a fresh sample of blood because methemoglobin levels increase with storage. A co-oximeter is used to detect methemoglobin, though false positives may result in the presence of other pigments including methylene blue. Ideally methemoglobin that has been detected by the co-oximeter is confirmed by the Evelyn Malloy method. This method adds cyanide to the assay eliminating confounding factors, especially for those who have already been treated with methylene blue.

Treatment

Treatment for acquired methemoglobinemia is usually methylene blue given at 1- 2 mg/kg over five minutes. The response is rapid and a repeat dose may be given one hour later if the methemoglobin level is still elevated or is rising. Those who have a rapid improvement clinically do not need to have methemoglobin levels rechecked. Methylene blue is contraindicated in patients with G6PD deficiency. In such instances ascorbic acid 300-1000mg/day divided should be used instead.

For a list of educational lectures, grand rounds, workshops, and didactics please visit BrowardER.com and **click** on the **"Conference"** link.

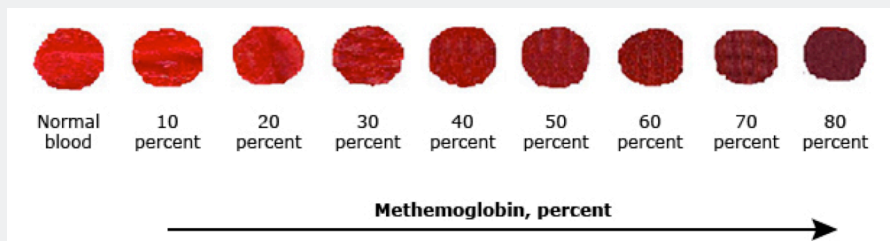
All are welcome to attend!

Warriors

Symptoms correlate to methemoglobin fractions in blood

Percentage	Symptoms
0-3%	Normal range of methemoglobin in blood
3-15%	Slight discoloration (pale, gray, blue) of skin
15-20%	Cyanosis, though patients can be asymptomatic
25-50%	Headache, dyspnea, lightheadedness, weakness, confusion, palpitations, chest pain
50-70%	Abnormal cardiac rhythms; altered mental status, delirium, seizures, coma, profound acidosis
>70%	Death


Color of blood in correlation to methemoglobin percentage



© 2017 UpToDate

Take Home Points

- Acquired methemoglobinemia results in acute signs and symptoms of hypoxia after ingestion or administration of an oxidative agent
- Suspect methemoglobinemia in patients with normal PaO₂, low pulse oximetry, chocolate brown colored blood and signs of hypoxia
- Detect with co-oximetry and confirm results with the Evelyn Malloy method
- Treat with methylene blue, unless patient has G6PD deficiency, in which case treat with ascorbic acid



ABOUT THE AUTHOR

This month's case was written by Dona Rose. Dona is a 4th year medical student from NSU-COM. She did her emergency medicine rotation at Broward Health North in April 2018. Dona plans on pursuing a career in Internal Medicine after graduation.

REFERENCES

Prchal, J. T. (2017, November 28). Clinical features, diagnosis, and treatment of methemoglobinemia. Retrieved from UpToDate database.

Mary, D.-B. (2017, November 14). Methemoglobinemia. In *Medscape*. Retrieved April 27, 2018, from <https://emedicine.medscape.com/article/204178-overview#a1>