

Review

Wound healing in adult skin: aiming for perfect regeneration

Madalene C. Y. Heng, MD, FRACP, FACD, FAAD

Clinical Professor of Medicine/
Dermatology, UCLA School of Medicine,
University of California Los Angeles, Los
Angeles, CA, USA

Correspondence

Madalene C. Y. Heng, MD, FRACP, FACD,
FAAD
3641 West Fifth Street
Oxnard
CA 93035
USA
E-mail:
madalenehengmd@hengmedicalinc.com

Funding: None.

Conflicts of interest: Author is the inventor
of curcumin gel.

Introduction

The title of this paper was adapted from that of a previous report, “Wound healing – aiming for perfect skin regeneration”, published in *Science* by Dr. Paul Martin, a British reconstructive surgeon.¹ In order to discover how adult human skin can be induced to reconstruct damaged parts more perfectly after surgery, Dr. Martin compared wound healing in adults with wound healing in embryos in which perfect regeneration is observed after wounding.

Wounding of the skin occurs when the epidermal layer is breached, thus exposing the underlying dermis to air. Depending on the depth of the injury, the tissues that are exposed to the air include fibroblasts, blood vessels, fascial connective tissue, cartilage, and bone. A temporary repair is achieved by the laying down of a fibrin blood clot, which plugs the defect and seals off the underlying tissues from oxygen in the air. The degenerating platelets also secrete platelet-derived growth factor (PDGF), which is both chemotactic to other inflammatory cells and stimulates the first phase of cell proliferation of epidermal cells, fibroblasts, and endothelial cells.

Inflammatory cells play an important role in wound healing. Neutrophils arrive at the wound site within minutes of injury. They clear out debris and contaminating bacteria and secrete proinflammatory cytokines that serve to activate local fibroblasts and keratinocytes. Members of the p-selectin adhesion molecules are known to be crucial

Abstract

Wound healing in adult skin, a complex process involving many cell types and processes such as epidermal, fibroblastic, and endothelial cell proliferation, cell migration, matrix synthesis, and wound contraction, almost invariably results in scar tissue formation and wound induration. Unlike in adult skin, wound healing in embryos involves repair processes that result in the essentially perfect regeneration of damaged tissue. This paper discusses key mechanisms that lead to scar tissue formation in adult human skin and treatment modalities, including curcumin gel, that may result in essentially perfect skin regeneration following surgical procedures.

in the rolling and diapedesis of leukocytes across endothelial cells into the wound, because these functions are severely affected in p-selectin knockout mice.² Within a few days, the neutrophils are replaced by blood-borne macrophages, which become activated and produce cytokines and growth factors essential to wound healing, as evidenced by findings that healing is impaired by the prevention of macrophage infiltration.³ These cytokines [interleukin-1 (IL-1) and tumor necrosis factor- α (TNF- α)], which induce nuclear factor- κ B (NF- κ B) signaling pathways, and growth factors (fibroblast growth factor, transforming growth factor- α [TGF- α] and TGF- β), which amplify growth factor receptor-mediated pathways, amplify the earlier proliferative wound signals induced by neutrophils and platelets.

About a week following wounding, the wound clot is infiltrated by activated fibroblasts, stimulated by TGF- β . TGF- β is chemotactic to fibroblasts and stimulates fibroblast proliferation, thereby increasing the synthesis of single strands of collagen by the activated fibroblasts. These single collagen fibers polymerize and cross-link in the extracellular matrix, forming thick strands of collagen fibers. These fibers are embedded in a newly synthesized, metalloprotein-rich extracellular matrix.

At this stage, a proportion of the wound fibroblasts transform into myofibroblasts, which express α -smooth muscle actin and resemble smooth muscle cells in their capacity to generate strong contractile forces.⁴ This

conversion of wound fibroblasts to myofibroblasts is triggered by TGF- β 1.⁵

In addition, the conversion of wound fibroblasts to myofibroblasts rises with increased wound tension.⁶ The tensile forces exerted by wound fibroblasts before, during, and after contraction have been studied in collagen-gel models.^{6–8} *In vivo* observations have shown that a number of tension-induced growth factors generated at the wound site are potent stimulators of fibroblast-driven gel contraction and granulation tissue contraction, i.e. increased tension stimulates fibroblast proliferation and contraction, while lack of tension induces increased myofibroblast apoptosis.¹ These observations may explain the increased scarring observed in tissue that heals under tension.

Factors associated with increased scarring

Unlike wounds in embryos, adult wounds almost always heal with scarring. Scarring is associated with various factors, including the type of wound, site of involvement, depth of the wound, presence of infection or excess inflammation, and tension exerted at the wound edges. Furthermore, injury to the underlying blood vessels and exposure of the wound to oxygen in the case of deep wounds tend to induce hypertrophic scar formation. Finally, genetic factors, such as the tendency to form keloids, will obviously affect how the patient heals after surgery.

Scarring, often severe, is associated with injury caused by burns and scalds, with greater degrees of scarring associated with more severe (third-degree) and extensive (larger surface area) burns. Hypertrophic scarring occurs frequently after thermal injury and involves the formation of a severe fibrosis of the skin, which limits movement. In addition, wounds associated with massive damage to underlying blood vessels, such as chemical or thermal burns and severe cold-induced injury, tend to be associated with severe scarring. Increased expression of TGF- β 1 has been observed in keloids and hypertrophic scars,⁹ and TGF- β , particularly TGF- β 1 and TGF- β 2, has been implicated in the pathogenesis of keloids.¹⁰ It is believed that TGF- β may also be implicated in hypertrophic scarring in burns and scalds.¹¹

Deep wounds also tend to be associated with injury to underlying blood vessels. The association between scarring and the depth of dermal injury was quantified by Dunkin *et al.*¹² The deep dermal end of the wound healed with a visible scar, whereas the superficial epidermal end showed no residual mark after 18 weeks. High-frequency ultrasound analysis showed a gradual reduction in scar thickness at the deep end and no detectable scar at the shallow end. Dermal fibroblasts from different layers of

human skin are heterogeneous in their expression of collagenase and types I and III procollagen mRNA,¹³ and it is not surprising that deep dermal fibroblasts have been shown to contribute to hypertrophic scarring.¹⁴

The increased scarring observed at various wound sites may have a basis in the increased tissue tension exerted on wounds at various scar-prone locations. The conversion of wound fibroblasts to myofibroblasts increases with greater wound tension,^{6–8} whereas lack of tension induces apoptosis. In addition, wounds located in areas of increased movement, such as on the shoulders, presternal chest, and clavicular areas, may subject the healing tissues to repeated tension, thereby making them more prone to hypertrophic scarring.

The association between vascular injury and scarring may be related to the release of oxygen free radicals in vascular compromised wounds that are exposed to oxygen in the air. In uninjured skin with a normal complement of blood vessels, the oxygen free radicals released by oxidative phosphorylation are quenched by an abundance of intravascular free radical quenchers, including superoxide dismutase, catalases, and reduced glutathione. The presence of damaged blood vessels allows unquenched free radicals to accumulate in sites exposed to oxygen in the air.¹⁵ Tissues exposed by surgery to oxygen in the air can be protected from exposure by the close apposition of the skin edges using multiple, closely positioned, fine stitches (M. C. Y. Heng, unpublished data, 2010). The size of space between the stitches depends upon the thickness of the skin and ranges from ≤ 0.5 mm in eyelid skin to 1 mm in the skin of the back.

Inflammatory cytokines and growth factors in hypertrophic scarring and keloids

Burn patients with hypertrophic scarring were observed to have polarized IL-4⁺ Th2 cytokine production, with significantly increased IL-10 and TGF- β production.¹¹ TGF- β is a pleiotrophic growth factor secreted by many activated cells, including inflammatory cells. The conversion of wound fibroblasts into myofibroblasts has also been linked to TGF- β 1 secretion in adult skin.

Fibroblasts are converted into myofibroblasts only in adult wounds. In embryos, there is no apparent conversion from fibroblasts to myofibroblasts.^{16–18} Consequently, in embryos to late fetal stage, wounds heal without scarring. Much has been learned from observations of wound healing in marsupials, which are born at a developmental stage equivalent to that of a young amniote fetus. For the first few days of their post-natal life, wounds in these fetal marsupials heal without scarring.¹⁹ There is a strong correlation between the age of

onset of scarring and the first stage in development when inflammation is generated.²⁰ The difference between embryo and adult skin may refer to the secretion of TGF- β 1. In the embryo, TGF- β 1 is expressed transiently and at low levels after injury.^{21,22} In the adult wound, high and prolonged levels of TGF- β 1 secretion have been observed.²³ Of interest is the observation that grafting adult skin in a fetal environment results in scar formation, which suggests that the inflammatory elements that lead to TGF- β formation are contained in adult grafted skin.

Transforming growth factor- β has also been implicated in the pathogenesis of keloids, particularly TGF- β 1 and TGF- β 2,¹⁰ whereas TGF- β 3 is thought to have an inhibitory role. Expression of TGF- β 1 is known to increase in keloids and hypertrophic scars, particularly in the early stages of wound healing.⁹

Signaling pathways in scar tissue formation targeted by treatment modalities

The occurrence of injury to the skin instigates signals that lead to the initiation of wound healing, resulting in inflammation, neovascularization, scarring, post-inflammatory pigmentation, and epidermal proliferation. One of the first changes involves the activation of transcription activators, particularly NF- κ B (Fig. 1). The activation of NF- κ B involves the removal of its inhibitory protein I κ B α by I κ B α kinase, a serine/threonine activated by phosphorylase kinase (PhK) and inhibited by curcumin.²⁴ Activation of NF- κ B results in the subsequent activation of over 200 genes involved in inflammation, cell migration, cell proliferation, cell cycling, cell survival, and inhibition of apoptosis. Targeting PhK, which is activated five minutes following injury, serves to block signaling induced by NF- κ B, which comprises

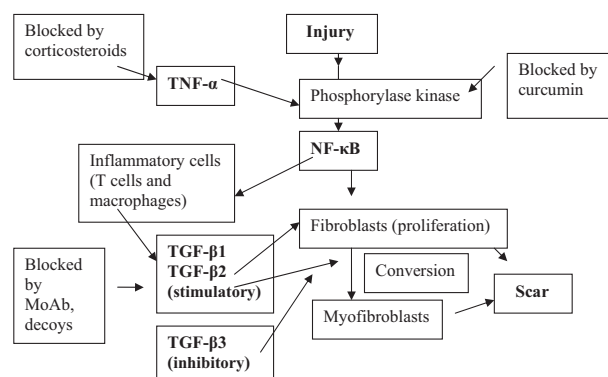


Figure 1 Signaling pathways in scar tissue formation: targets for anti-scarring therapy. TNF- α , tumor necrosis factor- α ; NF- κ B, nuclear factor- κ B; TGF- β 1, transforming growth factor- β 1

inflammation including T cell and macrophage activation, TGF- β 1 secretion, fibroblast proliferation, and myofibroblast conversion.

Treatment modalities

Inhibitory cytokines and monoclonal antibodies

Reduced scarring in post-burn patients has been noted following interferon- α 2b (IFN- α 2b) treatment. The improvement has been associated with decreased angiogenesis mediated by vascular endothelial cell growth factor (VEGF),²⁵ as well as by decreased fibrocytes.²⁶ More recently, anti-TGF- β 1 antibodies have been observed to give promising results in animal studies,²⁷ but the treatment is still experimental. The addition of exogenous TGF- β 3, which has inhibitory properties for fibroblast proliferation, is also undergoing clinical trials.²⁷

Intralesional corticosteroid injections, silicone gel sheeting and laser therapy

Intralesional corticosteroid injections have been used for many years and, until recently, have represented the mainstay of therapy for hypertrophic scars and keloids. However, improvement is limited, and keloids frequently recur. More recently, 1550-nm fractional erbium-glass laser²⁸ and pulse dye laser²⁹ have been reported to be useful in scar prevention and treatment. Multifaceted therapy, such as the combination of intralesional corticosteroids/5-fluorouracil with 595-nm long pulsed dye laser and 1450-nm diode laser, was attempted in one patient,³⁰ but the results were far less satisfactory than those achieved with curcumin gel (see below). Silicone sheeting for preventing and treating hypertrophic scars has also been used, with uncertain and unproven benefits.³¹

Topical hyperbaric oxygen therapy

Low-pressure topical hyperbaric oxygen therapy has been shown to assist in the healing of deep ulcers with minimal scarring.¹⁵ Necrotic wounds contain damaged blood vessels. When exposed to oxygen in the air, the surface layer of tissues becomes necrotic as a result of the presence of the unopposed free radicals generated when the wound makes contact with oxygen. These unopposed free radicals occur because of inadequate supplies in the tissues of free radical quenchers (superoxide dismutase, catalases, and reduced glutathione) that would normally be available for injury-free oxidative phosphorylation in undamaged tissue blood vessels. This constant generation of unopposed free radicals prevents necrotic wounds from healing. Within the confines of “therapeutic pressures”, low-pressure topical hyperbaric oxygen is believed to neutralize the free oxygen radicals that are released when

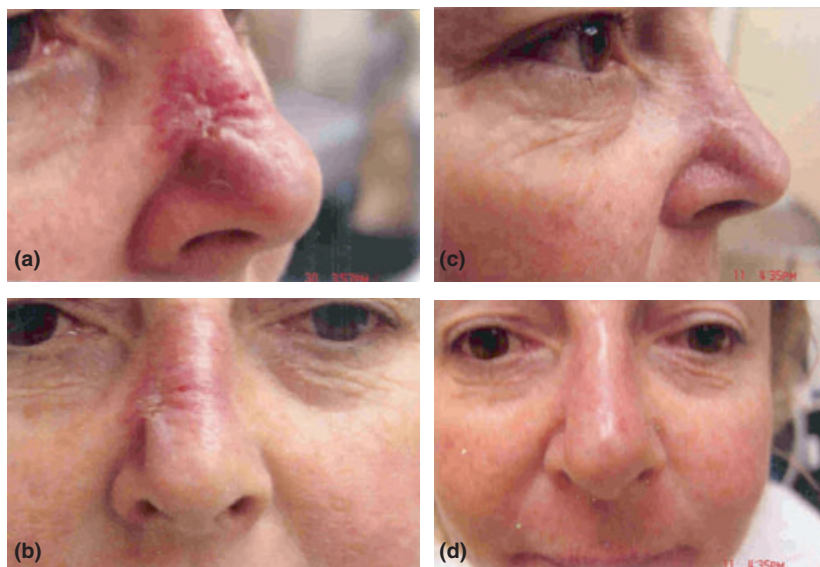


Figure 2 Patient 1. (a) Right oblique and (b) frontal views of the hypertrophic scar at the site of graft repair at removal of sutures 3 weeks after grafting. (c) Right and (d) frontal views of the hypertrophic scar after 6 weeks of topical treatment with extra-strength curcumin gel

tissues are exposed to oxygen in the air, thus allowing neovascularization and the healing of wounds with minimal scarring.¹⁵ However, topical hyperbaric oxygen treatment is more suitable for open than sutured wounds. In addition, the treatment must be administered for a period of four hours per day, which makes it both expensive and impractical for routine use.

Topical curcumin (curcumin gel) for hypertrophic scar treatment and prevention

Injury triggers a number of signaling pathways to cause increased cell proliferation, and including fibroblast proliferation, endothelial cell proliferation and the proliferation of myofibroblasts, resulting in the formation of scar tissue. These pathways are mediated by the transcription regulator NF- κ B. Prior to injury, NF- κ B exists as a pair of dimers (p50/p65) within the cytoplasm. When activated by a number of inflammatory stimuli, including surgical injury, these NF- κ B dimers translocate to the nucleus, where they bind to the κ B site on the DNA, an event that results in the transcription of over 200 genes responsible for cell proliferation, cell migration, cell cycling, and the inhibition of apoptosis,³²⁻³³ and thus in fibroblast proliferation, a requirement for subsequent scar tissue formation.

The activation of NF- κ B requires phosphorylation at multiple serine/threonine-specific sites as well as tyrosine-specific sites.³⁴⁻³⁷ The process of activating NF- κ B requires the removal of its inhibitory protein, I κ B α , by phosphorylation of its kinase, I κ B α kinase. I κ B α kinase is a serine/threonine kinase which is activated by PhK and inhibited by curcumin, a PhK inhibitor.³⁸ Protein kinases usually transfer high-energy phosphate bonds to either serine/threonine or tyrosine residues. This is because pro-

tein kinases, with the exception of PhK, allow only one configuration at the substrate binding site. PhK is a unique enzyme in which the spatial arrangements of the

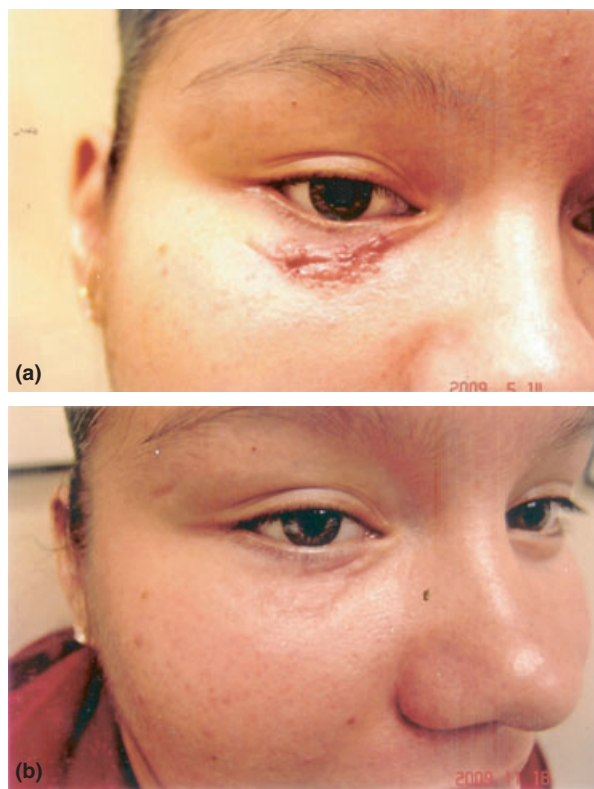


Figure 3 Patient 2. (a) Scarring at the removal of sutures of a sclerosing basal cell carcinoma with graft repair. (b) Minimal residual scarring is apparent after 2 months of topical treatment with extra-strength curcumin gel b.i.d.

specificity determinants can be manipulated such that PhK can transfer high-energy phosphate bonds from ATP (adenosine-5'-triphosphate) to substrates of different specificities, such as serine/threonine and tyrosine residues.³⁹ This is achieved by means of a hinge joint between the subunits, which alters the size of the substrate binding site, and by ions such as Mn or Mg, which allow the shape of the substrate binding site to be altered by swiveling in one plane by binding to Mn and in another by binding to Mg, thus allowing for dual specificity.^{39,40} Additionally, PhK, which is activated within five minutes of injurious stimuli, is also responsible for the generation of ATP through the activation of glycogen phosphorylase at ser-14,²⁴ for repair processes, including inflammation and fibroblast proliferation. Curcumin, a non-competitive and selective inhibitor of PhK,³⁸ has been shown to be a potent inhibitor of NF-kB activation⁴¹ and hence to cause the blockade of signaling pathways for fibroblast proliferation.⁴¹

Although the curcumin molecule is not readily absorbed through the skin, we have found that the gel preparation of curcumin is capable of penetrating injured

skin, such as in psoriasis,⁴² sufficiently to decrease PhK levels within the epidermis.⁴² Outcomes in the series of patients presented herein demonstrate that curcumin gel is also capable of penetrating at least as far as the superficial dermis in post-surgical scars, with significant resolution of post-surgical scarring. In patient 4, perfect regeneration was achieved in the grafted site, with some scarring, albeit minimal, in the temporal area closed under some tension. In patient 5, near perfect regeneration was observed as early as four weeks after the removal of stitches. Stitches were removed at two weeks from the donor site and at four weeks from the graft. As the graft was devoid of blood supply at the time of the surgery, it required four weeks to acquire new blood vessels from the surrounding tissues in order for the graft to heal sufficiently for the stitches to be removed. In patient 6, the wound was closed with an O-to-Y rotation flap, from which stitches were removed at two weeks post surgery. As the wound was closed under some tension, prominent early scarring was observed at the time of suture removal at two weeks, but the scar was seen to

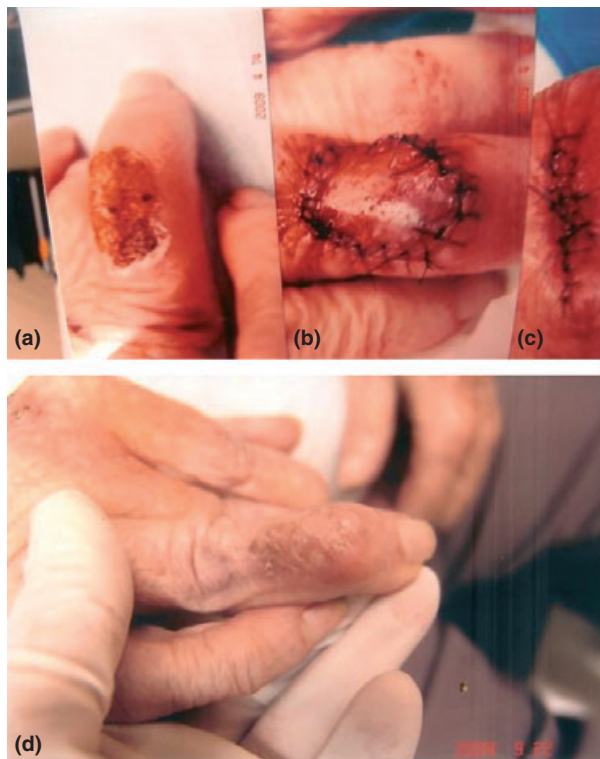


Figure 4 Patient 3. (a) A large squamous cell carcinoma situated over the middle and distal phalanx of the ring finger was excised, and (b, c) repaired by graft. (d) Topical treatment with extra-strength curcumin gel facilitated healing with minimal scarring

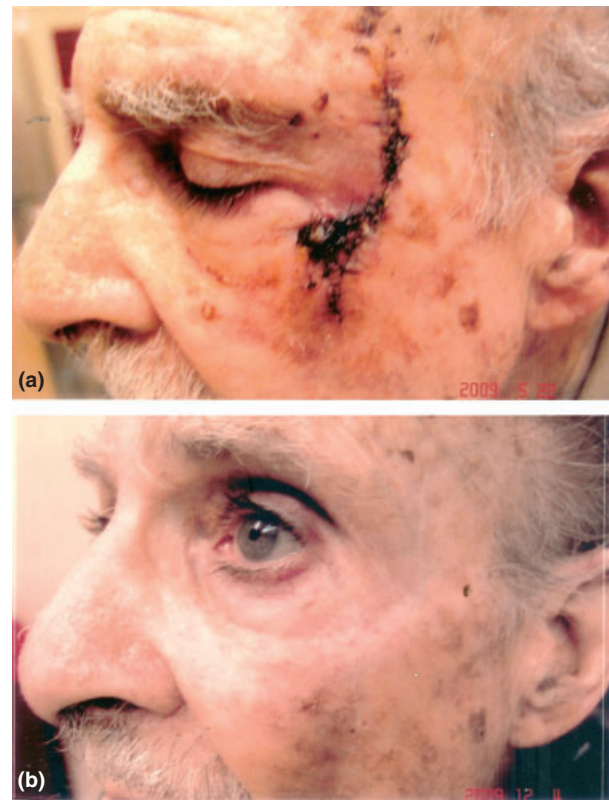

Figure 5 Patient 4. (a) Excision and donor sites at the time of surgery. (b) Seven months later, the grafted site on the malar cheek had healed with no evidence of scarring (perfect regeneration), but the donor site on the temple, which was closed with some tension, healed with some scarring

have resolved four weeks later. Although early NF- κ B-dependent scarring is reversible, this may not be true of hypertrophic scarring, which is based on TGF- β ₁/TGF- β ₂-dependent myofibroblast proliferation.

Case reports

Patient 1

Patient 1 was a 42-year-old Caucasian woman with a biopsy-proven sclerosing carcinoma on the nose of two years' duration. The tumor was situated over the right nasal side wall and spread to involve the right supratip and tip of the nose and to encroach on the right alar of the nose (Fig. 2a). The tumor was excised down to cartilage and bone and the defect closed with a graft from a donor site situated over the left nasal side wall and bridge of the nose. Sutures were removed three weeks later, when prominent scarring was observed (Fig. 2a, b). Extra-strength curcumin gel (12%) was massaged into the scar tissue twice daily. Six weeks later, minimal scarring was observed (Fig. 2c, d).

Patient 2

Patient 2 was a 28-year-old Hispanic man with a sclerosing basal cell carcinoma over the right lower eyelid. This was excised down to muscle and the defect closed using a tissue graft taken from a donor site over the lower eyelid and cheek. A prominent scar was observed at the time of

suture removal (Fig. 3a). Extra-strength curcumin gel was massaged into the scar twice daily, with minimal residual scarring (Fig. 3b).

Patient 3

Patient 3 was an 80-year-old man with a large, well-differentiated carcinoma situated over the dorsum of the fourth finger. This was excised down to tendon and bone and the defect closed with a graft taken from the dorsum of the same hand. The stitches were removed four weeks later, and extra-strength curcumin was applied with minimal residual scarring (Fig. 4).

Patient 4

Patient 4 was an 85-year-old man with a large basosquamous carcinoma situated over the left malar cheek and temple. This was excised down to deep fascia and muscle, and the wound grafted with a tissue graft taken from the temple (Fig. 5a). Stitches were removed from the donor site at two weeks and from the graft at four weeks. Extra-strength curcumin gel was applied to the surgical site for two months from the removal of the stitches until the resolution of the scar (Fig. 5b).

Patient 5

Patient 5 was an 80-year-old woman with biopsy-proven sclerosing basal cell carcinoma (Fig. 6a) affecting the right alar of the nose and paranasal cheek and right

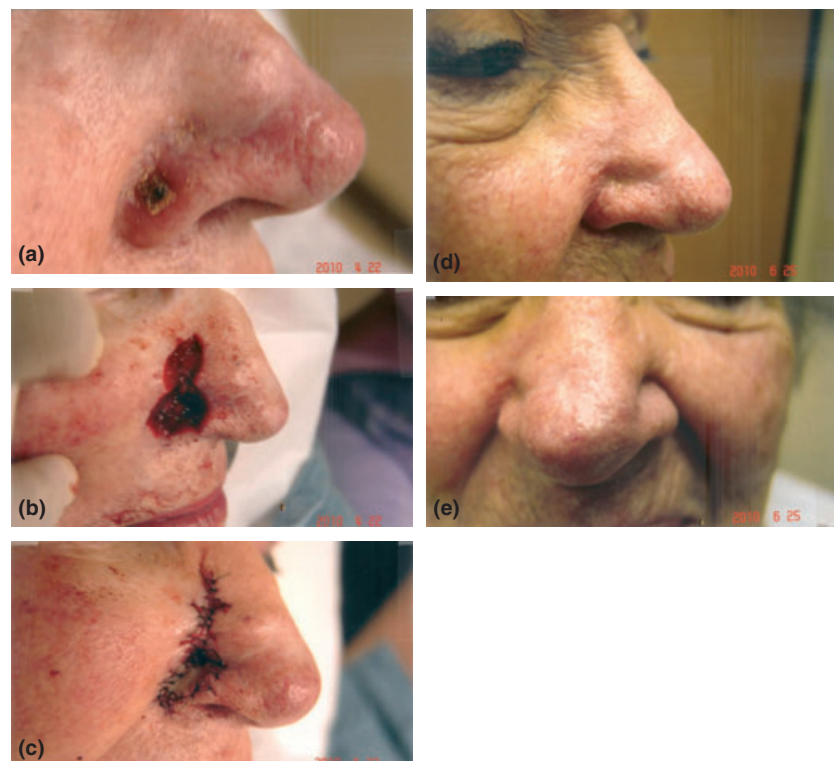

Figure 6 Patient 5. Sclerosing basal cell carcinoma of the nasal ala (a) before and (b) after excision. (c) The resulting wound was repaired by a tissue graft obtained from the paranasal cheek. (d, e) Scarring resolved at both the surgical and graft sites after topical treatment with extra-strength curcumin gel b.i.d. for 4 weeks

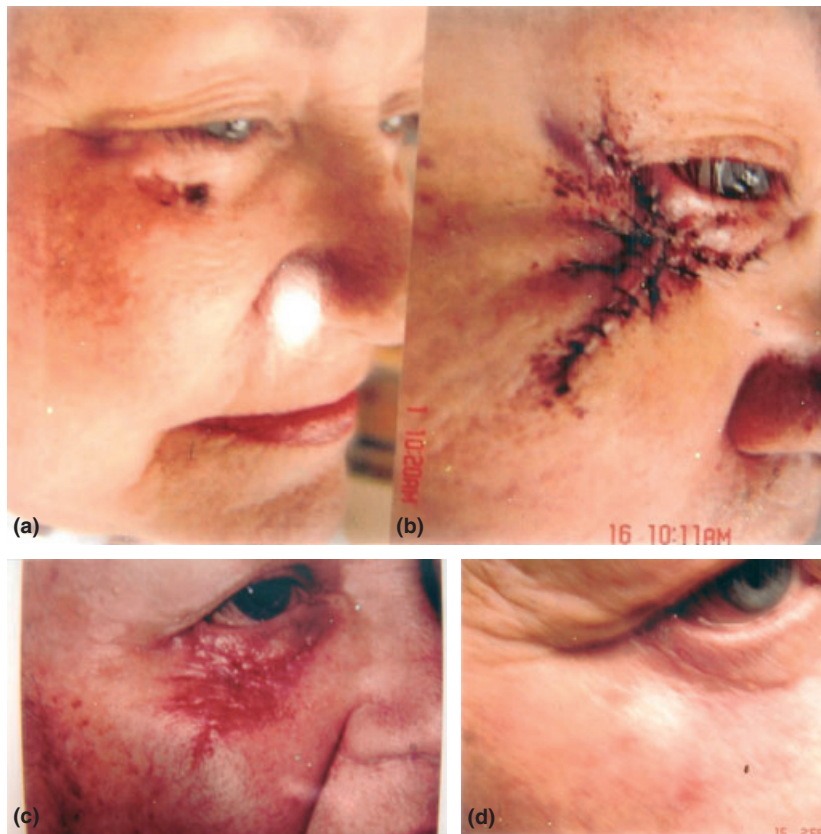

Figure 7 Patient 6. A large sclerosing basal cell carcinoma involving the right lower eyelid, malar and infraorbital cheek (a) before and (b) after excision closed with an O-to-Y rotation flap. (c) Early scarring was apparent over the eyelid, malar and infraorbital cheek following suture removal 2 weeks later. (d) Scarring resolved after 30 days of topical treatment with extra-strength curcumin gel b.i.d.

nasal side wall. This was excised (Fig. 6b) and the defect closed with a tissue graft taken from a donor site situated over the right paranasal cheek (Fig. 6c). Stitches were removed from the donor site at two weeks and from the graft at four weeks, after which extra-strength curcumin gel was massaged into the surgical sites twice daily, with resolution of residual scarring four weeks later (Fig. 6d, e).

Patient 6

Patient 6 was a 72-year-old woman with a large sclerosing basal cell carcinoma (Fig. 7a) involving the right lower eyelid and malar cheek. Excision resulted in a large defect, which was not grafted but closed using an O-to-Y rotation flap (Fig. 7b). As a result of the tension applied by the flap, a prominent scar was observed at the time of suture removal at two weeks (Fig. 7c). Extra-strength curcumin gel was applied twice daily and achieved complete resolution of the scar (Fig. 7d) 30 days later.

Conclusions

All wounds in adults heal with scarring and are further aggravated by genetic predisposition, wound location and depth, wound tension, exposure to oxygen in the air, infection, and inaccurate stitching. Signaling pathways for

fibroblast proliferation are mediated through NF- κ B activation. Hypertrophic scarring occurs when fibroblasts further convert to myofibroblasts, a process stimulated by TGF- β ₁ and TGF- β ₂, and inhibited by TGF- β ₃. NF- κ B is activated by PhK and blocked by curcumin. To date, there is a lack of effective anti-scarring treatments available for general use. Corticosteroids with or without laser treatments have been tried but are generally unsatisfactory and do not achieve “perfect regeneration”. The application of monoclonal antibodies against TGF- β ₁ and TGF- β ₂ and exogenous inhibitory TGF- β ₃ has been largely experimental, and its effects are unproven to date. Topical hyperbaric oxygen therapy requires that wounds be open to have benefit and is unwieldy and usually not applicable in sutured wounds. The series of post-surgical wounds presented here, which includes wounds both with and without grafts, all of which were treated with extra-strength curcumin gel (12%), demonstrates results that approached perfect regeneration in some patients. It is believed that successful treatment of scarring involves blocking the apparently reversible NF- κ B-based fibroblast proliferation rather than resolving myofibroblast-based hypertrophic scarring, which may be irreversible. Early treatment with curcumin gel is believed to block PhK/NF- κ B-based fibroblast proliferation, which then prevents the development of hypertrophic scars. However, curcumin

gel appears to be effective only in the early stages of scar tissue formation.

References

- 1 Martin P. Wound healing – aiming for perfect skin regeneration. *Science* 1997; 276: 75–81.
- 2 Springer TA. Traffic signal for lymphocyte recirculation and lymphocyte emigration: the multistep paradigm. *Cell* 1994; 76: 301–314.
- 3 Leibovich SJ, Ross R. The role of the macrophage in wound repair. *Am J Pathol* 1975; 78: 71–100.
- 4 Desmoulière A, Gabbiani G. *The Molecular and Cellular Biology of Wound Repair*. New York, NY: Plenum, 1996: 391–423.
- 5 Desmoulière A, Geinoz A, Gabbiani F, *et al*. Transforming growth factor-beta 1 induces alpha smooth muscle actin expression in granulation tissue myofibroblasts and in quiescent and growing cultured fibroblasts. *J Cell Biol* 1993; 122: 103–111.
- 6 Grinnell F. Fibroblasts, myofibroblasts and wound contraction. *J Cell Biol* 1994; 124: 401–404.
- 7 Montesano R, Orci L. Transforming growth factor-beta stimulates collagen matrix contraction by fibroblasts; implication for wound healing. *Proc Natl Acad Sci USA* 1988; 85: 4894–4897.
- 8 Clark RA, Folkword JM, Hart CE, *et al*. Platelet isoforms of platelet-derived growth factor stimulate fibroblasts to contract collagen matrices. *J Clin Invest* 1989; 84: 1036–1040.
- 9 Abou AG, Maraee AH, Al-Bara AM, *et al*. Immunohistochemical expression of TGF-beta1 in keloids and hypertrophic scars. *Am J Dermatopathol* 2011; 33: 334–391.
- 10 Lee TY, Chin GS, Kim WJ, *et al*. Expression of transforming growth factor-beta 1, 2, and 3 proteins in keloids. *Ann Plast Surg* 1999; 43: 179–184.
- 11 Tredget EE, Yang L, Delehanty M, *et al*. Polarized Th2 cytokine production in patients with hypertrophic scar following thermal injury. *J Interferon Cytokine Res* 2006; 26: 179–189.
- 12 Dunkin CS, Pleat JM, Gillespie PH, *et al*. Scarring occurs at a critical depth of skin injury: precise measurement in a graduated dermal scratch in human volunteers. *Plast Reconstr Surg* 2007; 119: 1722–1732.
- 13 Ali-Bahar M, Bauer B, Tredget EE, *et al*. Dermal fibroblasts from different layers of human skin are heterogeneous in expression of collagenase and types I and III procollagen mRNA. *Wound Repair Regen* 2004; 12: 175–182.
- 14 Wang J, Dodd C, Shankowsky HA, *et al*. Deep dermal fibroblasts contribute to hypertrophic scarring. *Lab Invest* 2008; 88: 1278–1290.
- 15 Heng MC, Harker J, Csathy G, *et al*. Angiogenesis in necrotic ulcers treated with hyperbaric oxygen. *Ostomy Wound Manage* 2000; 46: 18–32.
- 16 Martin P, Lewis J. Actin cables and epidermal movement in embryonic wound healing. *Nature* 1992; 360: 179–183.
- 17 McCluskey J, Martin P. Analysis of the tissue movements of embryonic wound healing – DiI studies in the limb bud stage mouse embryo. *Dev Biol* 1995; 170: 102–114.
- 18 Estes JM, Vande Berg JS, Adzick NS, *et al*. Phenotypic and functional features of myofibroblasts in sheep fetal wounds. *Differentiation* 1994; 56: 173–181.
- 19 Armstrong JR, Ferguson MW. Ontogeny of the skin and transition from scar free to scarring phenotype during wound healing in the pouch young of a marsupial, *Monodelphis domestica*. *Dev Biol* 1995; 169: 242–260.
- 20 Adzick NS, Harrison MR, Glick PL, *et al*. Comparison of fetal, newborn, and adult wound healing by histologic, enzyme-histochemical, and hydroxyproline determinations. *J Pediatr Surg* 1985; 20: 315–319.
- 21 Whitby DJ, Ferguson MW. Immunohistochemical localization of growth factors in fetal wound healing. *Dev Biol* 1991; 147: 207–215.
- 22 Martin P, Dickson MC, Millan FA, *et al*. Rapid induction and clearance of TGF-beta 1 is an early response in wounding in mouse embryo. *Dev Genet* 1993; 14: 225–238.
- 23 Frank S, Madlener M, Werner S. Transforming growth factors beta1, beta2 and beta3 and their receptors are differentially regulated during normal and impaired wound healing. *J Biol Chem* 1996; 271: 10188–10193.
- 24 Heng MCY. Curcumin targeted signaling pathways: basis for anti-photoaging and anti-carcinogenic therapy. *Int J Dermatol* 2010; 49: 608–632.
- 25 Wang J, Chen H, Shankowsky HA, *et al*. Improved scar in post-burn patients following interferon-alpha2b treatment is associated with decreased angiogenesis mediated by vascular endothelial growth factor. *J Interferon Cytokine Res* 2008; 28: 423–434.
- 26 Ferguson MW, O’Kane S. Scar-free healing from embryonic mechanisms to adult therapeutic intervention. *Philos Trans R Soc Lond B Biol Sci* 2004; 359: 839–850.
- 27 Wang J, Jiao H, Stewart TL, *et al*. Improvement in postburn hypertrophic scar after treatment with interferon- α 2b is associated with decreased fibrocytes. *J Interferon Cytokine Res* 2007; 27: 921–930.
- 28 Choe JH, Park YL, Kim BJ, *et al*. Prevention of thyroidectomy scar using a new 1,550 nm fractional erbium-glass laser. *Dermatol Surg* 2009; 35: 1199–1205.
- 29 Chan HH, Wong DS, Ho WS, *et al*. The use of pulsed dye laser for the prevention and treatment of hypertrophic scars in Chinese persons. *Dermatol Surg* 2004; 30: 987–994.
- 30 Katz TM, Glaich AS, Goldberg LF, *et al*. 595-nm long pulsed laser and 1450-nm diode laser in combination with intralesional triamcinolone/5-fluorouracil for

- hypertrophic scarring following a phenol peel. *J Am Acad Dermatol* 2010; **62**: 1045–1049.
- 31 O'Brien L, Pandit A. Silicon gel sheeting for preventing and treating hypertrophic and keloid scars. *Cochrane Database Syst Rev* 2006; **25**: CD003826.
- 32 Aggarwal BB. Nuclear factor-kappa B: the enemy within. *Cancer Cell* 2004; **6**: 203–208.
- 33 Verma IM, Stevenson JK, Schwarz EM, *et al.* Rel/NF- κ B family: intimate tales of association and disassociation. *Genes Dev* 1995; **270**: 2723–2735.
- 34 Takada Y, Singh S, Aggarwal BB. Identification of p65 peptide that selectively inhibits NF-kappa B activation induced by various inflammatory stimuli and its role in downregulation of NF-kappaB-mediated gene expression and upregulation of apoptosis. *J Biol Chem* 2004; **279**: 15096–15104.
- 35 Lallena MJ, Diaz-Meco MT, Bren G, *et al.* Activation of I κ B α by protein kinase C isoforms. *Mol Cell Biol* 1999; **19**: 2180–2188.
- 36 cHuang WC, Chen JJ, Chen CC. c-Src dependent tyrosine phosphorylation of IKKbeta is involved in tumor necrosis factor-alpha-induced intercellular adhesion molecule-1 expression. *J Biol Chem* 2003; **278**: 9944–9952.
- 37 Yang F, Yamashita J, Tang E, *et al.* The zinc finger C417R of I-kappa B-kinase gamma impairs lipopolysaccharide and TNF-mediated NF-kappa B activation through inhibiting phosphorylation of the I-kappa B kinase beta activation loop. *J Immunol* 2004; **172**: 2446–2452.
- 38 Reddy S, Aggarwal BB. Curcumin is a non-competitive and selective inhibitor of phosphorylase kinase. *FEBS Lett* 1994; **341**: 19–22.
- 39 Graves D, Bartelson C, Bjorn A, *et al.* Substrate and inhibitor recognition of protein kinases: what is known about the catalytic subunit of phosphorylase kinase? *Pharmacol Ther* 1999; **82**: 143–155.
- 40 Yuan CJ, Huang CY, Graves DJ. Phosphorylase kinase: a metal ion dependent dual specificity kinase. *J Biol Chem* 1993; **268**: 17683–17686.
- 41 Chen A, Zheng S. Curcumin inhibits connective tissue growth factor gene expression in activated hepatic stellate cells *in vitro* by blocking NF-kappa B and ERK signaling. *Br J Pharmacol* 2008; **153**: 557–567.
- 42 Heng MC, Song MK, Harker J, *et al.* Drug-induced suppression of phosphorylase kinase activity correlates with resolution of psoriasis as assessed by clinical histological and immunohistochemical parameters. *Br J Dermatol* 2000; **143**: 937–949.