

## Ehlers-Danlos syndrome presenting with infarction of stomach

N A Shaikh MBBS FRCSE D T L T Turner MS FRCS  
Department of Surgery, Pilgrim Hospital, Lincolnshire

Keywords: Ehlers-Danlos syndrome; infarction; stomach

Ehlers-Danlos syndrome was first described by Ehler (1901) and well documented by Danlos (1908). It is an inherited disorder of connective tissue with many complications involving the gastrointestinal system, but infarction of the stomach has not previously been reported.

### Case report

The patient, a 17-year-old girl, a known case of Ehler-Danlos Syndrome (EDS), presented with a 14 h history of generalized abdominal pain, worse in the upper abdomen. The pain radiated to the back. She had been vomiting, starting 2 h after onset of pain and continued with approximately 30-60 min intervals. She had one loose motion 8 h prior to admission; there was no mucus nor blood in the stools. Her previous malformations which had required surgical correction had been scoliosis, and dislocated hip and knee joints.

On examination, she was toxic, febrile with a pulse of 130/min and a blood pressure of 130/95 mmHg. Abdominal examination revealed a cyanotic tinge to the skin from nipple line down. It was distended with generalized tenderness and guarding. The bowel sounds were present.

There were soft faeces present on rectal examination.

The cardiovascular and respiratory systems were normal.

The blood investigations were as follows: Haemoglobin, 18.7 g/dl; white cell count, 10.5 (92% neutrophils); platelets, 152; haemocrit, 0.549; sodium, 139 mmol; potassium, 3.6 mmol; urea, 5.6 mmol; glucose, 10.6 mmol; serum amylase, 174.

The chest X-ray was normal, but plain X-ray of the abdomen showed a dilated stomach with some food debris and gas in the wall of the stomach, indicating a severe ischaemia (Figure 1).

At laparotomy, the proximal  $\frac{3}{4}$  of the stomach was found to be gangrenous but no free perforation. There was no evidence of a torsion or a hiatus hernia which could have caused strangulation.

A proximal gastrectomy with end-to-end anastomosis between the antrum and oesophagus was performed using nonabsorbable sutures. In addition a Heineke-Mikulicz pyloroplasty was performed. She made an uneventful postoperative recovery apart from a chest infection which resolved with antibiotics.

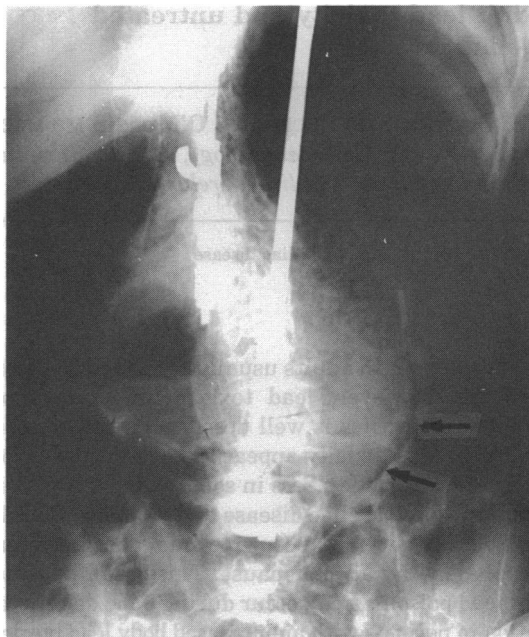


Figure 1. Ehlers-Danlos syndrome with spinal instrumentation. Plain X-ray shows dilated stomach with food debris and intramural gas (arrows)

### Discussion

EDS is relatively rare. On clinical grounds it has been divided into 5 types. Patients with type I-IV appear to have an autosomal dominant form of inheritance whereas those with type V have X-linked pattern of inheritance<sup>1</sup>.

Previously reported gastrointestinal complications of EDS are hiatus hernia, eventration of diaphragm, peptic ulceration, perforation, diverticulosis (stomach, duodenum, jejunum and colon), rectal prolapse, megaduodenum<sup>2-3</sup>.

Gastric torsion has been described<sup>4</sup> but an infarction of the stomach has not previously been reported in this condition. Though it has been advised that surgery is best avoided in EDS, due to the fragility of the tissues<sup>5</sup>, it is encouraging that problems of this sort were not encountered in this case and that her progress has been good after a two year follow up.

### References

- 1 Scully RE, Galdabini JJ, McNeely BU. Case records of the Massachusetts General Hospital, Case 3-1979. 1979;300:129-35
- 2 Beighton PH. *The Ehlers-Danlos syndrome*. London: William Heinemann, 1970
- 3 Beighton PH, Murdoch JL, Votcler T. Gastrointestinal complications of the EDS. *Gut* 1969;10:1004-8
- 4 Linneman MP. EDS presenting with torsion of stomach. *Proc R Soc Med* 1975;68:12-4

(Accepted 27 July 1987. Correspondence to Mr Shaikh, Breast Clinic, St Mary's Hospital, London W2 1PG)

0141-0768/88/  
100611-01/\$02.00/0  
© 1988  
The Royal  
Society of  
Medicine