

# Alternative Fistula Management

---

A Case Study

# Alternative Fistula Management Objectives

---

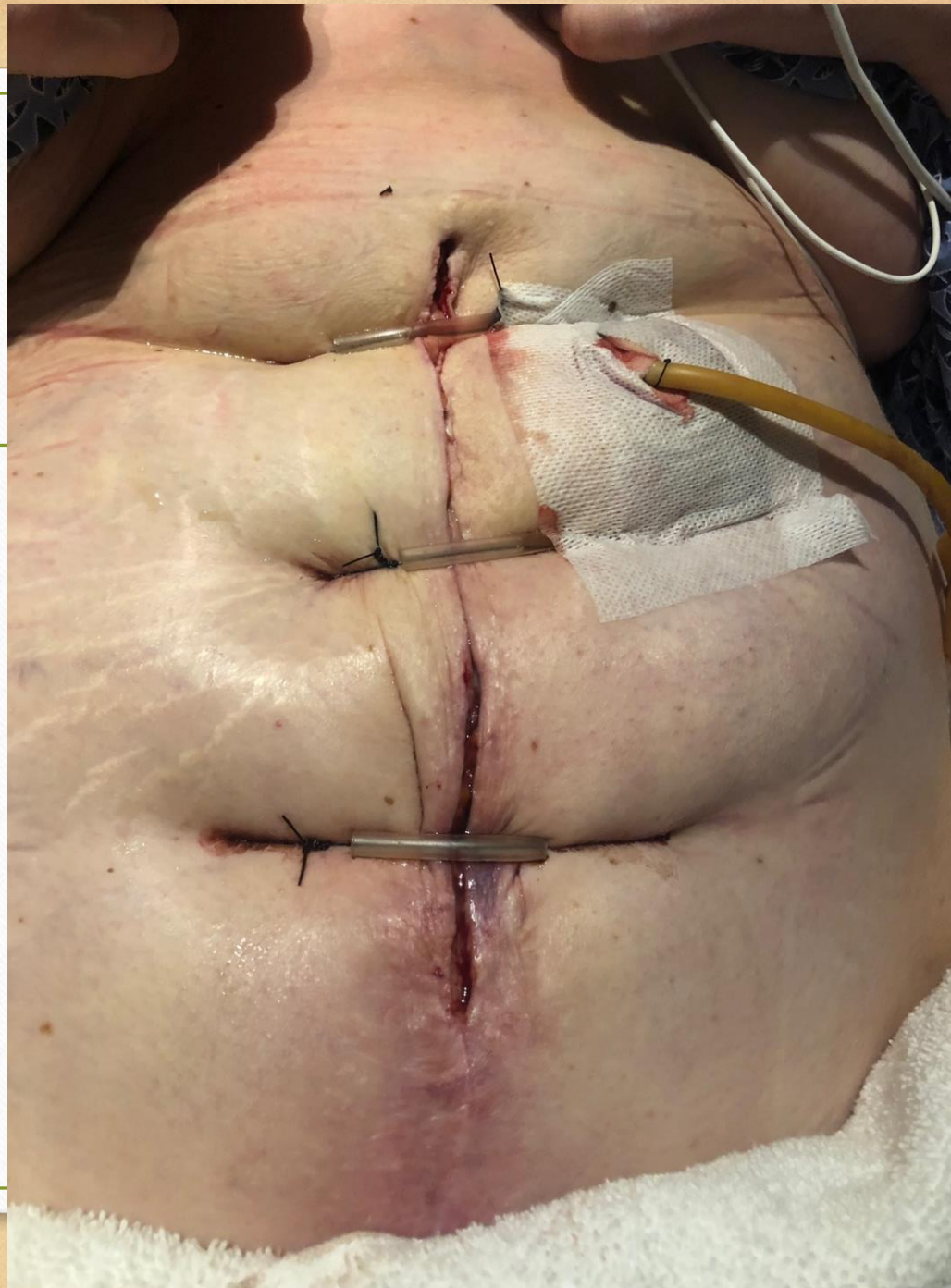- Discover use for NPWT to manage a fistula when the goal of therapy is not wound closure.
- Understand multidisciplinary approach to custom fistula management used in a complicated case.



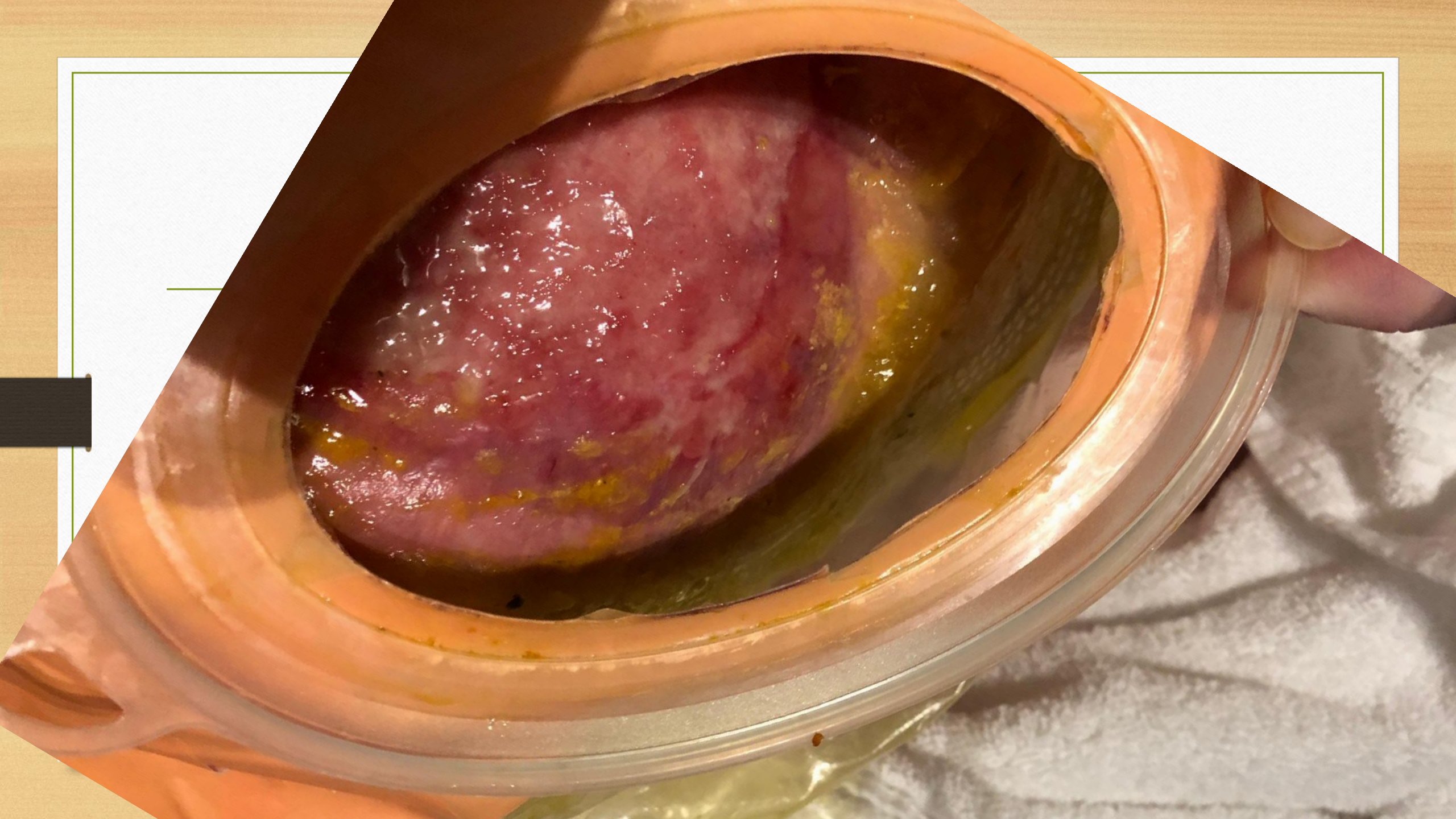
# Patient History

---

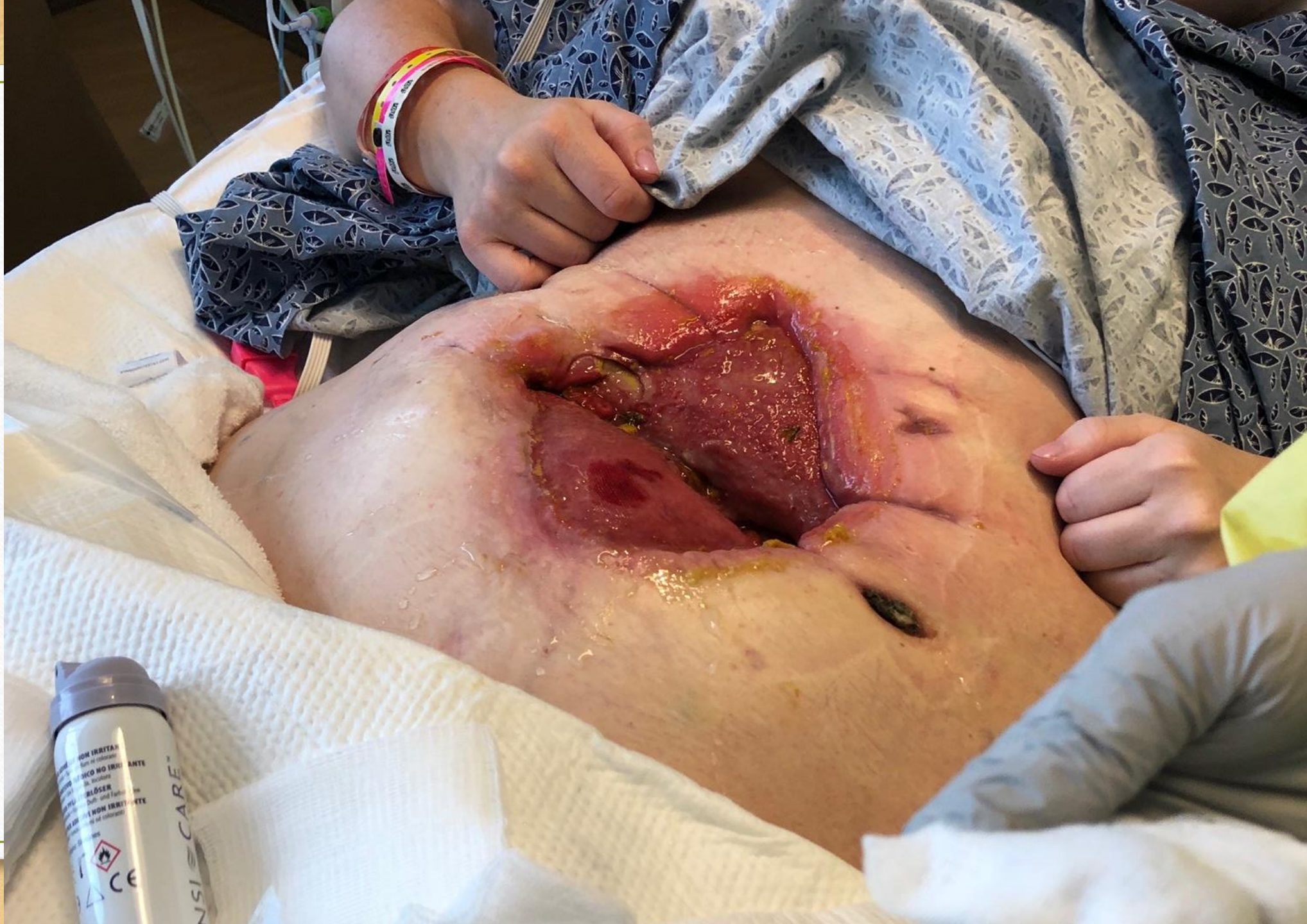- 33yo female
- Unresectable metastatic liposarcoma despite multiple debulking surgeries in the past with a chronic midline wound and enterocutaneous fistula who was readmitted for symptomatic anemia and acute kidney injury.
- Currently on TPN due to high output fistula to open abdominal wound.
- Patient has been in and out of the hospital with an extensive medical course.
- Patient has unresectable disease and at this time goal of care is to make the patient as comfortable as possible with the best quality of life possible.
- CHF with systolic dysfunction
- Hypothyroidism
- Addison's disease
- DVT on apixaban













Consulted to assist with containing fistula  
drainage separate from the wound. May 29,

2019

ileostomy



Puncture wound  
from PEG

Enteroatmospheric fistula  
Caused by anastomosis rupture

tumor

undermining

Colo-atmospheric fistula

Full thickness wounds  
from retention sutures

